

# The Pedicled LICAP Flap Combined with a Free Abdominal Flap In Autologous Breast Reconstructions

Thomas Sjøberg, MD\*  
Louis de Weerd, MD, PhD\*†

**Background:** Previous surgery or slim body configuration can limit the size of the available abdominal flap in autologous breast reconstruction. However, redundant skin and subcutaneous tissue lateral to the mastectomy site can be utilized as the pedicled lateral intercostal artery perforator (LICAP) flap. This study evaluates the combination of a free abdominal flap and a pedicled LICAP flap to achieve increased breast size and improved cosmetic outcome.

**Methods:** Patients undergoing secondary autologous breast reconstruction were included in a prospective study. The combination with a LICAP flap was used for women with insufficient abdominal flap tissue in relation to the desired breast size. The authors also assessed their modification of the original lateral thoracodorsal flap design to improve the aesthetic outcome.

**Results:** In 109 patients, 121 free abdominal flaps were performed. The combination with a pedicled LICAP flap was used in 82 free abdominal flap reconstructions (68%). The LICAP flap provided additional volume and resulted in better projection and ptosis of the neo-mamma. The overall complication rate for the LICAP flaps was 26 %; all minor complications. Despite combining flaps, the majority of patients needed additional surgery to improve breast symmetry. Breast reduction of the native breast was the most common symmetrizing procedure.

**Conclusion:** In selected patients with insufficient abdominal flap tissue, a combination of a free abdominal flap and a pedicled LICAP flap is a valuable option to increase breast size and cosmetic outcome. Additional symmetrizing surgery might still be necessary. (*Plast Reconstr Surg Glob Open* 2018;6:e1562; doi: 10.1097/GOX.0000000000001562; Published online 12 January 2018.)

## INTRODUCTION

Free abdominal flap breast reconstruction is a well-established surgical procedure. Few other donor sites can provide the same volume and tissue quality to create

a natural looking breast. Still, slim body configuration, previous surgery affecting the abdominal flap perfusion or the request for bilateral reconstructions might result in breasts with unsatisfactory volume and shape. In these patients, we therefore recognize a need to augment the abdominal flap with other tissue to fulfill patients' expectations.

Many women with previous ablative breast surgery have an excess of skin and subcutaneous tissue lateral to the original breast site, which can be utilized as a pedicled fasciocutaneous flap. This flap was originally described as the lateral thoracodorsal flap (LTD) by Holmström and Lossing<sup>1</sup> in secondary implant breast reconstructions. Their seminal article has been followed by several publications describing the relevance of this flap, in combination with other flaps as well as a stand-alone option in oncoplastic or salvage breast surgery.<sup>2-6</sup> In accordance with the recent change in flap nomenclature, the pedicled LTD

From the \*Department of Plastic and Reconstructive Surgery, University Hospital of North Norway, Tromsø, Norway; and †Medical Imaging Research Group, Institute of Clinical Medicine, UiT, The Arctic University of Norway, Tromsø, Norway.

Received for publication June 24, 2017; accepted September 1, 2017.

Presented by the corresponding author at the 9th Congress for World Society for Reconstructive Microsurgery, June 14–17 2017, Seoul, Korea.

Drs. Sjøberg and de Weerd have contributed equally to the conception and design, acquisition of data, analysis, and interpretation of data. Prepublishing revision and final approval was performed in agreement.

Copyright © 2018 The Authors. Published by Wolters Kluwer Health, Inc. on behalf of The American Society of Plastic Surgeons. This is an open-access article distributed under the terms of the Creative Commons Attribution-Non Commercial-No Derivatives License 4.0 (CCBY-NC-ND), where it is permissible to download and share the work provided it is properly cited. The work cannot be changed in any way or used commercially without permission from the journal.

DOI: 10.1097/GOX.0000000000001562

**Disclosure:** The authors have no financial interest to declare in relation to the content of this article. The Article Processing Charge was paid for by a grant from the publication fund of UiT, The Arctic University of Norway.

flap should now more correctly be named the pedicled lateral intercostal artery perforator (LICAP) flap.<sup>7,8</sup>

At our institution, many patients wish to keep their breast size unchanged and therefore desire rather large reconstructions. The aim of our study was to assess the applicability of a novel combination of a free abdominal flap and a pedicled LICAP flap to achieve the desired breast size in selected patients. Being able to reconstruct larger breasts, we also hypothesized that there would be a reduced need for additional surgery to reach symmetry with the native breast in unilateral cases. Although the combination of a LICAP flap with other flaps already has been described in breast surgery, to the best of our knowledge there are no previous reports on the combined use of the LICAP flap and a free abdominal flap in secondary breast reconstruction.

## MATERIALS AND METHODS

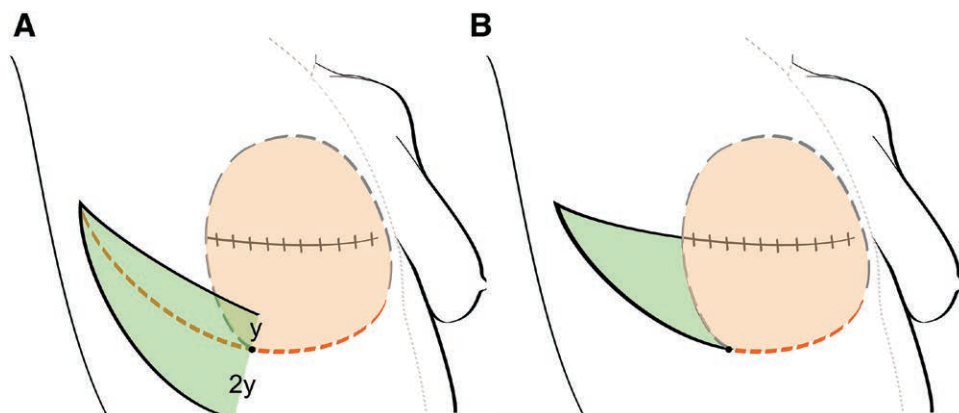
A retrospective study of prospectively collected data was performed in accordance with the principles outlined in the Declaration of Helsinki and in-house rules of the University Hospital. All patients consented in writing to participate in the study. Patients were nonsmokers or had stopped smoking at least 3 months before surgery. First, the maximal lower abdominal flap size was estimated based on a preoperative evaluation considering previous scars and body mass index (BMI). A pinch test was used to establish the maximal width that could be obtained. If patients asked for a breast volume larger than what could be provided by the free abdominal flap alone, the combination with an LICAP flap was discussed and a formal consent to proceed was obtained. The excess of skin and subcutaneous tissue on the ipsilateral thoracic wall was thereafter assessed, also by pinch test. The LICAP flap was initially designed as described by Holmström and Lossing<sup>1</sup>, with 2/3 of the base of the flap positioned below the anticipated sub-mammary fold and 1/3 above (Fig. 1A). We later modified the LICAP flap design, whereby the whole base of the flap was above the anticipated sub-mammary fold, as we found this to give a more natural appearance of the neo-mamma (Fig. 1B). The inferior border of the flap was marked a few centimeters shorter than the superior border.

## Surgical Technique

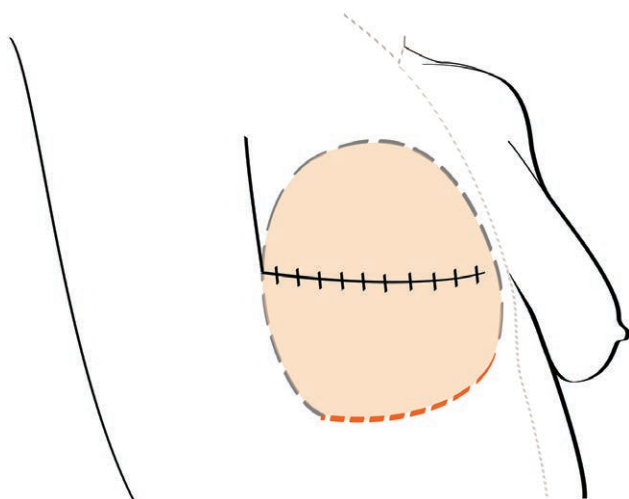
Using a two-team approach, one team raised the free abdominal free flap, whereas the other team prepared the recipient vessels and the LICAP flap. The abdominal flap was harvested using previously described techniques.<sup>9,10</sup> The superficial inferior epigastric vein was frequently included, to enable us to enhance the venous drainage in large flaps, as needed. On the thorax, the transverse postmastectomy scar was excised and the skin incision was extended in a cranial direction at the anterior axillary fold (Fig. 2). The mastectomy skin flaps were raised from the thoracic wall. The LICAP flap was harvested by incisions through skin and subcutaneous tissue along its superior and inferior borders, whereby the inferior incision was beveled in a caudal direction to recruit more tissue and protect the intercostal perforators. The flap was thereafter raised at subfascial level lateral to medial from the underlying serratus anterior musculature starting at the anterior border of the latissimus dorsi muscle. Hakakian et al.<sup>11</sup> have recently described a subcutaneous dissecting technique, that we used in a few cases. Once the basis of the flap was reached, no further dissection was done. Although the perforators can be skeletonized, this is not necessary for flap transposition. In fact, we recommend leaving a cuff of soft tissue for vascular pedicle protection.

The internal mammary vessels were used as recipients in all cases. Exposure and dissection was accomplished by removing a parasternal piece of the third or fourth rib. The microvascular anastomosis was done using end-to-end sutures on the arteries and a coupling device for the veins (GEM coupler; Synovis Micro Companies Alliance, Birmingham, Alabama). If the venous drainage of the flap was deemed insufficient based on clinical signs and dynamic infrared thermography, the superficial inferior epigastric vein was coupled to another local vein, most commonly the cephalic vein, to enhance the flap circulation.

The free flap was then partially deepithelialized and covered by the mastectomy flaps. The LICAP flap was transposed in a cranial direction to fill the defect created at the anterior axillary fold when raising the superior mastectomy flap. To optimize breast contour, the LICAP flap tip can be partially deepithelialized and buried. The LICAP flap donor site was closed using subcutaneous and



**Fig. 1.** Preoperative planning of the LICAP flap. A, The original LICAP flap design. B, The modified LICAP design by the authors. Note the change in pivot point to a more cranial position.



**Fig. 2.** Extending the transversal postmastectomy scar cranially at the lateral border of the breast site enables transfer of the LICAP flap and reduces scar contracture.

resorbable intracutaneous sutures. The remaining skin incisions on the thorax were closed using only resorbable intracutaneous sutures. A drain was placed beneath the free flap and in the LICAP flap donor site.

#### Statistical Analysis

Statistical analysis was performed using IBM SPSS Statistics ver. 22 (IBM Corp., Armonk, N.Y.). The following tests were used: independent samples *t* tests (flap size versus BMI class, relative use versus flap type or BMI class, flap weight and relative use versus surgical procedure), 1-way analysis of variance (ANOVA) (age, BMI, or flap size versus flap type) and binary logistic regression (symmetrizing surgery versus procedure type). The significance level was set at  $P = 0.05$  in all tests.

## RESULTS

During a 6-year period, 109 patients were operated for secondary autologous breast reconstruction, resulting in 121 abdominal flaps. The mean age was 52 years (range, 28–72) and the mean BMI was  $26.2 \text{ kg/m}^2$  (20.6–33.5). In addition to prior breast ablative surgery, 74 patients had received radiochemotherapy, whereas 11 patients had only radiotherapy, and 8 patients had only chemotherapy. The number of deep inferior epigastric artery perforator (DIEAP) flaps and muscle sparing transverse rectus abdominis (ms-TRAM) flaps was 100 and 16, respectively. There were 5 superficial inferior epigastric artery flaps. There was no statistical difference in age and BMI between patients grouped by flap type. The ms-TRAM flaps were significantly larger [mean weight 787 g (range, 453–1270)], than the DIEAP flaps [666 g (218–1124)], and the superficial inferior epigastric artery flaps [561 g (470–602)]. Abdominal flap size was also related to patients' BMI; The 42 patients with BMI over  $27 \text{ kg/m}^2$  had significantly larger flaps [mean weight, 762 g (250–1270)] compared with the 67 patients with BMI at or lower than  $27 \text{ kg/m}^2$  [623 g (218–988)]. Regarding the available lower abdominal tissue, a mean of 75% (45–100%) of the transverse flap was

used to reconstruct the breast, with no difference between ms-TRAM and DIEAP flap procedures. There was a tendency to use less of the total transverse flap in patients with BMI over  $27 \text{ kg/m}^2$  (mean, 71%) compared with patients with lower BMI (mean, 77%;  $P = 0.1$ ). The range of the relative use was equal for both groups (46–100%).

The free abdominal flap was combined with an LICAP flap in 76 patients (82 LICAP flaps), in 70 unilateral and 6 bilateral reconstructions. The remaining 33 patients with only free abdominal flaps comprised 27 unilateral and 6 bilateral cases. Comparing unilateral breast reconstructions with the LICAP flaps to the ones without, there was no significant difference in mean flap weight (702 versus 682 g) or the amount of abdominal tissue that was used (68% versus 75%). The same held true for bilateral cases, in which each breast was reconstructed with half of the abdominal flap. The mean flap weight was 658 g for patients with the combined procedure compared with 549 g for patients with only free abdominal flap reconstructions. The mean length and width of the LICAP flaps were 11 cm (5–15 cm) and 6 cm (4–9 cm), respectively.

Two ms-TRAM flaps and 2 DIEAP flaps failed completely, and these 4 patients were therefore excluded from the statistical analysis concerning the need for additional symmetrizing surgery. All of them had received both radio- and chemotherapy. In general, all LICAP flaps survived. Sixteen LTD flaps developed a necrotic tip and 5 LTD flaps showed partial epidermolysis. The overall complication rate of the LTD flaps was 26% (21/82). Thirteen of the 21 LTD flap-related complications occurred in patients with previous radiotherapy.

Follow-up data were available for all the 105 patients with successful reconstructions (117 breasts). Additional surgery to improve breast symmetry was needed in 47 of the 79 reconstructions (57%) with the combined procedure compared with 18 of the 38 reconstructions (47%) without LICAP flap. This difference in frequency was not statistically significant. Symmetrizing surgery was also equally frequent for patients, when grouped by BMI class (more or less than  $27 \text{ kg/m}^2$ ). The most commonly performed symmetrizing procedures were contralateral breast reduction for patients with LICAP flaps and fat transfer to the native breast for patients without LICAP flaps.

## DISCUSSION

The major goal in breast reconstruction is creating a natural looking breast with adequate volume and shape. Beautiful results can be obtained with the use of a free abdominal flap. However, previous abdominal surgery can reduce the availability of abdominal tissue and will, together with obesity, increase the risk for complications in relation to both donor sites and flaps.<sup>12–14</sup> Furthermore, in patients with thin body configuration and large breasts, the entire lower abdominal tissue might be needed to create an appropriate breast size. There are various surgical techniques to recruit the whole flap, including double pedicle, stacked flaps, and other methods to increase flap projection.<sup>15–18</sup> All these will increase the complexity of the surgery and, thereby put the patient at greater risk for

complications. The patients at our institution often prefer to keep their original breast size. Even overweight patients may, for various reasons, not always have an abdominal pannus to achieve that, keeping in mind that these patients often have a large remaining breast to go with their general body habitus. We therefore looked for additional tissue to create a larger neo-mamma without complex harvesting procedures or substantially increased risk for inadvertent results.

### General Impression

In this study, we have combined free abdominal flaps with pedicled LICAP flaps, to provide extra volume in secondary breast reconstructions. In addition to larger breast size, we observed increased projection of the reconstructed breast with the combined procedure, as the free abdominal flap could be positioned more medially resulting from the lateral support from the LICAP flap, in comparison to the reconstructions in which we did not use LICAP flaps. Harvesting the LICAP flap did not increase operation time. The LICAP flap tissue lateral to the original breast site is often annoying and many patients ask to have this reduced anyhow. Still, although rather inconspicuous, harvesting a LICAP flap will result in additional scarring in the axilla, which potentially might cause additional postoperative morbidity.

### Protecting the Pedicle in Large Reconstructions

Voluminous subcutaneous tissue, in relation to the area of skin surface of the free abdominal flap, can sometimes cause high tension at the suture lines and may result in inadvertent compression on the vascular pedicle after inset. Excision of subcutaneous tissue to reduce the flap volume would result in a smaller breast with less projection. In these situations, the LICAP flap can provide additional skin coverage and thereby reduce the risk for high tension on the sutures and pedicle compression. Furthermore, the skin surplus enables the surgeon to create more ptosis of the reconstructed breast if needed.

### Symmetrizing Procedures

The novel combination of flaps presented in this study did not result in a reduced need for breast symmetrization, contrary to our hypothesis. Despite using a mean of 75% of the abdominal tissue and a LICAP flap to augment volume, the majority of patients still asked for additional surgery to achieve symmetry. In the group of patients with the combined procedure, breast reduction of the remaining breast was the most frequently performed procedure. We believe that this can be explained by the fact that many of our patients had a large remaining breast that we could not match with the available flaps. Although we used the entire lower abdominal tissue in some patients, more often we decided to discard zone 4 and a part of zone 3, in situations where the distal flap perfusion was insufficient on preoperative assessment. In a recent article, Wade et al.<sup>19</sup> reported on contralateral breast symmetrization after unilateral DIEP flap breast reconstructions, finding that almost half of their patients had additional surgery done. An interesting finding of our study is the high percentage

of patients who asked for the combined procedure. We have the impression that our patients commonly ask for a large-volume breast reconstruction. In patients who had their breast reconstructed with only the free abdominal flap, the most frequently performed additional procedure was fat transplantation to the contralateral native breast to increase its volume. The need for additional surgery in our study was not related to BMI. Although patients with high BMI often have more surplus tissue on the lower abdomen, these patients also commonly wish for larger breast reconstructions. The main indications for symmetrizing surgery were unequal size and ptosis of the non-operated breast.

### Complications

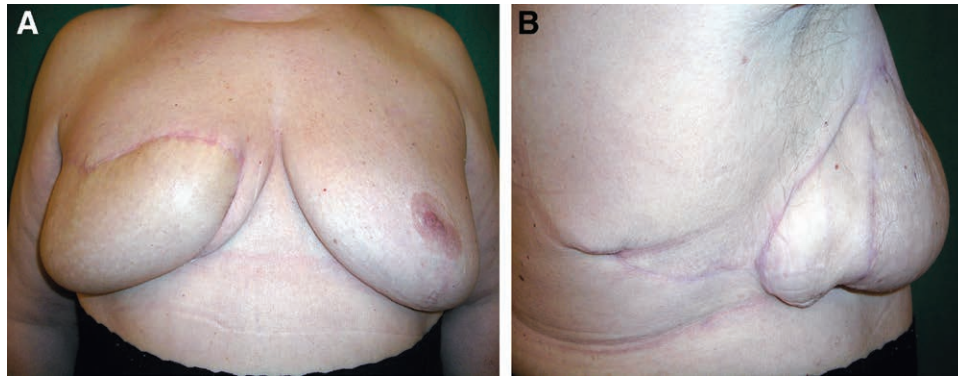
A few patients developed early postoperative complications and required secondary revisions. The risk for complications in autologous breast reconstruction are well known and relate to flap type, length of surgery, and patient characteristics.<sup>20–22</sup> Our complication rate did not differ from previous reports.<sup>12</sup> Regarding LICAP flap-related complications, our early complication rate at 26% falls within the previously reported incidence at 12–36%.<sup>2,22,23</sup> These flap complications can be considered minor and are easily treated at the outpatient clinic. Commonly reported risk factors are high BMI, smoking, and lengthy flaps. Because the LICAP flap does not have a true axial perfusion, the distal flap circulation is difficult to predict, resulting in an increased risk for partial epidermolysis and tip necrosis. We therefore limited the length of the LICAP flaps to maximally 15 centimeters, in accordance with previously reported recommendations.<sup>23</sup> Still we observed tip necrosis in 16 LICAP flaps, mainly in patients who had received radiotherapy. This has also been reported by others.<sup>24</sup> Contrary to some studies, we did not find any correlation between BMI and LICAP flap complications.<sup>22</sup>

### Novel LICAP Flap Design

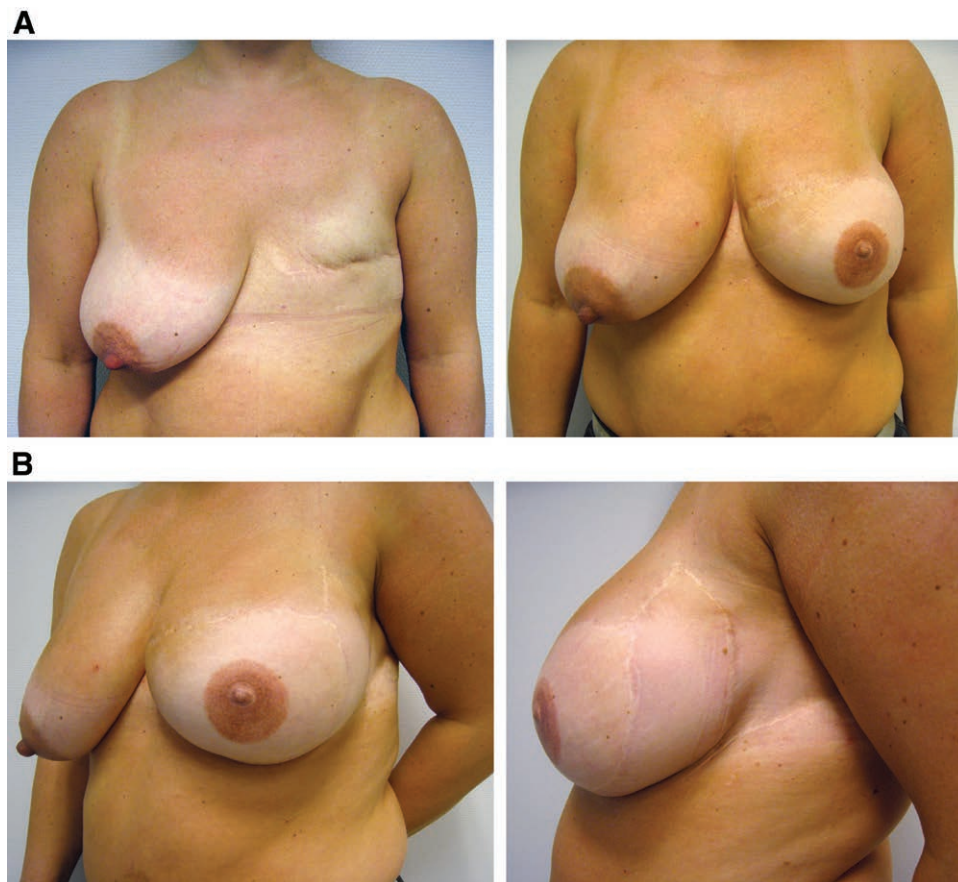
We modified the LICAP flap design as compared with the description by Lossing et al.<sup>25</sup> In our hands, the combination of the original flap outline and a free abdominal flap resulted in an unsightly box-form appearance of the new breast (Fig. 3). A similar square shape was also reported by Hudson<sup>3</sup>, when using the combination of a pedicled TRAM and a LICAP flap. This is related to the LICAP flap pivot point being at the inferolateral border of the breast. Our modification transposes the pivot point more superiorly due to the fact that the inferior border of the LICAP flap is placed at the anticipated submammary fold. The result is a more natural contour in the inferior and lateral part of the breast (Fig. 4). In any case, the perforators arising from the serratus anterior muscle need to be protected, when the base of the LICAP flap is reached during the subfascial dissection.

### Postoperative Considerations

It is important to avoid using a tight bandage or bra postoperatively, since this might cause inadvertent compression on the lateral intercostal perforators. Following mastectomy, some patients will experience unsightly and



**Fig. 3.** Postoperative result in a 69-year-old patient after breast reconstruction with a free ms-TRAM flap combined with an LICAP flap, using the original LICAP design. Lateral (A) and anterior view (B). This design can result in an unsightly box-form, as illustrated.



**Fig. 4.** Postoperative result in a 41-year-old patient after breast reconstruction using a DIEAP flap combined with an LICAP flap of the modified design. Lateral (A) and anterior view (B). Note the improved lateral contour and ptosis.

tense contracture of the transversal scar. Since this scar is intersected laterally with soft skin and subcutaneous tissue from the LICAP flap, the tension is reduced and the esthetical appearance improved. The transposed LICAP flap also allows for more tension free inset of the free abdominal flap beneath the raised mastectomy skin flaps. Finally, the distal part of the LICAP flap can contribute to recreate the lateral cranial fullness seen in a natural breast. The scars in the axilla and in the lateral part of the

neo-mamma can be easily hidden using regular clothing and were well tolerated by our patients. It is worth noticing that the scars after the LICAP flap procedure do not reach onto the back, as would be the case when using a latissimus dorsi or thoracodorsal artery perforator flap. Esthetically, the LICAP flap enabled us to create a breast with a more natural shape, more ptosis, and an improved lateral contour, even in patients with inadequate abdominal flap volume to match their preoperative desires.

## CONCLUSIONS

The combination of a free abdominal flap and a pedicled LICAP flap allows for the reconstruction of larger breasts in patients with marginal tissue redundancy on the abdomen. The LICAP flap provides a natural lateral contour to the reconstructed breast and can contribute to more projection as well as increased ptosis. The procedure is simple and safe without adding extra operative time or unsightly scars. To minimize postoperative complications, the length of the LICAP flap and previous local radiotherapy need to be considered. Many patients still opt for additional procedures to achieve optimal breast symmetry.

**Thomas Sjøberg, MD**

Department of Plastic and Reconstructive surgery  
University Hospital of North Norway  
PO Box 100  
N- 9038 Tromsø, Norway  
E-mail: thomas.sjoberg@unn.no

## ACKNOWLEDGMENTS

The authors thank Mr. Knut Steinnes, Department of Medical Physiology, Faculty of Medicine, UiT The Arctic University of Norway, Tromsø, Norway for his assistance in preparing the figures.

## REFERENCES

- Holmström H, Lossing C. The lateral thoracodorsal flap in breast reconstruction. *Plast Reconstr Surg*. 1986;77:933–943.
- Blomqvist L, Malm M, Holmström H, et al. The lateral thoracodorsal flap in breast reconstruction: a comparison between two plastic surgical centres. *Scand J Plast Reconstr Surg Hand Surg*. 2000;34:327–330.
- Hudson DA. Aesthetic modification for delayed autologous breast reconstruction: using a thoracodorsal flap to create a breast pocket. *Ann Plast Surg*. 2001;47:589–593.
- Kijima Y, Yoshinaka H, Funasako Y, et al. Immediate reconstruction using thoracodorsal adipofascial flap after partial mastectomy. *Breast*. 2009;18:126–129.
- de Weerd L, Woerdeman LA, Hage JJ. The lateral thoracodorsal flap as a salvage procedure for partial transverse rectus abdominis myocutaneous or deep inferior epigastric perforator flap loss in breast reconstruction. *Ann Plast Surg*. 2005;54:590–594.
- Munhoz AM, Montag E, Arruda EG, et al. The role of the lateral thoracodorsal fasciocutaneous flap in immediate conservative breast surgery reconstruction. *Plast Reconstr Surg*. 2006;117:1699–1710.
- Blondeel PN, Van Landuyt KH, Monstrey SJ, et al. The “Gent” consensus on perforator flap terminology: preliminary definitions. *Plast Reconstr Surg*. 2003;112:1378–1383; quiz 1383, 1516; discussion 1384.
- Sjøberg T, de Weerd L. Lateral thoracodorsal flap or lateral intercostal artery perforator flap: what is in the name? *Ann Plast Surg*. 2017;78:600.
- Blondeel PN, Morrison CM, Allen RJ. The deep inferior epigastric artery perforator (DIEAP) flap. In: Grotting JC, Neligan PC, eds. *Plastic Surgery*. 3 ed. Elsevier; 2012;435–456.
- Chang DW. Breast reconstruction with microvascular MS-TRAM and DIEP flaps. *Arch Plast Surg*. 2012;39:3–10.
- Hakakian CS, Lockhart RA, Kulber DA, et al. Lateral intercostal artery perforator flap in breast reconstruction: a simplified pedicle permits an expanded role. *Ann Plast Surg*. 2016;76:S184–S190.
- Mehrara BJ, Santoro TD, Arcilla E, et al. Complications after microvascular breast reconstruction: experience with 1195 flaps. *Plast Reconstr Surg*. 2006;118:1100–1119; discussion 1110.
- Roostaean J, Yoon AP, Sanchez IS, et al. The effect of prior abdominal surgery on abdominally based free flaps in breast reconstruction. *Plast Reconstr Surg*. 2014;133:247e–255e.
- Butler PD, Wu LC. Abdominal perforator vs. muscle sparing flaps for breast reconstruction. *Gland Surg*. 2015;4:212–221.
- Chang EI, Kronowitz SJ. Dual-pedicle flap for unilateral autologous breast reconstruction revisited: evolution and optimization of flap design over 15 years. *Plast Reconstr Surg*. 2016;137:1372–1380.
- DellaCroce FJ, Sullivan SK, Trahan C. Stacked deep inferior epigastric perforator flap breast reconstruction: a review of 110 flaps in 55 cases over 3 years. *Plast Reconstr Surg*. 2011;127:1093–1099.
- Patel NG, Ramakrishnan V. Microsurgical tissue transfer in breast reconstruction. *Clin Plast Surg*. 2017;44:345–359.
- Salgarello M, Barone-Adesi L, Sturla M, et al. Needing a large DIEAP flap for unilateral breast reconstruction: double-pedicle flap and unipedicle flap with additional venous discharge. *Microsurgery*. 2010;30:111–117.
- Wade RG, Marongiu F, Sassoon EM, et al. Contralateral breast symmetrisation in unilateral DIEP flap breast reconstruction. *J Plast Reconstr Aesthet Surg*. 2016;69:1363–1373.
- Rao S, Stolle EC, Sher S, et al. A multiple logistic regression analysis of complications following microsurgical breast reconstruction. *Gland Surg*. 2014;3:226–231.
- Massenburg BB, Sanati-Mehrziy P, Ingargiola MJ, et al. Flap failure and wound complications in autologous breast reconstruction: a national perspective. *Aesthetic Plast Surg*. 2015;39:902–909.
- Thorarinsson A, Frojd V, Kolby L et al. Blood loss and duration of surgery are independent risk factors for complications after breast reconstruction. *J Plast Surg Hand Surg*. 2017;1–9.
- Woerdeman LA, van Schijndel AW, Hage JJ, et al. Verifying surgical results and risk factors of the lateral thoracodorsal flap. *Plast Reconstr Surg*. 2004;113:196–203; discussion 204.
- Blomqvist L, Malm M. Clinical experience with the lateral thoracodorsal flap in breast reconstruction. *Ann Plast Surg*. 1999;43:7–13.
- Lossing C, Elander A, Gewalli F, et al. The lateral thoracodorsal flap in breast reconstruction: a long-term follow up study. *Scand J Plast Reconstr Surg Hand Surg*. 2001;35:183–192.