

Boll. Mus. reg. Sci. nat. Torino	Vol. 28 - N. 1	pp. 29-36	31-10-2011
----------------------------------	----------------	-----------	------------

Laith A. JAWAD<sup>1</sup>, Armin KOUSHA<sup>2</sup>

## A case of vertebral coalescence and lateral line deformity in *Hypophthalmichthys nobilis* (Richardson, 1844) obtained from aquaculture activity in Iran

### ABSTRACT

Vertebral coalescence and malformation in the lateral line are reported in a specimen of cultured cyprinid fish *Hypophthalmichthys nobilis*. Severe vertebral fusion was observed and described. Lateral line showed unusual undulation in the trunk region. Genetic and epigenetic causes may be implicated in these anomalies.

Keywords: Abnormality, vertebral coalescence, lateral line, *Hypophthalmichthys nobilis*, Iran.

Spinal deformities in natural and reared fish populations are relatively well described and documented (Tutman *et al.*, 2000; Dulčić, 2004; Jawad, 2005). In wild fishes, the visible anomalies are usually encountered through fishing activities, angling, and scientific studies. They are used as indicators of water pollution, because of their high incidence in polluted areas (Bengtsson, 1979).

Fish reared in an aquacultural setting are exposed to different environmental cues and stimuli as compared with wild fish. Food, habitat, water quality, lighting, and sound may be well controlled in food-focused aquaculture, but these variables are only relevant to the extent that they limit growth rates or survival of the product (Schwartz *et al.*, 2005).

The quality of aquaculture-produced fish depends on organoleptic and morphological characteristics that are directly related to the quality of the fry and its diet (Dinis & Soares, 1993). In fish culture the frequencies of phenotypic anomalies can be higher than the wild population because environmental control ensures survival while in the wild predation and other components of natural

---

<sup>1</sup> Marine Science & Fisheries Centre, Ministry of Fisheries Wealth Muscat, Sultanate of Oman

<sup>2</sup> Norwegian College of Fisheries Science, University of Tromsø, Norway

selection can eliminate specimen showing different kinds of anomalies (Tave *et al.*, 1982).

In aquaculture, skeletal abnormalities are a serious economical problem, as they reduce the market value of produced fish by affecting their morphology and survival (Koumoundouros *et al.*, 1997). Thus, it is important to describe abnormal phenotypes that usually occur in the cultured population and analyse their effects on economically important criteria, and discover their causes so that the frequencies may be controlled (Tave *et al.*, 1982).

Coalescence of vertebrae is an abnormality that has been reported to occur in several fish groups both culture and wild populations (Komada, 1980; Daoulas *et al.*, 1991; Divanach *et al.*, 1996). Such an extensive fusion of vertebrae is seriously affecting the shape of the body (Boglione *et al.*, 1993).

Abnormalities in the lateral line of fish, however, have received little scientific attention (Dawson, 1964, 1966, 1971; Dawson & Heal, 1971). Incidence of malformation of the lateral line is relatively common in captive bred fish (Carrillo *et al.*, 2001; Jawad *et al.*, 2007), but rare in the wild.

In fish, the mechanoreceptor neuromast cells, the major receptors for external vibrational and gravitational stimuli are associated with the lateral line system (Bleckmann, 1986). Thus, malformation of the lateral line will be expected to directly affect sense reception, which may disrupt schooling behaviour, predation avoidance, feeding, social communication (Partridge & Pitcher, 1980; Bleckmann, 1986) and possible survivorship.

In the present study, we describe a skeletal abnormality and a lateral line deformity in one hatchery adult fish specimen. No previous report on record about fish anomalies in cultured fish in Iran, thus the abnormal cases reported in the present study are considered the first record to the aquaculture industry in Iran. The objective of work is to contribute to the identification of specific anatomical descriptions useful to set up morphological quality criteria. It will be important to determine whether modifications outside of the lateral line are accompanied by histological and cytological modifications of its neuromasts.

Adult specimen of bighead carp *Hypophthalmichthys nobilis* (age 1) with skeletal deformity and lateral line malformation described in this study was obtained on January 2008 from the hatchery of the School of Fisheries, Azad University, Iran in Mazandaran Province and held in ground ponds. The specimen was grown using normal culture techniques. The system is a closed type supplied with running water from the nearby river and from wells present in the area. Water temperature ranges between 18-20 °C, pH at 7 water hardness is regularly mediated. Enrichment by fertilizers is the feeding method that usually followed. Since part of the water supplied to the tank is originated, therefore is a great possibility for the pollutants to be present in the aquaculture tanks. Both anomalies occurred naturally; neither the eggs nor the developing fry were treated with chemicals or physical stimuli to alter development. Both normal specimen (Fig. 1 above) used for comparison and the abnormal fish (Fig.1 below) came from the same pond. The specimen was radiographed with ordinary X-rays to interpret the skeletal anomaly and to verify any potential correlation between lateral




Fig. 1 - External morphology of bighead carp *Hypophthalmichthys nobilis*. Above: normal fish. Below: abnormal fish with lateral line and skeletal deformities.

line abnormality and osteological deformity (Fig. 2 above and below). A normal bighead carp specimen of similar total length and age was chosen as comparison specimen. Using the radiographs, the length of the fish from the anterior margin of the first vertebra to the posterior margin of the last vertebra is divided by average vertebra length to produce a ratio that is used to compare abnormal fish with normal fish. Head and tail length were excluded because the abnormality is in the thoracic region. Age was determined from scales viewed under light microscope.

Measurements for the deformed specimen are as follows: total length 455 mm, standard length 380 mm, fork length 405 mm, head length 112 mm, pre-orbital length 30 mm, eye diameter 14 mm, body depth 158 mm.

For the case of vertebral coalescence, the following features were observed in the vertebral column of the deformed carp specimen (Fig 2 below). Coalescence of vertebrae was noticed in the posterior and anterior parts of the thoracic and abdominal regions respectively. In the thoracic region at least three of the last vertebrae were involved in the fusion while in the abdominal region only the first abdominal vertebra is affected. Except for the first coalescent vertebra the remaining fused thoracic vertebrae shown to have completely lost their normal morphology and transformed into an irregular shape lump of bony material. On the other hand, the first abdominal vertebra has lost its anterior part only. Non-alignment and misplacement of the neural and haemal spines and ribs of the tho-

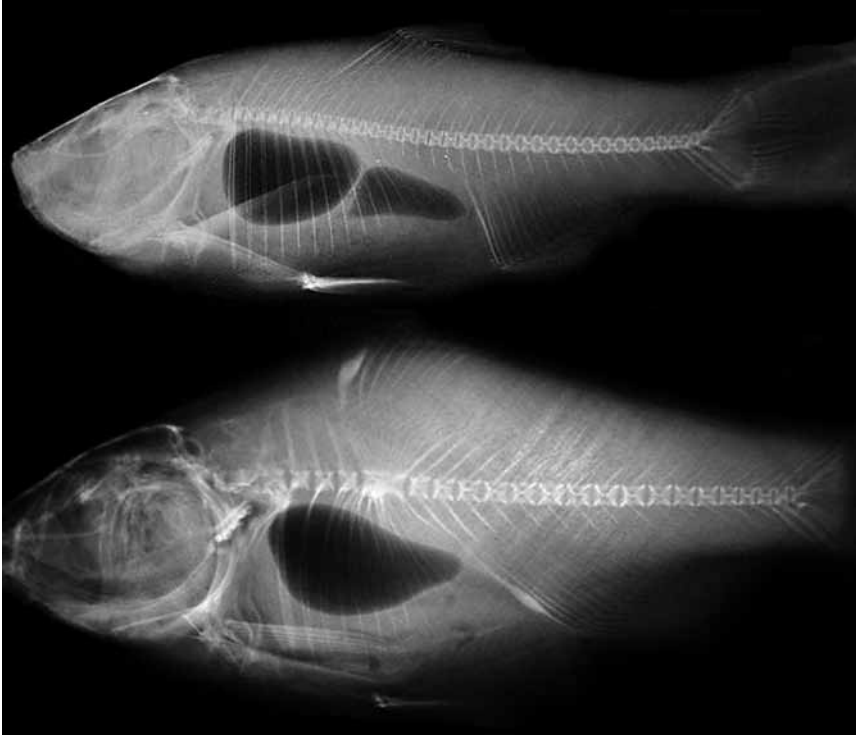


Fig. 2 - X-ray of bighead carp *Hypophthalmichthys nobilis*. Above: normal fish. Below: fish with skeletal deformity.

racic vertebrae were also observed. The thoracic vertebrae situated at the anterior part of the vertebral column and the abdominal vertebrae located after the first abdominal vertebra shown no evidence of anomalies.

The coalescence of vertebrae in *H. nobilis* had an obvious effect on body length. Normal *H. nobilis* had a body length/ vertebra length ratio of 96: 1. Fish specimen with coalescence had a body length/ vertebra length ratio of only 33: 1. The difference between the two ratios reflects the effects that the coalescent vertebrae had on body length.

The lateral line of the normal *H. nobilis* is continuous with a dorsoventral curvature starting behind the operculum to the posterior end of the dorsal fin. Then continue straight to the base of the caudal fin (Fig.1 above). In the abnormal carp specimen, the lateral line shows undulation with dorsoventral curvatures in the area behind the operculum to the posterior end of the anal fin. Lateral line is deformed in the both sides of the abnormal specimen (Fig. 1 below).

X-ray examination revealed vertebral coalescence in the region of the lateral line abnormalities. The scales around the affected area of the lateral line, however, exhibit no abnormalities.

The dark mass appeared in the x-ray of the normal and abnormal specimen is the air-bladder. In the normal specimen, the air-bladder is composed of two sections, the anterior part is rectangular in shape (size, 75 mm) while the posterior section is pear-shaped (size, 62.5 mm). For the abnormal specimen, there was only one part of the air-bladder. This part has wide pear-shaped (size, 112.5 mm).

The combination of genome, environment and developmental noise can produce what is known as phenotype (Scheiner, 1993). It is quite obvious that diversities in the genetic pool can determine variations in the developmental pattern. Developmental noise is a factor which can theoretically induce phenotypic differences in genetically identical individuals developing in identical environments (Divanach *et al.*, 1996). In this context, morphological variability in a genetically related population can supply a “size” of the developmental noise. In this regard, Soulè (1982) maintains that an augmentation of the phenotypic variability is a characteristic of biologic systems subjected to stress (like intensive rearing conditions, for instance) and that developmental noise reveals itself as a reduction of the intracellular order. The second factor, the environment, includes the influences exercised by external conditions, such as biotic and abiotic factors (Divanach *et al.*, 1996).

Skeletal abnormalities can be induced during embryonic and postembryonic periods of life through a complicated mechanism (Cataudella *et al.*, 1996; Koumoundouros *et al.*, 1994, 1995).

Gavaia *et al.*, (2002) stated that the development of vertebral fusion may be the most susceptible to rearing conditions in captivity. This deformity are among the most visible, since it can alter the shape and length of the fish depending on the severity and number of structures affected and consequently make it less attractive for the consumer. Nutritional factors such as levels of vitamin A and its precursors or f vitamin C in the diet have also been shown to affect the development of the skeletal structures in other fish species (Madson & Dalsgaard, 1999). In the present case of vertebral coalescence in the bighead carp, without additional data it is impossible to support the biotic and abiotic hypotheses in causing skeletal anomalies. Establishment of both nutritional and abiotic parameters involved in the mechanisms leading to the appearance of this deformity must be determined in order to prevent a high incidence of malformations particularly under intensive culture conditions.

Lateral line malformation has been attributed to several factors. The classical works of Popovici (1930) and Popov (1931) suggested that such anomaly is the result of irregular scalation, mechanical dysfunction, and environmental factors. Kozikowska (1960) and Whitefield *et al.* (1996) suggested that genetic mutations that affect the development of the lateral line produce such anomaly. Two genetic mutations were found to be responsible for lateral line defects in zebrafish, *Danio rerio* (Whitefield *et al.*, 1996). The association of the vertebral coalescence and lateral line deformity observed in the present study can be not completely unex-

pected case since such association is often seen in the cultured *Dicentrarchus labrax* and *Sparus aurata* (Divanach *et al.*, 1996).

Clearly more detailed investigation is required to determine the cause of lateral line deformity observed here, but the present records is nevertheless significant because it is considered the first record for the Iranian aquaculture system and in the same time indicates a prompt attention to the health management of culture ponds. Moreover is important to remember that the carp culture is the most important fisheries sector of Iranian aquaculture and its rapid development has attracted considerable attention in recent years (Salehi, 2004).

#### ACKNOWLEDGEMENTS

Our sincere thank goes to Raymond Coory (Te Papa Tongarewa, Wellington, New Zealand) for the technical assistant in producing image.

Laith A. JAWAD  
*Marine Science & Fisheries Centre,  
 Ministry of Fisheries Wealth,  
 P. O. Box 427, Postal Code 100,  
 Muscat, Sultanate of Oman*

Armin KOUSHA  
*Faculty of Biosciences, Fisheries and Economics,  
 Norwegian College of Fishery Science,  
 University of Tromso, Norway*

#### REFERENCES

- BENGTSSON B.E., 1979. Vertebral damage in fish induced by pollutants. In: Koeman J.H., Strik J.J.T.W.A. (eds.), *Sublethal effects of toxic chemicals on aquatic animals* (pp. 23-30). - Elsevier, Amsterdam.
- BLECKMANN H., 1986. Role of the lateral line in fish survival. - *Journal of Fish Biology*, 21: 239-249.
- BOGLIONE C., MARINO G., BERTOLINI B., ROSSI A., FERRERI F., CATAUDELLA S., 1993. Larval and post larval monitoring in sea bass: morphological approach to evaluate finfish seed quality. In: Barnabe G., Kestmont P. (eds.), *Aquaculture 92. Production, Environment and Quality* (pp. 189-204). - European Aquacultural Society, Special Publication 18.
- CARRILLO J., KOUMOUNDOUROS G., DIVANACH P., MARTINEZ J., 2001. Morphological malformations of the lateral line in reared gilthead sea bream (*Sparus auratus* L. 1758). - *Aquaculture*, 192: 281-290.
- CATAUDELLA S., LOY A., SCARDI M., BOGLIONE C., 1996. Anatomical descriptions and geometric morphometrics to evaluate larval and postlarval quality in Mediterranean Sea bass and sea bream from different hatcheries. - *International Symposium on Live Food Organisms and Environmental Control or Larviculture of Marine Animals*, September 1-4, 1996, Nagasaki, Japan.

- DAOULAS C.H., ECONOMOU N.A., BANTAVAS I., 1991. Osteological abnormalities in laboratory reared sea bass (*Dicentrarchus labrax*) fingerlings. - *Aquaculture*, 97: 169-180.
- DAWSON C., 1964. A bibliography of anomalies of fishes. - *Gulf Research Report*, 1: 308-399.
- DAWSON C., 1966. A bibliography of anomalies of fishes. Supplement 1. - *Gulf Research Report*, 2: 169-176.
- DAWSON C., 1971. A bibliography of anomalies of fishes. - *Gulf Research Report*, 3: 215-239.
- DAWSON C., HEAL E., 1971. A bibliography of anomalies of fishes. Supplement 3. - *Gulf Research Report*, 5: 35-41.
- DINIS M.T., SOARES F., 1993. Skeleton abnormalities in farmed fish. World aquaculture-from discovery to commercialization. - *World aquaculture Society, Special Publication*, 19: 349.
- DIVANACH P., BOGLIONE C., MENU B., KOUMOUNDOUROS G., KENTOURI M., CATAUDELLA S., 1996. Abnormalities in finfish mariculture: an overview of the problem, causes and solutions. In: Chantain B., Saroglia M., Sweetman J., Lavens P. (eds.), *Seabass and seabream culture: Problem and prospects. International Workshop. Verona, Italy. October 16-18, 1996.* - *European Aquacultural Society, Oostende, Belgium*.
- DULČIĆ J., 2004. Incidence of spinal deformities in natural populations of grass goby, *Zosterisessor phiocephalus* from the Karin Sea, Eastern Middle Adriatic. - *Cybiurn*, 28: 7-11.
- GAVAIA P.J., DINIS M.T., CANCELA M.L., 2002. Osteological development and abnormalities of the vertebral column and caudal skeleton in larval and juvenile stages of hatchery-reared Senegal sole (*Solea senegalensis*). - *Aquaculture*, 211: 305-323.
- JAWAD L.A., 2005. Scale deformities in Nile tilapia, *Oreochromis niloticus* (Actinopterygii: Cichlidae) from Sudan. - *Acta Ichthyologica et Piscatoria*, 35: 61-63.
- JAWAD L.A., AHYONG S.T., HOSIE A., 2007. Malformation of the lateral line and ambicolouration in the triplefin *Grahamina capito* (Jenyns, 1842) (Pisces: Tripterygiidae) from New Zealand. - *Annali del Museo civico di Storia naturale di Ferrara*, 9/10: 89-97.
- KOMADA N., 1980. Incidence of gross malformations and vertebral anomalies of natural and hatchery *Plecoglossus altivelis*. - *Copeia*, 1: 29-35.
- KOUMOUNDOUROS G., GAGLIARDI F., DIVANACH P., BOGLIONE C., CATAUDELLA S., KENTOURI M., 1997. Normal and abnormal osteological development of caudal fin in *Sparus auratus* L. fry. - *Aquaculture*, 149: 215-226.
- KOUMOUNDOUROS G., GAGLIARDI F., DIVANACH P., STEFANAKIS S., KENTOURI M., 1995. Osteological study of the origin and development of the abnormal caudal fin in gilthead sea bream (*Sparus auratus*) fry. - *Quality in Aquaculture. European Aquaculture Society, Special Publication No. 23*: 16-18.
- KOUMOUNDOUROS G., KIRIAKOS Z., DIVANACH P., KENTOURI M., 1994. Morphometric relationships as criteria for the evaluation of larval quality of gilthead sea bream. - *Aquaculture International*, 3: 143-149.
- KOZIKOWSKA Z., 1960. Interesting deviations from usual form in the lateral line of the carp, *Cyprinus carpio* L. from the breeding ponds near Radziadz in Silesia. - *Zoologica Polonica*, 10: 333-336.
- MADSON G., DALSGAARD I., 1999. Vertebral column deformities in farmed rainbow trout (*Oncorhynchus mykiss*). - *Aquaculture*, 171: 41-48.

- PARTRIDGE B.L., PITCHER T.J., 1980. The sensory basis of schools: relative roles of lateral line and vision. - *Journal of Comparative Physiology*, 135: 315-325.
- POPOV A.M., 1931. Einige bemerkungen über die variation der seitenlinien bei *Hexagramus stelleri* Til. (Pisces: Hexagrammidae). - *Zoologischer Anzeiger*, 95: 51-55.
- POPOVICI Z., 1930. Missbildungen. en der Seitenlinie bei einigen teleodeern. - *Zoologischer Anzeiger*, 91: 125-138.
- SALEHI H., 2004. Carp culture in Iran. - *Sustainable aquaculture*, 9(2): 8-11.
- SCHNEIDER S.M., 1993. Genetics and evolution of phenotypic plasticity. - *Annual Review of Ecological Systematics*, 24: 35-68.
- SCHWARTZ J., MARSHALL K., MORAN B., KAUFMAN L., 2005. Culture-induced abnormalities in Tautog. - *North American Journal of Aquaculture*, 67: 265-274.
- SOULÉ M.E., 1982. Allometric variation. I. The theory and some consequences. - *The American Naturalist*, 120: 751-764.
- TAVE D., BARTELS J.E., SMITHERMAN R.O., 1982. Stumpbody *Sarotherodon aureus* (Steindachner) (= *Tilapia aurea*) and tail-less *S. niloticus* (L.) (= *T. nilotica*): two vertebral anomalies and their effects on body length. - *Journal of Fish Biology*, 5: 487-494.
- TUTMAN P., GLAMUZINA B., SKARAMUCA B., KOŽUL V., GLAVIĆ N., LUČIĆ D., 2000. Incidence of spinal deformities in natural populations of sand smelt, *Atherina boyeri* (Risso, 1810) in the Neretva River Estuary, middle Adriatic. - *Fisheries Research*, 45: 61-64.
- WHITEFIELD T.T., GRANATO M., VAN EDEN F.J.M., SCHCH U., BRAND M., SEIKI F., HAFFTER P., MAMMERSCHMIDT M., HEISENBERG C-P., JIANG Y-J., KANE D.K., KELSH R.N., MULLINS M.C., ODENTHAL J., VOLHARD C.N., 1996. Mutations affecting development of the zebrafish inner ear and lateral line. - *Development*, 123: 241-254.