



**UIT**


**THE ARCTIC  
UNIVERSITY  
OF NORWAY**

Faculty of Health Sciences

# **Studies of peripheral nerve blocks for hand and shoulder surgery**

**Sandra Flohr-Madsen**

*A dissertation for the degree of Philosophiae Doctor – 2019*



## Table of contents

1	Acknowledgements .....	3
2	Abbreviations .....	4
3	List of papers .....	5
4	Abstract .....	6
4.1	Background .....	6
4.2	Methods .....	6
4.3	Results .....	7
4.4	Conclusions .....	7
5	Introduction .....	8
5.1	Brachial plexus anatomy .....	8
5.2	Peripheral nerve block .....	10
5.3	Peripheral nerve anatomy and Minimum effective volume .....	12
5.4	Pronation and supination of the hand and forearm .....	13
5.5	Innervation of the shoulder .....	15
5.6	The rational for a diaphragm-sparing shoulder block .....	21
6	Aims .....	24
6.1	Study I .....	24
6.2	Study II .....	24
6.3	Study III .....	24
7	Methods study I .....	25
7.1	Ethical considerations .....	25
7.2	The lateral sagittal infraclavicular block .....	25
7.3	The up-and-down staircase method .....	27
7.4	Block success assessment .....	28
8	Methods study II .....	31
8.1	Enrolment .....	31
8.2	The suprascapular nerve block .....	33
8.3	Block success assessment .....	34
8.4	Statistics .....	36
9	Methods study III .....	38
9.1	Ethical considerations .....	38
9.2	The superficial cervical plexus block .....	39

10	Results .....	43
10.1	Study I.....	43
10.2	Study II.....	43
10.3	Study III.....	44
11	Discussion study I .....	47
11.1	Validity and limitations.....	47
11.2	Minimum effective volume methods.....	49
12	Discussion study II .....	51
12.1	Optimal hand position for dorsal hand surgery .....	51
12.2	Suprascapular nerve block (SSNB) - the new approach .....	52
12.3	The block combination and the phrenic nerve.....	53
12.4	Limitations .....	55
13	Discussion study III .....	56
13.1	The novel block combination for arthroscopic shoulder surgery .....	56
13.2	SSNB success criterion.....	58
13.3	Adverse events .....	58
13.4	Limitations .....	59
14	Conclusions.....	60
14.1	Study I.....	60
14.2	Study II.....	60
14.3	Study III.....	60
15	Perspectives.....	61
16	References.....	63

## 1 Acknowledgements

The main support for this thesis comes from the Department of Anesthesiology, University Hospital of North Norway, where all the clinical studies were performed. I am also grateful to the Department of Anesthesiology at Sykehuset Sørlandet in Kristiansand for giving me time to work on this thesis.

I am deeply grateful to Lars Marius Ytrebø my main supervisor, for his endless enthusiasm, extensive support and belief in me. His continuous and infectious energy combined with his great knowledge has been very inspiring.

Also my second supervisor, Øivind Klaastad, deserves my warm thanks. Øivind's knowledge in the field of regional anesthesia seems endless and he has always been willing to share it. He has a love for-detail, from which I learned a lot during these years.

Many thanks to my other co-authors: Tom Wilsgaard, Katrin Valen, Dario Musso, Khaled Meknas, and medical student Siri Kregnes for their contributions.

My thanks also go to all the nurses in the recovery room, as well as the hand surgeons in Tromsø, who have contributed to this work. All of them felt a responsibility to help me complete-the studies successfully. This was a tremendous stimulation for me.

Everyone who contributed with their knowledge on these investigations, deserve my gratitude: Axel Sauter for discussions of our studies and for having drawn one of the figures. Per Brodal and Jan Due for stimulating discussions and suggestions in the-design of study II. Frode Abrahamsen for editing the video files for study II. Also, thanks to all patients who volunteered in the studies.

Last, but not least, I want to thank my husband Matias and our three kids Franciska, Storm and Malte Kristoffer. Thanks for being there and for supporting me.

## 2 Abbreviations

ASA	American Society of Anesthesiologist
CI	Confidence interval
GA	General anesthesia
ISB	Interscalene brachial plexus block
LA	Local anesthetic
LAST	Local anesthetic systemic toxicity
LSIB	Lateral sagittal infraclavicular brachial plexus block
MEV	Minimum effective volume
MEV <sub>50</sub>	Minimum effective volume in 50% of the patients
MEV <sub>95</sub>	Minimum effective volume in 95% of the patients
SCPB	Superficial cervical plexus block
SD	Standard deviation
SSN	Suprascapular nerve
SSNB	Suprascapular nerve block

### 3 List of papers

This thesis is based on the following papers, which will be referred to by their Roman numerals:

- I. Flohr-Madsen S., Ytrebø L. M., Kregnes S., Wilsgaard T., Klaastad Ø. Minimum effective volume of ropivacaine 7.5 mg/ml for an ultrasound-guided infraclavicular brachial plexus block. *Acta Anaesthesiol Scand.* 2013;57(4):495-501
  
- II. Flohr-Madsen S., Ytrebø L. M., Valen K., Wilsgaard T., Klaastad Ø. A randomised placebo-controlled trial examining the effect on hand supination after the addition of a suprascapular nerve block to infraclavicular brachial plexus blockade. *Anaesthesia.* 2016;71(8):938-47
  
- III. Musso D., Flohr-Madsen S., Meknas K., Wilsgaard T., Ytrebø L. M., Klaastad Ø. A novel combination of peripheral nerve blocks for arthroscopic shoulder surgery. *Acta Anaesthesiol Scand* 2017; 61(9): 1192-1202

## 4 Abstract

### 4.1 Background

The lateral sagittal infraclavicular block (LSIB) is a well-established anesthesia method for surgery distal to the shoulder. Performing regional anesthesia with a minimum effective volume (MEV) of local anesthetic (LA) may reduce the risk of systemic local anesthesia toxicity (LAST). For LSIB using ropivacaine 7.5 mg/ml the MEV was not known prior to our study.

LSIB tends to result in supination of the hand/forearm, which may inhibit surgical access to the dorsum of the hand. In study II we hypothesised that this supination may be reduced by the addition of a suprascapular nerve block (SSNB) to the LSIB.

Gold standard for intra- and postoperative pain management for patients undergoing arthroscopic shoulder surgery has been the interscalene brachial plexus block (ISB). Due to a high incidence of phrenic nerve block with this technique, diaphragm-sparing alternatives have been investigated. In study III we hypothesised that the combination of superficial cervical plexus block (SCPB), SSNB and LSIB would provide a good alternative to the ISB.

### 4.2 Methods

In study I twenty-five American Society of Anesthesiologists (ASA) physical status I-II patients scheduled for hand surgery received an ultrasound-guided LSIB with ropivacaine 7.5 mg/ml. The MEV for a successful block in 50% of the patients (MEV<sub>50</sub>) was determined by a staircase up-and-down method. Study II was a double-blind, randomized placebo-controlled study. We measured the degree of supination (as assessed by wrist angulation) 30 minutes after LSIB with (suprascapular

group) or without (control group) a supplementary SSNB. The surgeons assessed the intra-operative position of the hand/forearm as either “good” or “poor”. In study III, twenty ASA physical status I-III patients scheduled for arthroscopic shoulder surgery received a combination of SCPB, SSNB and LSIB. The blocks were tested 30 minutes after withdrawal of the needle from the last of the three blocks and we identified the proportion of patients who could be operated under light propofol sedation, without the need of opioids or artificial airway.

### 4.3 Results

MEVs in 50% and 95% of the patients who received a LSIB with ropivacaine 7.5 mg/ml were 19 ml [95% confidence interval (CI), 14 - 27] and 31 ml (95% CI, 18 – 45), respectively. In study II, mean (SD) wrist angulation was lower (33 (27) vs. 61 (44) degrees;  $p = 0.018$ ) and assessment of the hand position was better (11/11 vs. 6/11 rated as ‘good’;  $p = 0.04$ ) in the suprascapular group. In study III nineteen out of twenty patients (95%, CI 85 – 100) underwent arthroscopic shoulder surgery with only light propofol sedation and without any need for an artificial airway.

### 4.4 Conclusions

MEV<sub>95</sub> for an ultrasound-guided LSIB with ropivacaine 7.5 mg/ml was estimated to be 31 ml (95% CI, 18 – 45 ml). The addition of a SSNB to a LSIB can provide a better hand/forearm position for dorsal hand surgery. The novel block combination of SCPB, SSNB and LSIB is feasible and provides surgical anesthesia with good intraoperative conditions for surgeons and satisfactory postoperative analgesia in patients who have had arthroscopic shoulder surgery.



## 5 Introduction

### 5.1 Brachial plexus anatomy

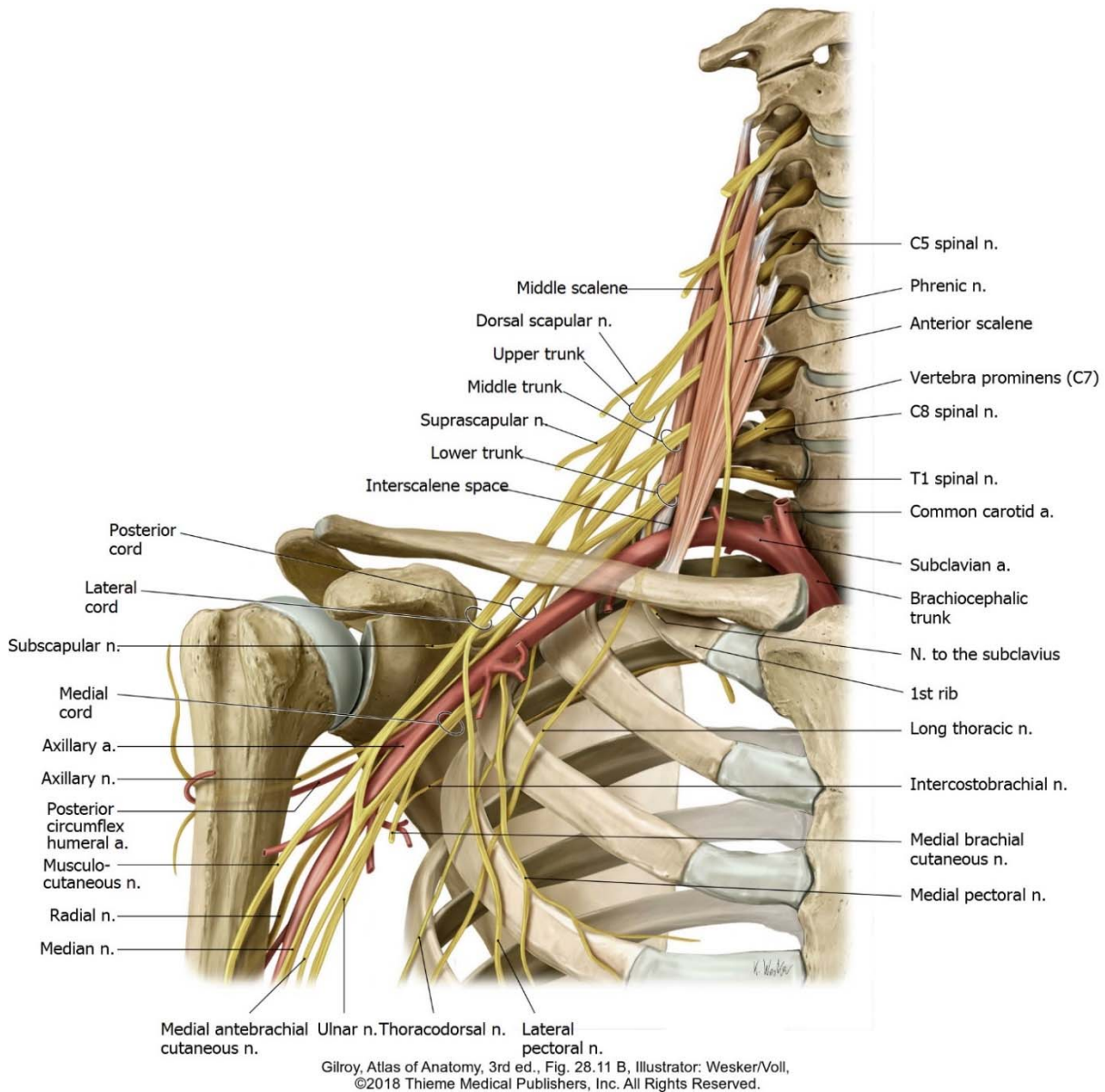
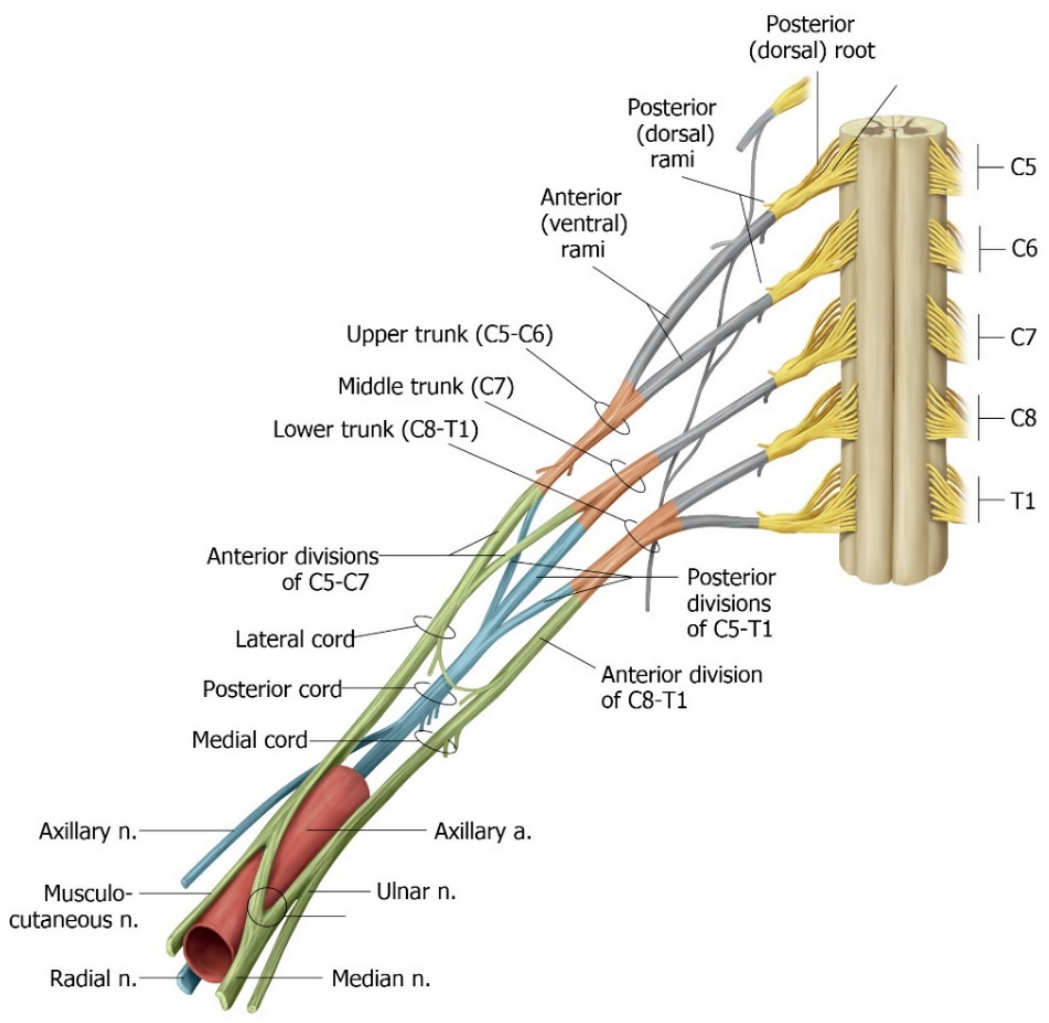


Figure 1. Brachial plexus. Gilroy et al., Atlas of Anatomy. All rights reserved. © Thieme 2018, [www.thieme.com](http://www.thieme.com)

The brachial plexus provides the innervation of the upper extremity and the shoulder<sup>1-3</sup>. It is formed by the ventral rami of the cervical spinal nerves C5-8 and the first thoracic spinal nerve T1. The roots of the brachial plexus cross the interscalene groove localized between the anterior and middle

scalene muscles. The roots of C5 and C6 form the superior trunk, C7 forms the middle trunk and of C8 and T1 the lower trunk. The suprascapular nerve (SSN) and the nerve to subclavius are derived from the upper trunk. Other nerves of particular interest are the dorsal scapular and phrenic nerves, which originate from the C5 root and from the C4 (C3 – C5) root, respectively. The long thoracic nerve originates from the C5-7 roots. Each trunk divides into two branches, the anterior and the posterior divisions.



Gilroy, Atlas of Anatomy, 3rd ed., Fig. 28.11 A, Illustrator: Wesker/Voll, ©2018 Thieme Medical Publishers, Inc. All Rights Reserved.

Figure 2: Roots, trunks, and cords of the brachial plexus. Gilroy et al., Atlas of Anatomy. All rights reserved. © Thieme 2018, [www.thieme.com](http://www.thieme.com)

Under the clavicle, the trunks reorganize to form three cords surrounding the axillary artery longitudinally. The anterior divisions of the upper and the middle trunk form the lateral cord. The posterior cord originates from posterior divisions of the trunks. The medial cord originates from the anterior division of the inferior trunk.

The three cords give rise to the terminal branches. Three nerves originate from the lateral cord: the lateral pectoral nerve, the musculocutaneous and the median nerve. However, the median nerve receives fibers from the medial cord as well. Four other nerves originate from the medial cord: the ulnar, the medial pectoral nerve, the medial cutaneous brachial and the medial cutaneous antebrachial nerve. The upper subscapular, the thoracodorsal, the lower subscapular, the axillary and the radial nerve originate from the posterior cord.

The brachial plexus is complex and anatomical variations have been found in up to 50% of the patients<sup>4</sup>. These variations can include all cords and terminal branches. Knowledge about this is crucial for the understanding why brachial plexus block may fail even in trained hands.

## 5.2 Peripheral nerve block

A nerve block is a temporary interruption of electrical signals traveling along nerve fibers and can be achieved by injection of local anesthetic (LA) close to the relevant nerve. The term “peripheral” is usually applied for nerve blocks performed distal to the spinal and epidural spaces.

Peripheral nerve blocks are used to provide surgical anesthesia, postoperative analgesia, and as a method to treat non-surgical pain. It offers distinct benefits over general anesthesia (GA) and provides analgesia that may be superior to other pain management alternatives in selected cases<sup>5-8</sup>.

Patients who have received a peripheral nerve block, spend shorter time in the post anesthesia care unit, receive less opioids and carry a lower risk of postoperative nausea and vomiting compared to patients who received GA<sup>9</sup>.

Peripheral nerve blocks were originally performed by using surface anatomical landmarks and needle paresthesia to confirm closeness of the needle tip to the target nerve. The nerve stimulator was introduced in the 1970`s. Stimulating the nerve with electrical current may induce contractions of the target muscle. Consequently, clinicians were no longer dependent on using paresthesia as a “guide” the clinician during the procedure.

Ultrasound was introduced in routine clinical practice around year 2000 and allowed clinicians to visualize anatomic structures in real time during the procedure. It thus provided simultaneous visualization of the actual nerve, needle, spread of LA, and relation to other neighbor structures close to the actual nerve, e.g. pleura and vessels.

Ultrasound-guided brachial plexus block was first used for the axillary approach in 1989 by Ting et al.<sup>10</sup> For infraclavicular blocks it was introduced in 1993 by Wu et al.<sup>11</sup>, followed by Ootaki et al. in 2000<sup>12</sup>. In 1994 Kapral et al.<sup>13</sup> was the first to published on sonographic experience with supraclavicular brachial plexus blocks. Resolution was initially poor, but improvements in ultrasound technology soon allowed developers to build high-resolution ultrasound machines. Sonographic guidance, affordable prices and a user friendly interface, have made ultrasound the preferable technique for peripheral nerve block guidance today.

However in modern practice, ultrasound and nerve stimulation may be used in combination to obtain real time imaging and confirm the identity of the targeted nerve. In study II and III we also applied a manometer to monitor injection pressure in order to avoid pressure induced nerve injury.

### 5.3 Peripheral nerve anatomy and Minimum effective volume

LAs prevent or relieve pain by interfering with normal nerve conduction. Peripheral nerves are similar in anatomic structure. The axons are surrounded by a loose connective tissue, the endoneurium. Numerous axons form the fascicle. A layer of connective tissue encircles the fascicle and is called the perineurium. A dense outermost sheath, the epineurium, surrounds all the fascicles. Blood vessels are located between the fascicles. A mixed peripheral nerve or nerve trunk consists of individual nerves surrounded by an epineurium.

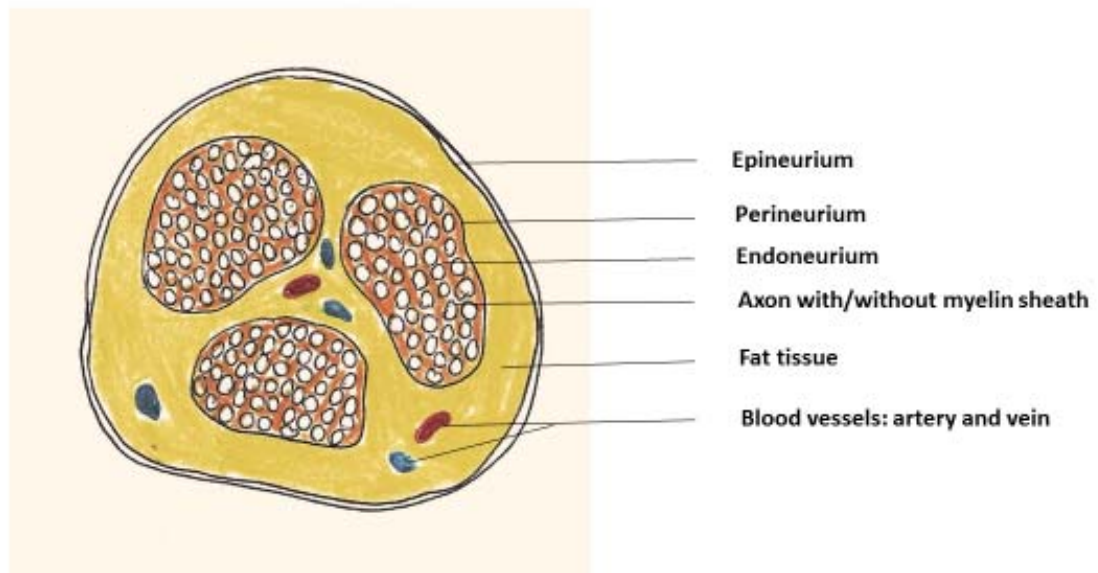


Figure 3: Drawing of a mixed peripheral nerve. Drawing by Sandra Flohr-Madsen

LAs bind to specific receptor sites on the sodium channels in nerves and block the voltage dependent sodium-influx in the cell. The resting potential becomes stabilized and an action potential can not longer be provoked. Both the chemical and pharmacologic properties of individual LA

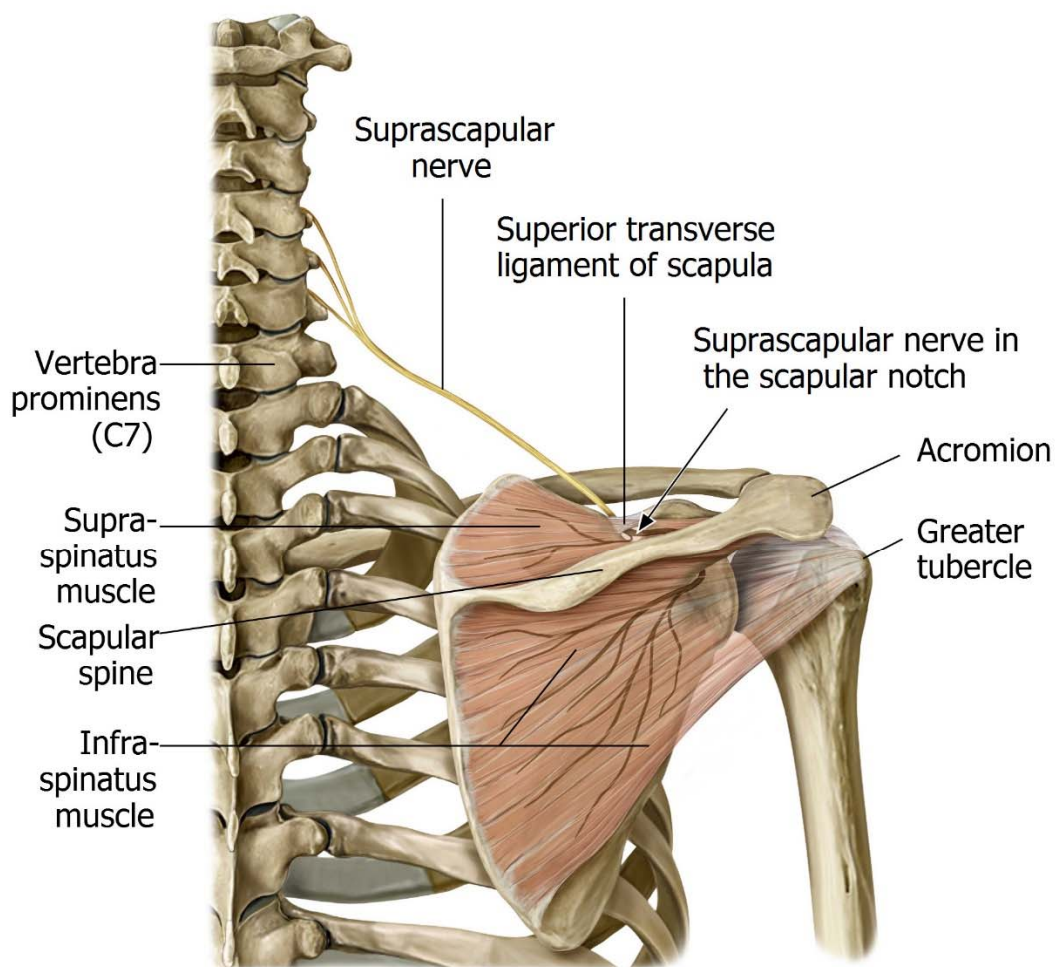
drugs determine their clinical properties. LA diffuses from the outer surface of the nerve to its core, along a concentration gradient. Consequently, nerves located in the outer mantle of the mixed nerve will be blocked first. The rate of diffusion across the epineurium is determined by the concentration of the drug, its degree of ionization (ionized LA diffuses more slowly), its hydrophobicity, and the physical characteristics of the tissue surrounding the nerve<sup>14</sup>.

LAs have, depending on their pharmacokinetic profile, varying degrees of toxicity. Another major risk factor is site of LA injection<sup>15,16</sup>. Upper limb blocks show an increased risk of systemic LA toxicity compared to other peripheral nerve blocks<sup>15</sup>. Therefore, data on minimum effective volumes (MEVs) for all relevant LAs at different injection sites are clinically desirable in order to reduce the total dose of LA.

#### 5.4 Pronation and supination of the hand and forearm

Supination of the hand and forearm usually occurs by lateral rotation of the radius. The responsible distal muscles are the supinator and brachioradial muscles, which are innervated by the radial nerve. Biceps brachii is supplied by the musculocutaneous nerve and also contributes to supination of the hand and forearm. In addition, when the upper limb is extended, supination may be obtained by lateral rotation of the humerus. The responsible muscles are then the infraspinatus, supraspinatus, posterior fibers of deltoid, teres minor and the long head of triceps muscles<sup>1-2</sup>. The deltoid and teres minor muscles are innervated by the axillary nerve, and the triceps by the radial nerve. All these nerves are normally blocked by a successfully performed lateral sagittal infraclavicular brachial plexus block (LSIB). However, the main lateral rotator of the humerus is the infraspinatus muscle, which along with the supraspinatus muscle, are innervated by the SSN. This nerve has not been reported to be affected by LSIB.

The SSN originates from the upper trunk of the brachial plexus. It contains fibers from the 5th and 6th cervical nerves. After branching off from the upper trunk, the SSN passes caudal to the inferior belly of the omohyoid muscle to the scapular notch, accompanying the suprascapular vein and artery. It passes the notch inferior to the superior transverse scapular ligament, before entering the supraspinatous fossa.



Schuenke, Atlas of Anatomy Vol. 1, 2nd Ed., Fig. 17.362 D, Illustrator: Karl Wesker, ©2018 Thieme Medical Publishers, Inc. All Rights Reserved.

Figure 4. Suprascapular nerve course. Gilroy et al., Atlas of Anatomy. All rights reserved. © Thieme 2018, [www.thieme.com](http://www.thieme.com)

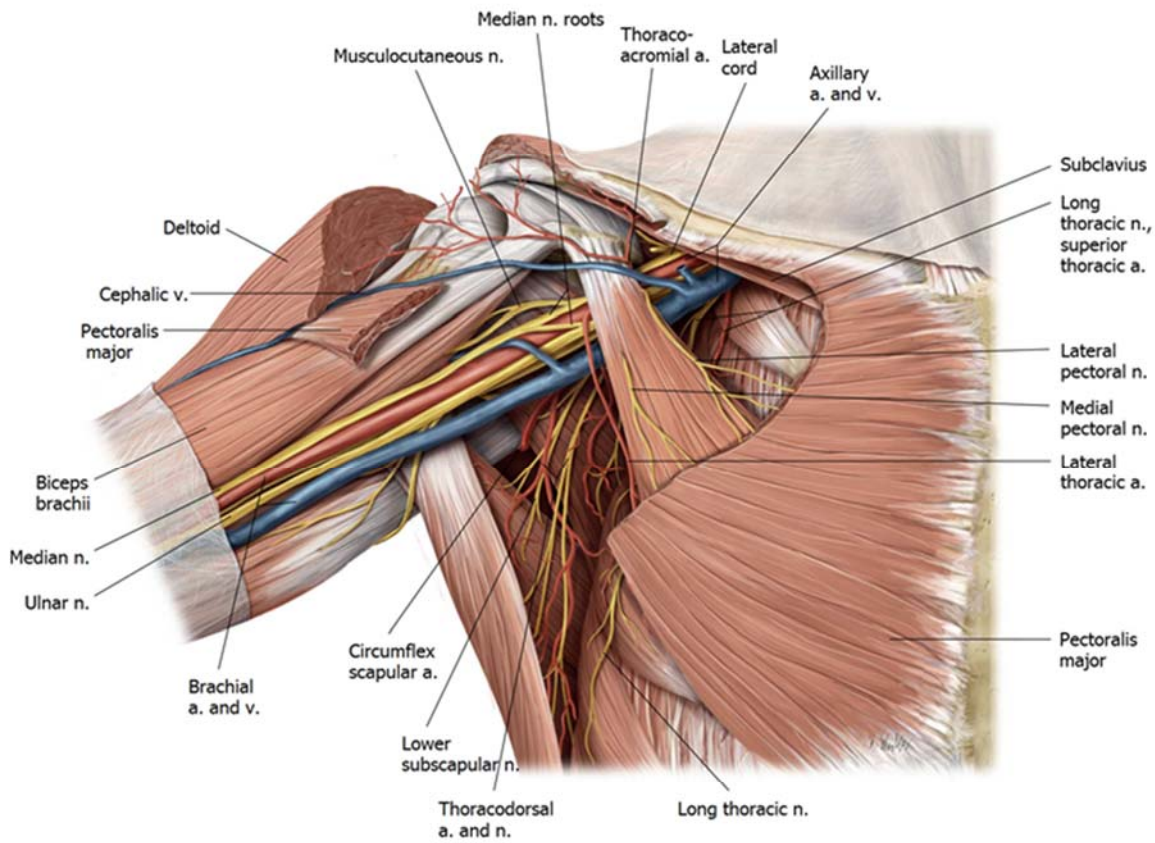
The nerve is a mixed nerve including both motor and sensory fibers. Motor fibres supply the supraspinatus and the infraspinatus muscles and sensory fibers innervate the acromioclavicular and the glenohumeral joints<sup>17,18</sup>. SSN does not normally carry sensory fibers to the skin.

One surgeon in our hospital was complaining that the LSIB tended to result in supination of the hand/forearm, which made surgical access to the dorsum of the hand challenging. We wanted to explore this original observation by a clinical study. We hypothesized that the supination may be reduced by the addition of a suprascapular nerve block (SSNB), which potentially would eliminate the lateral rotation of the humerus, caused by the supraspinatus and particularly infraspinatus muscle.

## 5.5 Innervation of the shoulder

The brachial plexus provides all motor and most of the sensory innervation of the shoulder joint. The anterior shoulder joint capsule is supplied by the subscapular, the axillary and the lateral pectoral nerves<sup>17</sup>. While the first two nerves are derived from posterior cord, the latter originates from the lateral cord. The axillary nerve innervates the anterior and inferior region of the shoulder joint, while the lateral pectoral nerve innervates the anterior and superior region. The medial anterior part is innervated by the subscapular nerve. Although disputed, the musculocutaneous nerve (originating from the lateral cord) may innervate an anterior and superior part of the shoulder joint.

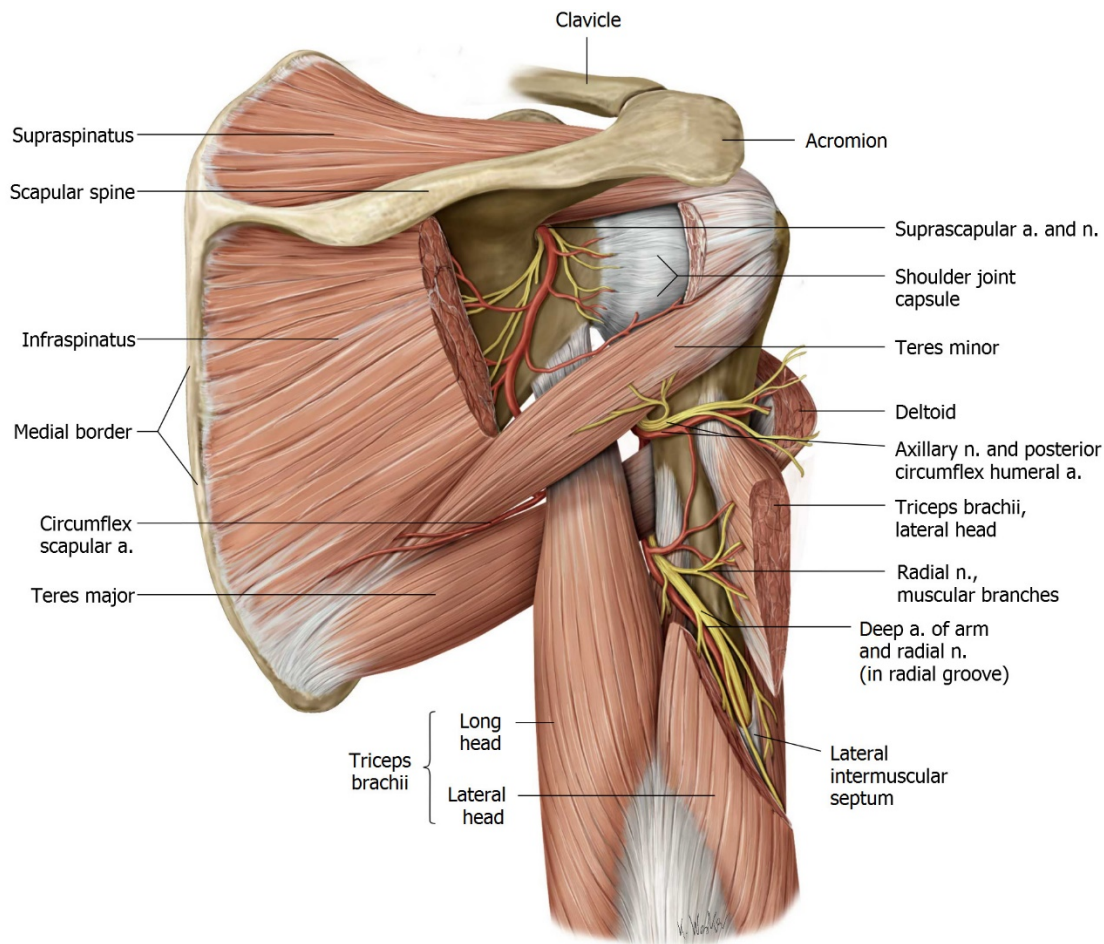




Gilroy, Atlas of Anatomy, 3rd ed., Fig. 28.34 A, Illustrator: Wesker/Voll, ©2018 Thieme Medical Publishers, Inc. All Rights Reserved.

Figure 5. Innervation of the shoulder. Anterior view of the right shoulder. Gilroy et al., Atlas of Anatomy. All rights reserved. © Thieme 2018, [www.thieme.com](http://www.thieme.com)

The posterior shoulder joint capsule receives articular branches from the SSN and small branches from the axillary nerves. The upper region is innervated by the suprascapular and the lower region by the axillary nerve.

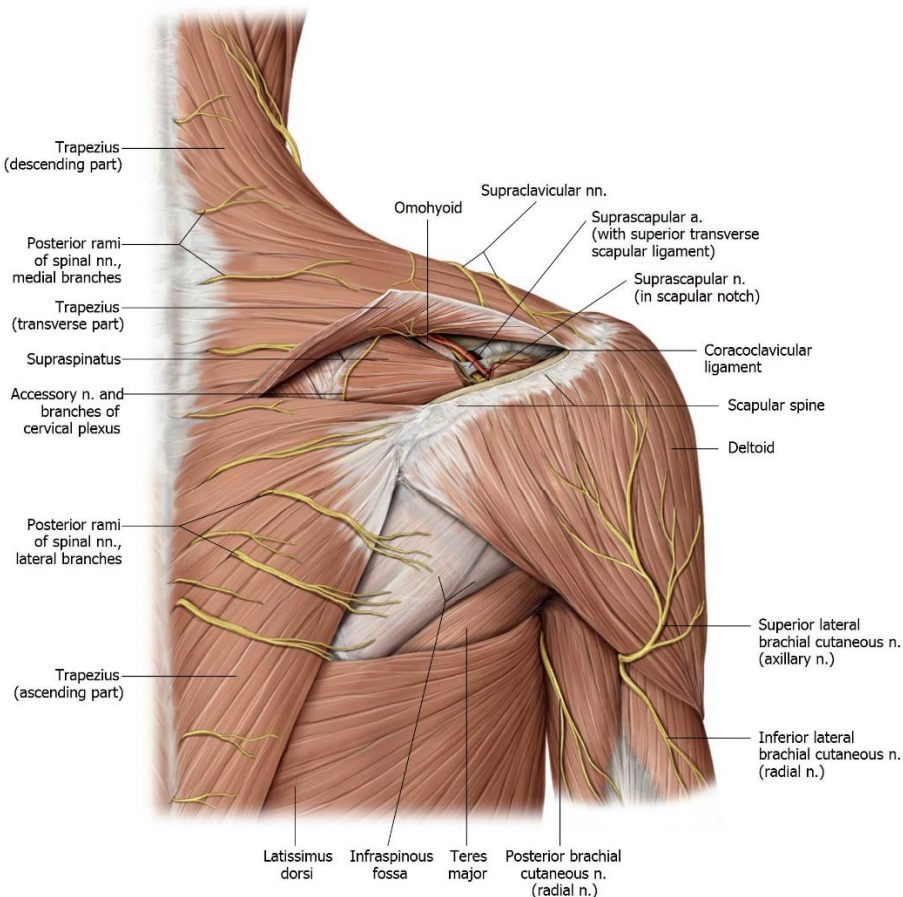


Gilroy, Atlas of Anatomy, 3rd ed., Fig. 28.30 B, Illustrator: Wesker/Voll, ©2018 Thieme Medical Publishers, Inc. All Rights Reserved.

Figure 6. Innervation of the shoulder. Posterior view of the right shoulder. Gilroy et al., Atlas of Anatomy. All rights reserved. © Thieme 2018, www.thieme.com

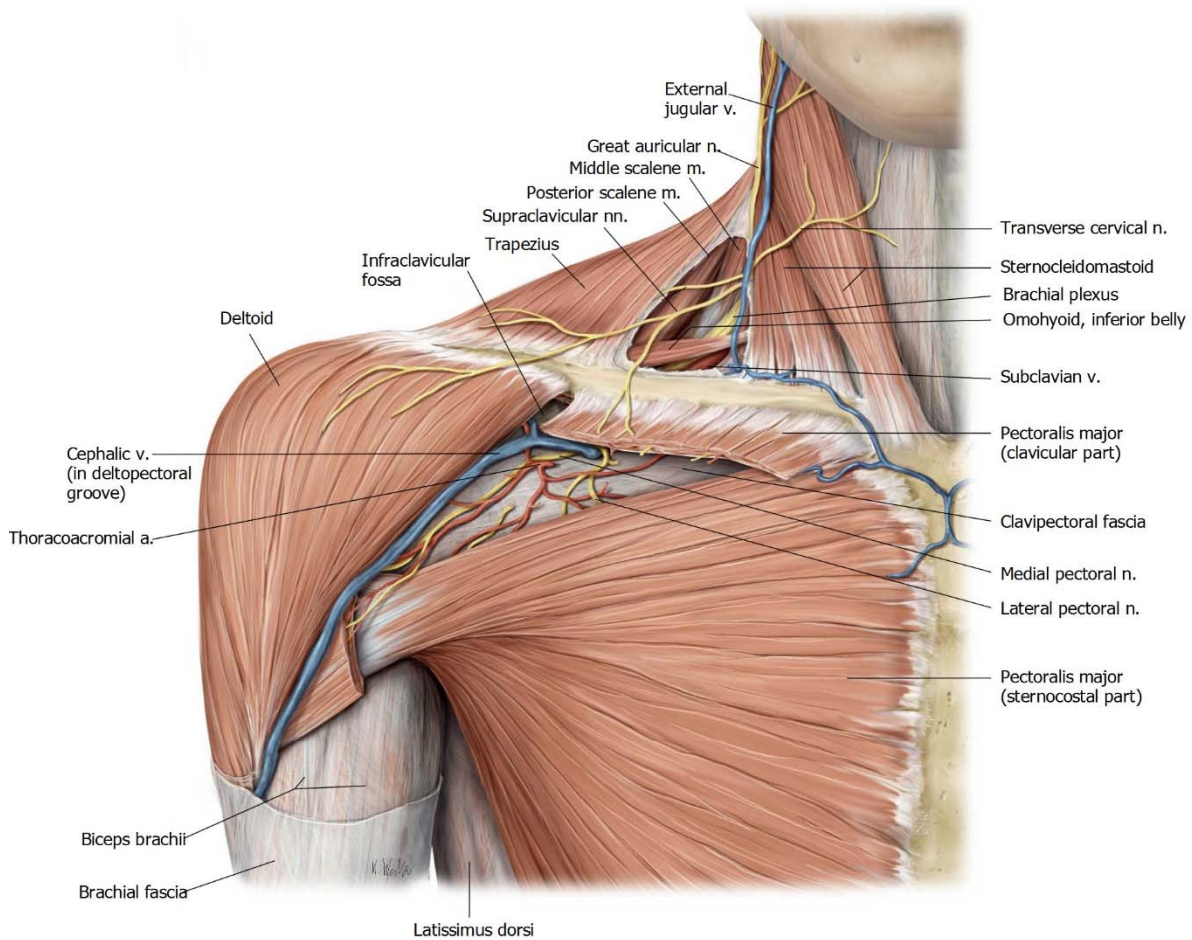
Three nerves of the brachial plexus contribute to the cutaneous innervation of the shoulder: the upper lateral brachial cutaneous nerve, a branch from the axillary nerve, the medial brachial cutaneous and the medial antebrachial cutaneous nerves, both diverging from the medial cord<sup>17</sup>. The first nerve innervates the skin over the deltoid muscle and the medial antebrachial cutaneous nerve the skin over the biceps muscle. The medial brachial cutaneous nerve innervates, together with the intercostobrachial cutaneous nerve, the upper medial side of the arm.

The cutaneous innervation of the shoulder's superior aspect, "the cape region", is supplied by the supraclavicular nerves<sup>17</sup>. These nerves originate from the lower part of the superficial cervical plexus (C3-4) and innervate the infraclavicular region, the skin over the pectoralis major and deltoid muscles and the cranial and posterior parts of the shoulder.



Gilroy, Atlas of Anatomy, 3rd ed., Fig. 28.29, Illustrator: Wesker/Voll, ©2018 Thieme Medical Publishers, Inc. All Rights Reserved.

Figure 7. Innervation of the skin. Posterior view of the right shoulder. Gilroy et al., Atlas of Anatomy. All rights reserved. © Thieme 2018, www.thieme.com



Gilroy, Atlas of Anatomy, 3rd ed., Fig. 28.31 B, Illustrator: Wesker/Voll, ©2018 Thieme Medical Publishers, Inc. All Rights Reserved.

Figure 8. Innervation of the skin. Anterior view of the right shoulder. Gilroy et al., Atlas of Anatomy. All rights reserved. © Thieme 2018, www.thieme.com

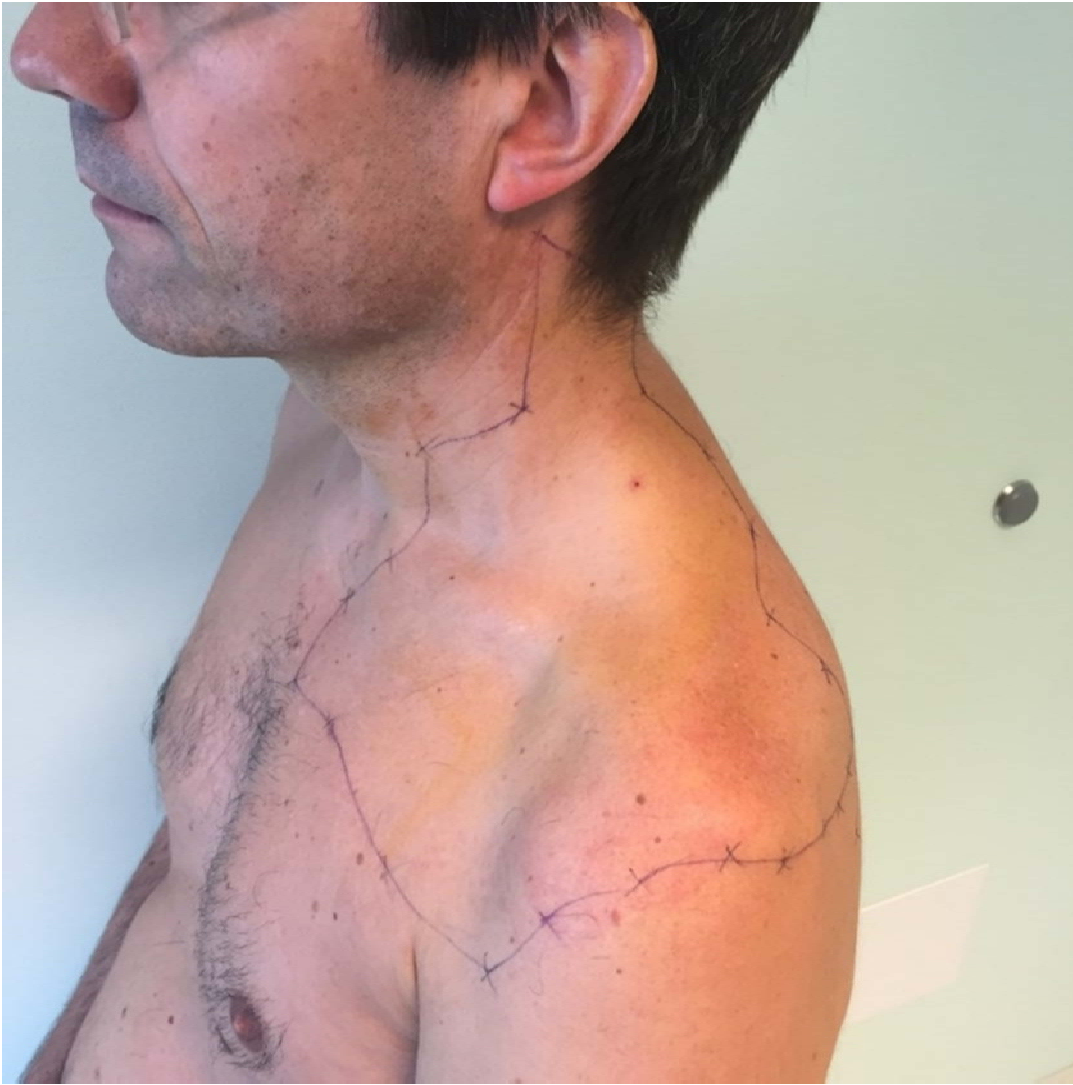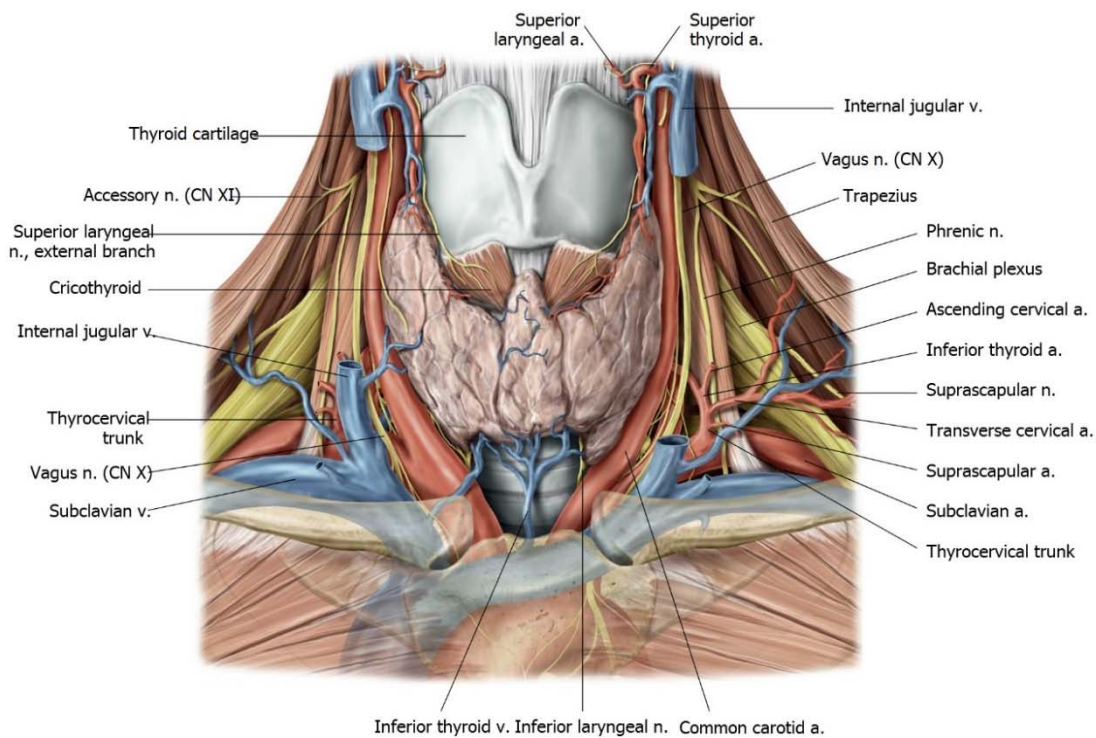


Figure 9: Analgesic territory 30 minutes after a selective superficial cervical plexus block performed on Lars Marius Ytrebø using 5 ml lidocaine 10 mg/ml.

In summary, a superficial cervical plexus block (SCPB), SSNB, and LSIB should theoretically block all nerves relevant for shoulder surgery.

## 5.6 The rationale for a diaphragm-sparing shoulder block

Interscalene brachial plexus block (ISB) has been the gold standard for intraoperative and postoperative pain management in patients undergoing shoulder surgery<sup>19,20</sup>. In expert hands, it has a very high success rate<sup>21</sup>, but may cause a wide spectrum of complications and side effects<sup>21-25</sup>. The risk of neurological complications, particularly concerning the phrenic nerve, can be explained by the short distance between the injection site (the interscalene groove) and the phrenic nerve (on the anterior aspect of the scalenus anterior [figure 10]). There are at least two potential causative mechanisms that may be involved; cranial LA spread toward the C3-C5 nerve roots and/or anterior LA spread from the interscalene groove towards the phrenic nerve.



Gilroy, Atlas of Anatomy, 3rd ed., Fig. 45.31 C, Illustrator: Wesker/Voll, ©2018 Thieme Medical Publishers, Inc. All Rights Reserved.

Figure 10. Anterior cervical triangle. Gilroy et al., Atlas of Anatomy. All rights reserved. © Thieme 2018, [www.thieme.com](http://www.thieme.com)

The incidence of ISB induced phrenic nerve block varies from 20-100%<sup>26</sup>. Irrespective of which ISB technique and LA that has been applied, this incidence has not been reported to be <20%<sup>26</sup>. Respiratory dysfunction is usually asymptomatic or short lived. However, Kaufman et al. at a tertiary referral center for peripheral nerve injury center covering the entire United States,

reported 14 patients who demonstrated permanent diaphragm paralysis after ISB<sup>27</sup>. The definite cause of phrenic nerve injury for each patient could not be established, but mechanical, LA toxic and ischemic origine were discussed. Complications were recorded after both single injection and following continuous administration of LA. The patients had various degrees of dyspnea. This may indicate that the real incidence of permanent nerve damage may be higher, because asymptomatic patients are less likely referred to specialist centers.

Several alternatives to the ISB have been proposed to avoid hemidiaphragmatic paresis/paralysis, yet many of them require further confirmatory trials. Lower volumes of LA<sup>21,23,28</sup> and the use of ultrasound has decreased the incidence of diaphragm paralysis after ISB, but cannot prevent it entirely<sup>26</sup>. Furthermore, additional interventions such as decreasing the LA concentration, digital compression cranial to the injection site and injection as far lateral as inside the scalenus medius muscle, have not prevented the effects of LA on the phrenic nerve<sup>26</sup>. In the last years some authors have proposed a C7 root block<sup>29</sup>, an alternative supraclavicular block limited to the distal upper extremity<sup>30</sup>, and an axillary-suprascapular block<sup>31</sup>.

In study II we applied SSNB to prevent lateral rotation of the humerus in patients undergoing dorsal hand surgery. Postblock chest radiographs documented that the combination of LSIB and SSNB did not cause phrenic nerve paralysis. Based on our anatomy studies and encouraging results from the previous study, we hypothesized that a combination of SCPB, SSNB, and LSIB would provide intraoperative anesthesia and postoperative analgesia for patients undergoing arthroscopic shoulder surgery.



## 6 Aims

### 6.1 Study I

The aim of the ultrasound-guided LSIB study was to estimate the MEV of ropivacaine 7.5 mg / ml sufficient for a successful block in 50% and 95% of the patients.

### 6.2 Study II

We hypothesized that the addition of SSNB to the LSIB would reduce supination and thereby improve upper limb positioning for dorsal hand surgery. Our primary outcome measure was the degree of supination (as assessed by wrist angulation) in patients 30 min after the LSIB, with and without an additional SSNB. Our secondary outcome measure was the surgeons' rating of the adequacy of intra-operative hand/forearm position.

### 6.3 Study III

We hypothesized that a combination of SCPB, SSNB, and LSIB would provide intraoperative anesthesia and postoperative analgesia for patients undergoing arthroscopic shoulder surgery. The primary aim was the proportion of patients who could be operated under light propofol sedation, but without the need for opioids or artificial airway. Secondary aims were patient satisfaction and surgeons' judgment of the operating conditions.

## 7 Methods study I

### 7.1 Ethical considerations

The study was in accordance with the Helsinki declaration, approved by the regional ethical committee of North Norway, and registered at Clinical Trials.gov (NCT01493986). Twenty-five patients scheduled for hand surgery gave written informed consent to participate in this prospective study.

The MEV for a successful block in 50% of the patients was determined by using the staircase up-and-down method<sup>32</sup>, which implicated that only 50% of the patients would experience a complete nerve block using a particular dose. All patients were given written information about the potential need for supplementary peripheral nerve blocks or GA. However, the ethical considerations were, that the benefits to future patients of knowing the MEV outweighed the potential discomfort and risk of complications to the individual study patient.

### 7.2 The lateral sagittal infraclavicular block

Several infraclavicular brachial plexus block methods have been published<sup>33,34</sup>. At the University Hospital of North Norway we practice the LSIB method. High success rate, negligible patient discomfort and a very low risk for pneumothorax have made this block popular among anesthetists<sup>35-37</sup>.

During the block procedure we used triple monitoring to reduce the risk of intraneural injection. Ultrasound allowed us to observe the relationship between needle and nerve in real time. Nerve

stimulator was applied using a current of 0.2 mA and 0.1 ms duration at 2 Hz. If a motor response was obtained, the needle was withdrawn in steps of 1 mm until the response disappeared. Thirdly, we assessed the resistance to injection manually, and did not inject if the resistance was increased.

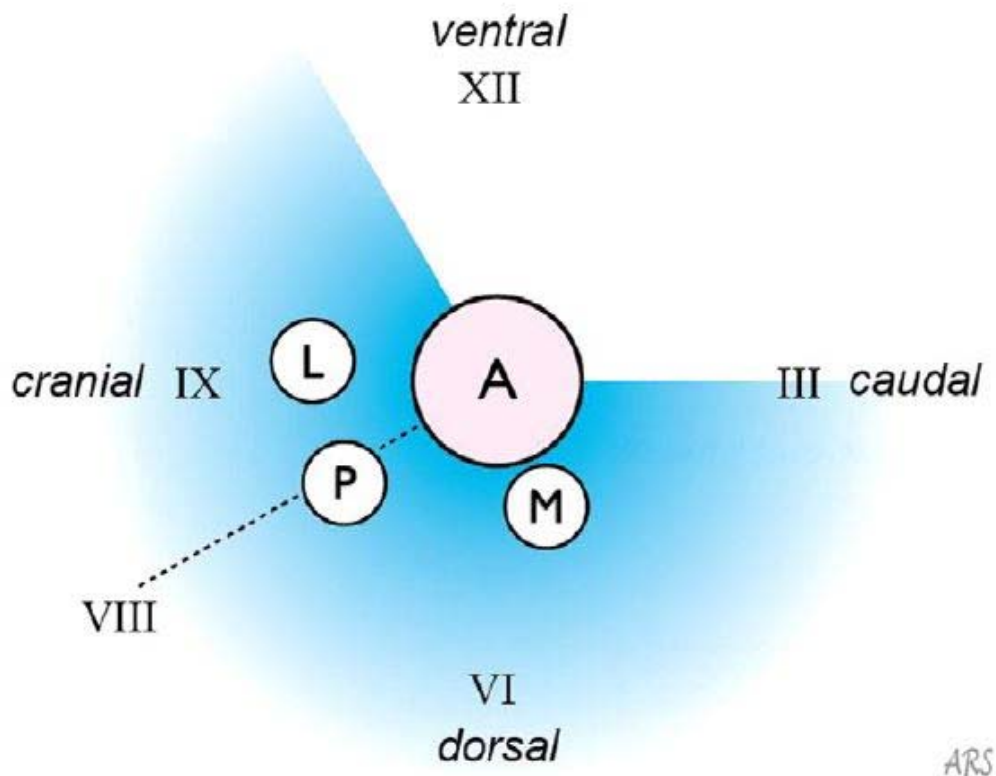


Figure 11. The periarterial sector. Schematic drawing in the parasagittal plane of the lateral sagittal infraclavicular block, showing the axillary artery (A) with clock face orientation (XII o'clock ventral), the cords and a blue-coloured periarterial sector. The sector extends from III to XI o'clock and radially 2 cm from the midaxis of the artery. It usually includes the lateral (L), posterior (P) and medial (M) cords, indicated in their average periarterial positions. The point on average closest to the cords is at VIII o'clock, immediately outside the arterial wall. The study protocol implied filling up the sector with LA. The drawing is made by Axel R. Sauter, based on data and a figure from a previous study<sup>38</sup>.

The needle insertion point was at the intersection between the lower edge of the clavicle and the medial surface of the coracoid process. Needle advancement was in the parasagittal plane, with continuous observation of the needle tip, using the in-plane technique. Considering the artery as a clock face with 12 o'clock ventral, the cords are normally found inside a periarterial sector from 3 to 11 o'clock and within 2 cm from the midaxis of the axillary artery. The aim for the injections was an even distribution of LA inside this sector only. We did not aim to selectively inject towards structures assumed to be cords, even if they were located outside the sector. The first deposit was, as a rule, at 8 o'clock and close to the artery. Subsequent injections were most often made at 6-7 o'clock and 9 o'clock, and usually also at a fourth position, depending on the observed spread of LA.

### 7.3 The up-and-down staircase method

The up-and-down method is commonly used to determine minimum effective volume in 50% of the patients (MEV<sub>50</sub>) for a particular LA drug<sup>29,33,39</sup> for upper limb surgery. By this method, the first patient will receive a LA volume which is believed to provide sufficient anesthesia. LA volume for the next patient is determined by the block result of the previous patient. LA volume is decreased for the subsequent patient if the block was successful and increased if it was as a failure. Up-and-down method experiments are relatively simple to perform and can be performed with a relatively small sample size.

We used ropivacaine 7.5 mg/ml in our study. The first patient received 30 ml, which we expected to be a sufficient anesthetic volume. Successful block was followed by a volume reduction of 2.5 ml

for the next patient, whereas volume was increased by 2.5 ml in case of block failure. However, maximum LA volume was limited to 40 ml due to the risk of LA toxicity.

The staircase up-and-down method for large samples was used to estimate the MEV<sub>50</sub> and its 95% confidence interval (95% CI)<sup>32</sup>. For this plot, we also required a priori a minimum of five negative-positive up-and down deflections<sup>29,40</sup>. To estimate the MEV in 95% of patients (MEV<sub>95</sub>), our secondary outcome measure, logistic regression and probit transformation were used, applying the SAS statistical software package (SAS®, V9.2, SAS Institute Inc., Cary, NC, USA). The binary response in the logistic regression model was failed block (yes/no) with LA volume as the independent variable.

#### 7.4 Block success assessment

An observer blinded for the block procedure and the injected volume assessed the sensory status of limb to be operated, before the block (baseline) and every fifth minute for 30 minutes after the block.

For sensory testing ice cubes were applied to the skin at pre-marked points in the areas of the radial, median, ulnar, musculocutaneous and medial antebrachial cutaneous nerves.

Test points were localized as follows:

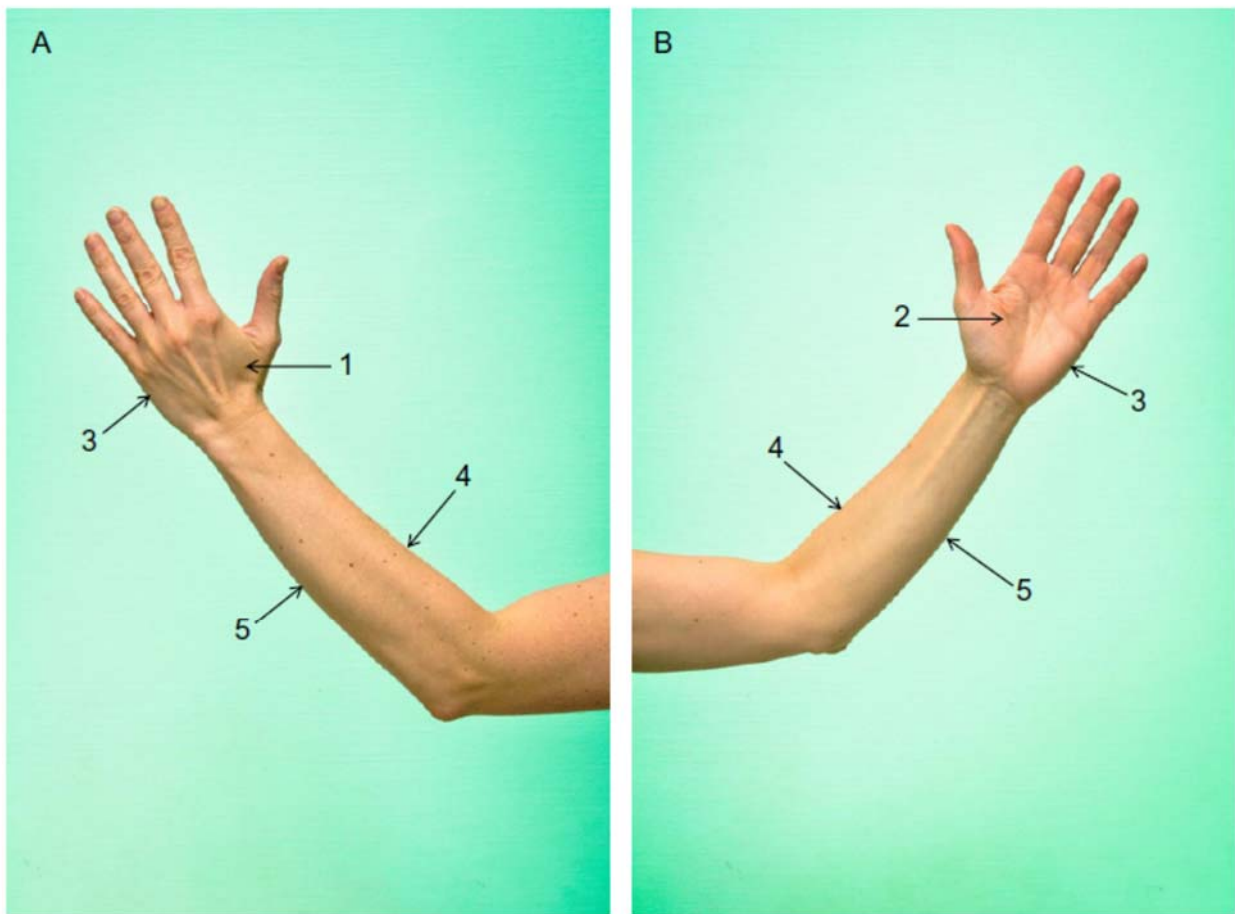


Figure 12: Sensory testing points. Photos of the hand and forearm, (A) from the dorsal (extensor) and B from the volar (flexor) surface. The arrows indicate the points for testing the sensory state innervation areas of five terminal nerves: 1: Radial nerve, 2: Median nerve, 3: Ulnar nerve, 4: Musculocutaneous nerve, 5: Medial cutaneous antebrachial nerve

A four-point sensory scale was applied<sup>41</sup>:

0 = normal sensation to cold

1 = hypoalgesia, that means the patient feels cold, but less than on the contralateral side

2 = analgesia, which means the patient feels touch, but not cold

3 = anesthesia, feeling neither cold nor touch

The block was defined as successful if all five nerves had a score of 2 or 3 within 30 minutes after completed LA injection.

All patients were followed up by a telephone interview on the first postoperative day and asked about the block length, average and maximum pain scores after block recovery (using numeric rating scale, 0-10) and intake of analgesics. The surgical follow up was one week after open fasciotomy for Duputren's contracture and five weeks after excision of the trapezium bone for carpometacarpal arthrosis. The patients were asked for signs of peripheral nerve injuries related to LSIB.

## 8 Methods study II

Clinical experience revealed that a successful LSIB often results in supination of the hand, making access to dorsal hand surgery awkward. We wanted to investigate the reasons for hand supination following LSIB and search for an alternative anesthetic method which could solve this clinical challenge.

### 8.1 Enrolment

The study was approved by the regional ethical committee of North Norway. The trial was performed at the University Hospital of North Norway in Tromsø from January to April 2014 and in accordance with the Helsinki Declaration. The study was registered at [www.clinicaltrials.gov](http://www.clinicaltrials.gov) (NCT02035774).

We screened 31 patients. Thirty of them were recruited for the study, after written informed consent, recruited 30 to this study. One of the screened patients was not able to pronate the hand  $\leq 15^\circ$ . The remaining participants were randomly allocated on a 1:1 basis to one of the two groups using computer-generated patient numbers in sealed envelopes. Patients in the suprascapular group received a SSNB with 4 ml ropivacaine 5 mg/ml while the control group had a sham nerve block with 4 ml saline 9 mg/ml. A study nurse opened the sealed envelope and provided either ropivacaine or saline in an unlabeled syringe for the SSNB procedure. Thus, the patient, block performer, assistant and assessor were all blinded to group allocation.

Only patients with successful blocks were included in the analysis for primary and secondary outcome measures.



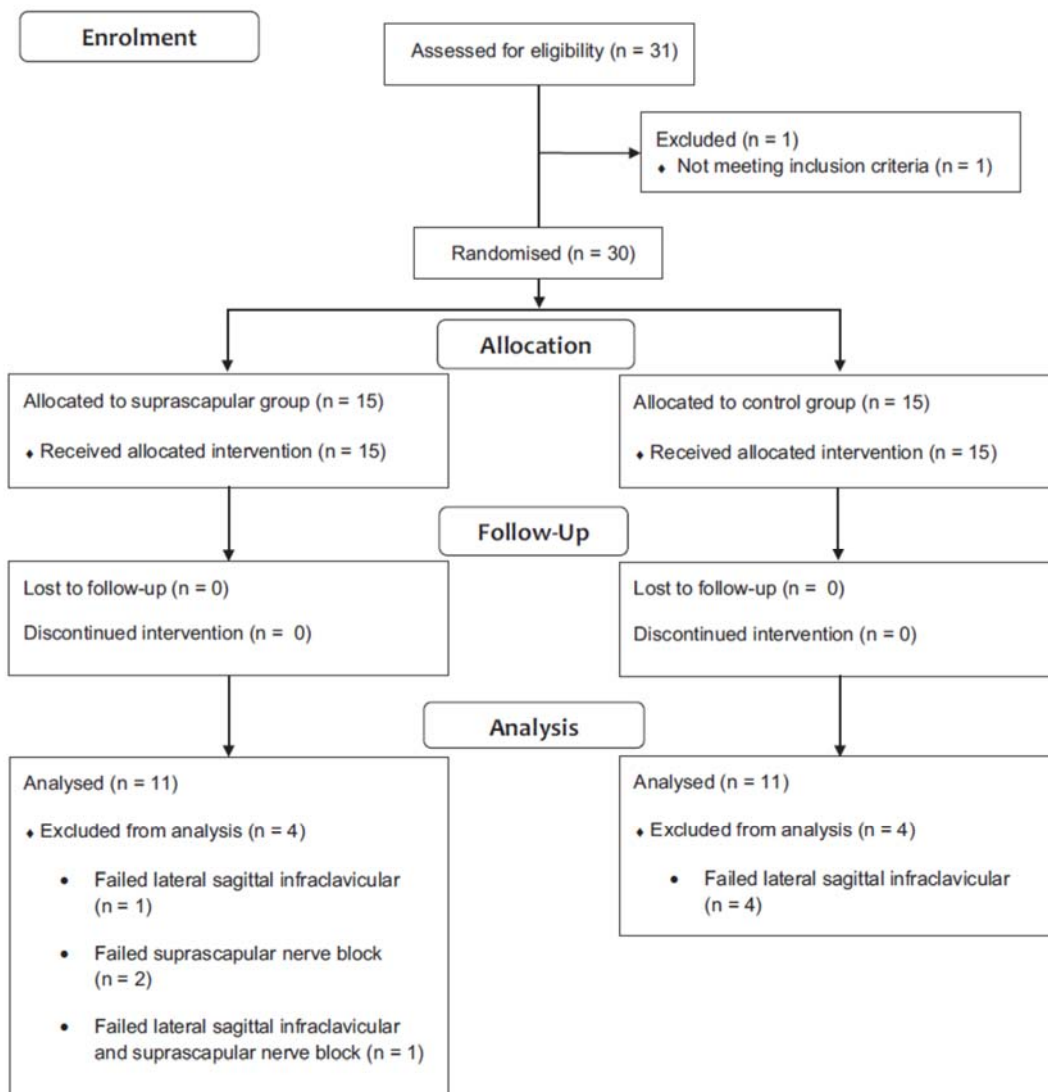


Figure 13. CONSORT flow diagram.

## 8.2 The suprascapular nerve block

Siegenthaler et al. investigated the ultrasound visibility of the SSN both in the classical posterior approach and in a new anterior approach (the supraclavicular approach)<sup>42</sup>. They were only able to identify the SSN in the supraspinatous fossa in 36% of the cases, while SSN was visible in 81% of the volunteers using the supraclavicular approach.

With small modifications, we performed the SSNB as described previously by Siegenthaler et al<sup>43</sup>. The patient was in a semi-lateral position with slightly elevated upper body. The linear ultrasound transducer was initially positioned immediately cranial and parallel to the middle of the clavicle to provide a cross-sectional view of the subclavian artery and the brachial plexus. Maintaining a short-axis view of the brachial plexus, the transducer was moved cranially to identify the superior trunk. While slowly returning the transducer towards the initial position, we could observe the SSN diverging from its trunk. The SSN was identified in the most craniolateral part of the brachial plexus cluster area. Tracing it laterally, we slowly slid the transducer to an oblique sagittal position, in the posterior cervical triangle. Using an in-plane technique, the block needle tip was positioned just caudal or lateral to the SSN. Correct identification of the nerve, caudal to the omohyoid muscle, was confirmed by nerve stimulation. We aimed to surround the nerve with 4 ml of the study fluid, if necessary by repositioning the needle.

The needle tip position relative to the SSN was monitored by ultrasound, nerve stimulation and measurement of the injection pressure. Motor response at a current of < 0.5 mA, 0.1 ms or injection pressure  $\geq$  103 kPa (15 psi) necessitated repositioning of the needle.

### 8.3 Block success assessment

The assessor was blinded to group allocation. He recorded the sensory-motor status of the upper limb and wrist angle before the blocks (baseline), 15 min, 30 min and 60 min after the last block (LSIB), and then before start of surgery.

We performed sensory testing of the axillary nerve and of all five nerves distal to the elbow, using ice (touching the skin). A four-divided sensory scale was used:

3 = normal sensation to cold

2 = reduced sensation to cold (hypoalgesia)

1 = no sensation to cold , but feels touch (analgesia)

0 = no sensation to cold or touch (anesthesia)

Note that the scale in the present study differs from the scale used in study 1, by simply being reversed.

Muscle strength was assessed using the following modified five-point scale<sup>44</sup>:

- |    |  |
|----|--|
| 5  | Normal power   |
| 4+ | Active movement against gravity and resistance (> 50% of normal power) |
| 4- | Active movement against gravity and resistance (< 50% of normal power) |
| 3  | Active movement against gravity  |
| 2  | Active movement with gravity eliminated                                |
| 1  | Flicker or trace contraction   |
| 0  | No contraction   |

SSN power was tested by lateral rotation of the humerus against manual resistance, while the arm was adducted and the elbow flexed at 90°. The other motor nerves tested were the accessory, axillary, musculocutaneous, radial, median and ulnar. The accessory nerve was tested by elevation of the shoulders (trapezius muscle), the axillary nerve by elevation of the arm in the sagittal plane (deltoid muscle, anterior and lateral parts), the musculocutaneous nerve by flexion the elbow ( biceps brachii muscle) while the forearm was supinated, radial nerve by wrist extension and by extension of the elbow (triceps brachii muscle), the median nerve by flexion of the distal phalanx of the index finger (flexor digitorum profundus muscle) and the ulnar nerve by abduction of the fifth finger (abductor digiti minimi muscle).

Thirty minutes after the block procedures, the SSNB was judged as successful if the motor score was  $\leq 2$  and LSIB successful if the sensory score for each of the five nerves distal to the elbow was 0 or 1<sup>41,45</sup>.

To measure the wrist angle, an electronic water level apparatus was used. It was positioned dorsally on the wrist, between the styloid processes of the radius and the ulna. During measurement, the patient was supine on a horizontal table while having the fully extended upper limb 75° abducted. Prior to the recording, we asked the patient to pronate as much as possible. The wrist angle was the angle between the table plane (at 0°) and the plane contacting the dorsal aspect of the wrist at the interstyloid level. The angle recorded was the mean of the three repeated measurements.

The surgeons assessed the intra-operative position of the hand/forearm as either 'good' or 'poor' without knowing the group allocation of the patients.

In the follow-up 1 – 2 weeks after the operation, the patients were asked about peripheral nerve injuries (numbness, abnormal sensations, tingling), abnormal pain and reduced strength in the operated upper limb. The surgeon also tested the muscle strength for the suprascapular and

accessory nerve. In addition, the patients were asked if they had noticed a hematoma or any other problem at the insertion sites.

#### 8.4 Statistics

The study was powered to show a difference in wrist angulation 30 min after completion of the two nerve blocks. Clinical experience indicated that surgeons would not be satisfied with a wrist angle greater than 20°. We assumed the suprascapular group would achieve a wrist angle of  $\leq 20^\circ$  and performed a power calculation anticipating a minimal angle difference of 20° between the suprascapular and the control group using a standard deviation equal to 5° and 10° in the groups, respectively. The study only needed five patients in each group when using a significance level of 5% and a power of 80%. However, the number of participants was increased to 30 patients to ensure sufficient power to detect a smaller group difference and to account for dropouts. With 11 patients in each group, the study had 80% power to detect a difference.

Ordinary linear regression models were used to assess changes in wrist angulation from baseline to follow-up measurement at 30 min. Linear mixed models were used to test for differences in wrist angulation from baseline over four repeated measures (15 min, 30 min, 60 min and before surgery in theatre). An unstructured covariance matrix was specified to control for dependencies between repeated observations. In separate models, two-way interactions were assessed by including cross-product terms between group and indicator variables of time. In all regression models with wrist angulation as the dependent variable, we adjusted for the baseline value of angle. Residual analyses verified the model assumptions. The Mann–Whitney U-test was used to assess differences in lateral rotation force of the humerus at each time point and the surgeons' evaluation of the hand position was analysed using the Fischer's exact test. In separate analyses, we used the intention-to-treat

principle and assessed group differences for all 30 patients who were randomly allocated, without exclusion of patients with unsuccessful suprascapular and/or lateral sagittal infraclavicular brachial plexus blocks. Statistical analyses were performed using the Statistical Package for Social Sciences (SPSS) program version 21.0 for Windows.

## 9 Methods study III

In study II we learned that the combination of LSIB and SSNB may provide adequate anesthesia to all relevant nerves to the shoulder joint. The suggestion of using a combined infraclavicular block and a selective SSNB for shoulder anesthesia, had been put forward by Martinez et al in 2003<sup>46</sup>. They combined infraclavicular plexus block with SSNB for humeral head surgery in a patient with respiratory failure. In study III, we hypothesized that our new block combination, when supplemented by a SCPB, would provide a good alternative to the ISB.

### 9.1 Ethical considerations

The study was approved by the Institutional Board at the University Hospital of North Norway (registration number 0472) and registered at Clinical Trials.gov (NCT02809144). The trial was performed at the University Hospital of North Norway (Tromsø and Narvik) from April to November 2016, in accordance with the Helsinki Declaration. Written informed consent was obtained from 20 patients scheduled for arthroscopic shoulder surgery.

The need of three injections (LSIB, SSNB, SCPB), change of patient's body position, and change of needle type during the procedure, make our triple block method more time consuming compared to the ISB<sup>31</sup> and the patients may experience more discomfort than during the single block procedure of ISB. However, ISB carries the risk of phrenic nerve block, even when using a low volume of LA and when injecting it at different interscalene positions<sup>3,21,23,25,28,47-51</sup>. Moreover, low volume ISB is unlikely to block the supraclavicular nerves (which innervate the skin of the "cape region" overlying the shoulder joint). As for the combined block of LSIB and SSNB, low volume ISB would therefore demand a supplementary SCPB, if not relying on preoperative supplementary LA by the surgeon. Accordingly, we proposed that our new block combination is a good alternative to

ISB in patients with impaired respiratory function and/or obesity. Therefore, we considered the benefits of the study to outweigh any patient discomfort.

## 9.2 The superficial cervical plexus block

Performance of the LSIB and the SSNB were performed as described in study I and II, respectively.

In study III we applied the same volume and the same concentrations of ropivacaine.

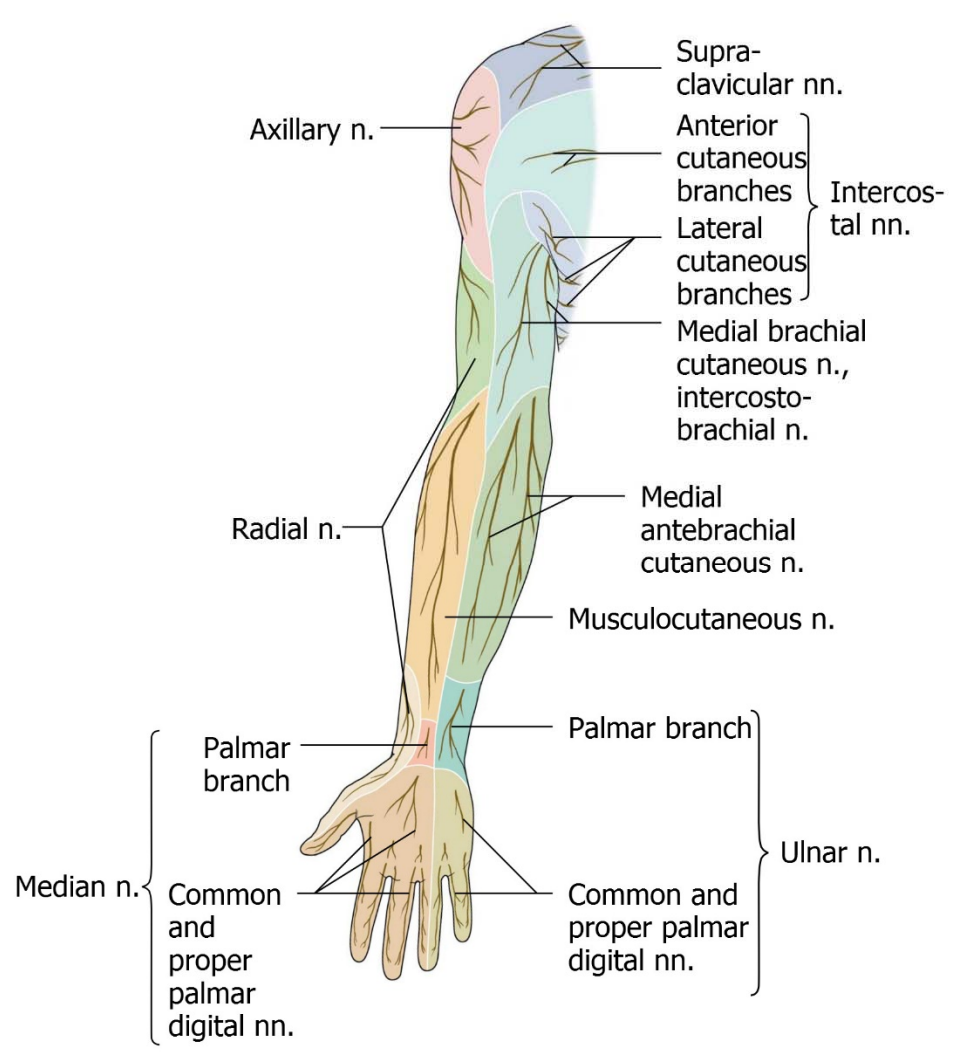
To reduce the risk of intraneural needle tip position during the SCPB, the relationship between needle and nerve was carefully observed by ultrasound. Moreover, a sensory nerve stimulator response by a current  $\leq 0.3$  mA, 0.1 ms and 2 Hz or an injection pressure  $\geq 103$  kPa (15 psi) necessitated a small retraction of the needle.

We used a slight modification of the method first described by Tran et al<sup>52</sup>. Before the insertion of the block needle, the skin was infiltrated with 1–2 ml lidocaine 10 mg/ml. The probe was placed axially, just below the midpoint of the sternocleidomastoid muscle, to visualize the intermuscular plane between the sternocleidomastoid and the scalene muscles.

The needle was slowly advanced from posterolateral to anteromedial in this potential space, using the in-plane technique. The patient was instructed to signal paresthesia toward the clavicle or shoulder, while receiving a current of 0.3–0.8 mA, 0.1 ms, 2 Hz. Five ml ropivacaine 5 mg/ml was injected in the described interfascial space, while trying to avoid distribution medial to the interscalene groove. The supraclavicular nerves can often be visualized by ultrasound. We did not perform a more comprehensive scan due to the fact that our technique relied solely on injection of LA agents in the intermuscular plane. Block success assessment



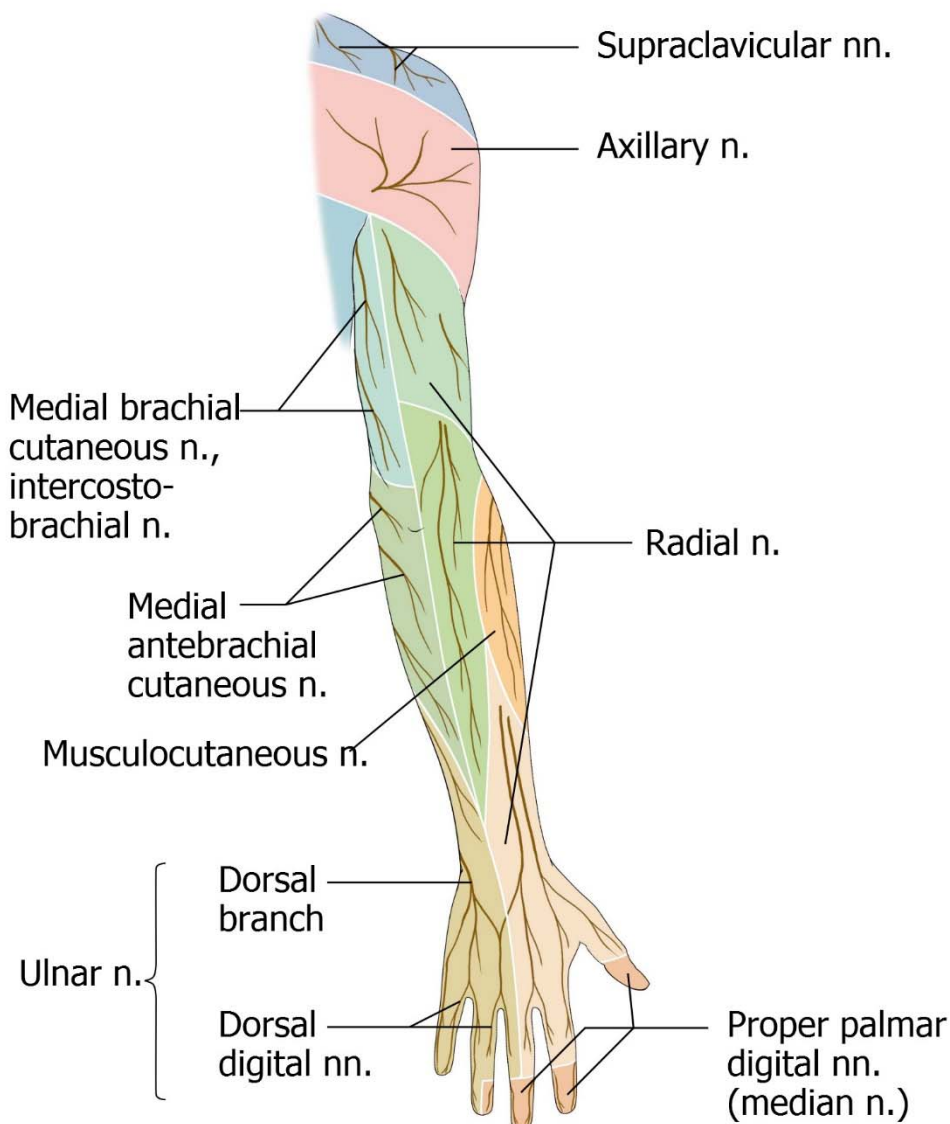
Sensorimotor status of the upper limb and the cervical area was assessed at baseline and 15 and 30 minutes after completion of the blocks.



Anatomy: An Essential Textbook, Fig. 13.20 A, Illustrator: Karl Wesker, Markus Voll, ©2018 Thieme Medical Publishers, Inc. All Rights Reserved.

Figure 14. Cutaneous innervation of the upper limb, frontal view. Gilroy et al., Atlas of Anatomy.

All rights reserved. © Thieme 2018, www.thieme.com



Anatomy: An Essential Textbook, 2nd Ed., Fig. 13.21 B, Illustrator: Karl Wesker, Markus Voll,  
©2018 Thieme Medical Publishers, Inc. All Rights Reserved.

Figure 15. Cutaneous innervation of the upper limb, dorsal view. Gilroy et al., Atlas of Anatomy.

All rights reserved. © Thieme 2018, [www.thieme.com](http://www.thieme.com)

We performed sensory testing by applying an ice cube on pre-marked points in the areas of the supraclavicular, intercostobrachial, axillary, medial brachial cutaneous, musculocutaneous, medial

antebrachial cutaneous, radial, median and ulnar nerves. Supraclavicular test points were at the soft spot and at the upper border of the clavicle in the midclavicular line. The soft spot is the posterior portal used for shoulder arthroscopy. It is formed by the interval between the infraspinatus and teres minor muscles, approximately 2 cm caudal and 1 cm medial to the postero-lateral tip of the acromion. For sensory scores we used the same 4-point scale as in paper II.

Muscle power was assessed using the modified five-point scale as described for study II. SSNB was tested by the force for lateral rotation of the humerus against manual resistance, while the arm was adducted and the elbow flexed at 90°. The axillary nerve was tested by elevation of the extended upper limb in the sagittal plan. The other nerves tested by muscle power were the subscapular, musculo-cutaneous, radial, median and ulnar nerves<sup>53</sup>.

Block success was assessed at 30 minutes after withdrawal of the needle upon the last of the three blocks. The SCPB was judged successful if the sensory score at both test points was 0 or 1. SSNB was successful if the motor score was  $\leq 2$  and LSIB if the axillary sensory score was 0 or 1.

All patients were interviewed in the recovery room and by phone approximately 24 hours after the surgery was completed. In the recovery room, post-operative nausea and vomiting, pain at rest (numeric rate scale 1 – 10), medication, signs of Horner's syndrome, hoarseness, dyspnea or dysphagia were recorded. The same questions were repeated on day one. Additionally, we asked about time to pain debut, average and maximum pain scores at rest (numerical rating scale 1 -10) and patients' total intake of analgesics. The surgeons assessed the operative conditions in the recovery room, immediately after surgery.

## 10 Results

### 10.1 Study I

The patients received ropivacaine 7.5 mg/ml volumes in the range of 12.5-30 ml. The MEVs in 50% and 95% of the patients were 19 ml [95% confidence interval (CI), 14–27] and 31 ml (95% CI, 18–45), respectively.

As foreseen by the study design, 10 out of 25 blocks were assessed as failures according to our definition. Two patients needed supplementary peripheral nerve blocks before surgery. None of the 25 patients received deep sedation or GA during surgery.

Eight patients reported paresthesia, but none of them were found to have nerve dysfunction at the follow up consultations. We observed two vascular punctures (one from a skin vessel and another from the axillary vein). There were no signs of local anesthesia systemic toxicity (LAST) or pneumothorax.

All patients were contacted by phone after surgery. Three patients did not show up at the surgical follow up consultation five weeks after surgery. None of the patients who met at the follow up clinic suffered from any nerve injury.

### 10.2 Study II

There was no significant difference regarding gender, body mass index or side of surgery (right/left hand). The LSIB was successfully blocked in 24 out of 30 patients. The SSN was sonographically identified in all patients using ultrasound and confirmed by nerve stimulation. The nerve was

successfully blocked in 12 out of 15 patients in the suprascapular group and in 2 out of 15 patients in the control group.

When only considering the patients with successful nerve blocks, we found a significantly lower mean (SD) wrist angulation at 30 min in the suprascapular group compared with the control group, when adjusted for baseline (33 (27) vs. 61 (44) degrees;  $p = 0.018$ ). Mean wrist angulation adjusted for baseline was also lower in the suprascapular group over all repeated time points ( $p = 0.014$ ). The difference between the two groups did not vary over time as the test of interaction between time and group was not significant ( $p = 0.23$ ).

The surgeons' assessment of the hand/forearm position was rated as good for all 11 patients in the suprascapular group. This was in contrast to the control group, where only 6 of 11 achieved that score ( $p = 0.04$ ).

Interestingly, the axillary nerve was well blocked in all 30 patients.

No patient demonstrated signs of LAST. In the suprascapular group, there was one vascular puncture of the axillary artery and transient paresthesia in two other patients. None of the patients complained of respiratory distress. Chest radiograph did not demonstrate pneumothorax or signs of phrenic nerve palsy in any patient. Three patients in the control group demonstrated temporary Horner's syndrome. The accessory nerve was not affected by the SSNB.

Follow-up by the surgeons revealed no patients with sensorimotor deficit or soft tissue injury.

### 10.3 Study III

Nineteen out of 20 patients (95%, CI 85-100) underwent arthroscopic shoulder surgery with light propofol sedation but without any need for opioids or artificial airway. Propofol dose given was 1.4 (0.4-2.6[0.0-3.4]), median (IQR [range] mg/kg/t. One patient had a successful block, but felt uneasy

in the beach chair position. After starting light propofol sedation, she became restless and therefore received GA. Two patients reported slight discomfort intraoperatively, pain score 1 - 2 (numeric rating scale 0-10), located at the posterior portal (soft spot). Both were offered analgesics, but refused.

Four patients did not fulfil the block success criteria for SCPB, SSNB and/or LSIB at 30 minutes, which resulted in a block success rate of 80%. One patient failed the midclavicular SCPB-test at 30 minutes, but met the success criteria 10 minutes later. SSNB failed in three patients. In two of these patients the SSN effect was successful at 45 and 90 minutes, respectively, after the last block. The last patient retained SSN mediated muscle power score 4- up to the time of surgery. In spite of this suboptimal score, we decided to proceed to surgery. The precondition was, by the slightest intraoperative pain, to convert to GA. However, the patient did not experience pain during surgery and received only propofol according to the protocol.

We observed no signs of LAST. There was one vascular puncture: LSIB, and 4 patients reported paresthesia: SSNB (n = 2), SCPB (n = 1), and LSIB (n = 1).

In the post-anesthesia care unit only one patient reported a pain score of 2 (numeric rating scale 0-10). Remarkably, the other patients were pain free. None of the patients suffered from nausea/vomiting, dyspnea, hoarseness or dysphagia. One patient demonstrated temporary Horner's syndrome.

The surgeons were satisfied with the working conditions in 19 of 20 patients.

One patient was excluded from postoperative day 2 data analyses because of protocol violation (he was given dexamethasone intravenously during the operation).

On the first postoperative day, no patient reported nausea/vomiting, dysphagia, dyspnea or hoarseness. Time to pain onset was 12.5 (11.7 – 14.8 [7.6 – 15.6]), median (IQR [range]) hours.

Average pain score at rest was 0 (0-2.3 [0 - 6]), median (IQR [range]) and maximum pain score was 5 (3.5-8.5 [0 - 10]), median (IQR [range]). During the first postoperative 24 hours the analgesic consumption was 40 (30 – 60 [0 - 100]), median (IQR [range]), mg oral morphine equivalents.

## 11 Discussion study I

### 11.1 Validity and limitations

The MEV data found in this study are only valid for ropivacaine 7.5 mg/ml and when injected as described in the method section of study I. Any other LA and/or block method is likely to result in different results. The MEV<sub>95</sub> of 31 ml fit well with our clinical experience and has become the standard dose for the LSIB at the University Hospital of North Norway.

Regarding other MEV studies of infraclavicular blocks, Tran et al. calculated MEV<sub>90</sub> for the LSIB to be 35 ml (95% CI, 30-37.5 ml) using lidocaine 15 mg/ml with epinephrine 5 µg/ml<sup>33</sup>. However, appropriate comparison between these two studies was hampered by major methodological differences. Tran et al. injected LA as a single deposit, whereas our study allowed more than one deposit. This creates a double bubble sign as described by the authors. The sign consists superiorly of the axillary artery (in short axis) superimposed on an inferior bubble created by the LA injection. If necessary, the needle was repositioned to obtain the double bubble. The LA bubble then contacts or is close to only a small dorsal segment of the artery<sup>33</sup>. This contrasts our method where LA initially covers 2/3 of the arterial circumference, in a sector usually including the cords<sup>38</sup>. This method was based on previous work by Klaastad et al. and Sauter et al.<sup>38,41,54</sup>, in which they documented the rationale for injection of LA at 8 o'clock with the aim to cover the periarterial 3-11 o'clock sector (figure 11). Furthermore, in the study by Tran et al., block success definition and dose-finding methodology (biased coin design up-and-down sequential method) were also different from our study<sup>33</sup>.



The MEV for the infraclavicular costoclavicular block was recently calculated. Using lidocaine 15 mg/ml with epinephrine 5 µg/ml the estimated MEV<sub>90</sub> was found to be 34.0 mL (95% CI, 33.4-34.4 mL)<sup>55</sup>, which is in line with the findings by Tran et al<sup>33</sup>. The similarity may surprise since the cords are tightly clustered at the medial target of the costoclavicular method (short LA distribution distances), while separated from one another at the lateral target of the “bubble” method and the LSIB (longer LA distribution distances).

Implementation of ultrasound-guided peripheral nerve blocks has enabled clinicians to be more accurate and precise in the application of LA. This has supported a trend towards the use of lower volumes and concentrations of LA, which implies a need to redefine MEVs for the most popular LAs. Moreover, Ultrasound has also enabled clinicians to perform selective injections towards or around the individual brachial plexus cords<sup>56</sup>. Accordingly, alternative injection techniques may decrease MEV<sub>95</sub> even further for ropivacaine 7.5 mg/ml, yet this hypothesis remains to be studied.

Another limitation of this study is the inclusion criteria. Although our patients were all ASA class I or II, their age and BMI ranged considerably. Saric et al. have showed that elderly patients (> 65 years) needed less LA compared to younger control patients receiving a supraclavicular block<sup>57</sup>. We studied relatively healthy individuals with a mean age (SD) of 57.6 (7.7) years. MEV<sub>95</sub> of elderly patients with or without comorbidities should be included in future protocols, because they represents an ever increasing group of patients.

## 11.2 Minimum effective volume methods

We decided to apply the staircase up-and-down method for this study<sup>32</sup>. To assess the 50th quantile, an initial dose/volume/concentration is selected. The selected value can be chosen because it represents the lowest value expected to result in a successful block (minimum dose/volume/concentration) or the one closest to the median dose/volume/concentration. Alternatively, it can be selected in an arbitrary fashion. Subsequent doses, volumes, or concentrations are determined based on the response of the previous patient<sup>58</sup>. This allows us to determine MEV<sub>50</sub> and to estimate MEV<sub>95</sub> by applying logistic regression and probit transformation. The staircase up-and-down method returns a relative wide confidence interval indicating the uncertainty about the clinical true MEV<sub>95</sub>. This is partly due to a small sample size, but other factors may have contributed as well<sup>59</sup>.

The LSIB method is based on magnetic resonance imaging of 20 healthy young volunteers, where the periarterial sector was first described<sup>38</sup>. Hence, any anatomical variation may alter efficiency and effectiveness of 31 ml ropivacaine 7.5 mg/ml. Patients were carefully selected according to inclusion and exclusion criteria, so variation due to mixed study population should not represent a major bias.

Other dose-finding methods could have been applied. A comprehensive review by Saranteas et al. outlines other potentially useful approaches<sup>58</sup>. They argue that one risk in the up-and-down design lies in a poor selection of the initial dose, which will bias the outcome. Another main weakness of this design is that by targeting MEV<sub>50</sub> the accurate estimation of higher quantiles far from the midpoint will cause a significant bias when estimating MEV<sub>95</sub>. We chose to start with 30 ml, which was thought to be close to the clinical relevant effective volume for this particular block. MEV<sub>50</sub>

was found to be 19 ml and MEV<sub>95</sub> estimated to 31 ml with a rather wide confidence interval of 18-45 ml.

The biased coin design and the continual reassessment method are two other methods discussed by Seranteas et al<sup>58</sup>. Both methods have a close mean square error and confer a better precision of the confidence interval. The biased coin design is a randomized variant of the up-and-down method, which does not require symmetry of the tolerance distribution.

The continual reassessment method integrates known information including patient outcome, which in combination with patient data, defines the next dose given to the subsequent patient. This method reduces the number of participants needed. An advantage of the continual reassessment method is the reduction in administration of ineffective volumes and thus a reduced number of failed blocks. The risk of achieving toxic levels of LA is a potential danger of this method.

Combining the information from the current dataset underpins our clinical practice. A smaller CI would probably have been achieved if an alternative MEV method was chosen. However, 31 ml of ropivacaine 7.5 mg/ml has become a recommended volume when performing LSIB at the University Hospital of North Norway.

## 12 Discussion study II

### 12.1 Optimal hand position for dorsal hand surgery

When considering only those patients with successful nerve blocks, our study confirmed the observation from our surgeons that LSIB is likely to cause supination, as demonstrated by the increase in wrist angulation (supination) in the control group. The novel combination of a SSNB and LSIB significantly reduced the amount of supination allowing a improved intra-operative hand position.

Wrist angle range was quite wide in both groups. In an attempt to explain this variation, it was necessary to review some functional shoulder anatomy. The two major muscular forces that determine the position of the scapula in the transverse plane are serratus anterior (innervated by the long thoracic nerve) and pectoralis minor (innervated by lateral and medial pectoral nerves). These muscles pull the scapula anteriorly along the rib cage, whereas trapezius (innervated by the accessory nerve) and rhomboid major and minor (innervated by the dorsal scapular nerve) pull it posteromedially. LSIB target the cords of the brachial plexus and is likely to have an effect on the lateral and medial pectoral nerves, as they originate from these structures. In some patients, the LA may theoretically also reach the long thoracic nerve, but is unlikely to reach the more distant dorsal scapular and accessory nerves. These effects could result in posteromedial displacement of the scapula, which is associated with lateral orientation of the glenoid cavity and lateral rotation of the humerus and thus supination of the forearm and hand when the elbow is extended. This might explain why some of the patients in the suprascapular group also developed a large degree of supination.

Thirty minutes after the nerve blocks, 7 of 11 patients in the suprascapular group had wrist angles above 20°. However, all of them obtained a ‘good’ rating by the surgeons for their intra-operative hand/forearm position. This can be explained by the fact that the surgeons’ assessment of hand position was undertaken sometime after performance of the nerve blocks (median 2.3 hrs). By that time, wrist angulation had improved and only three patients had angles above 20°. Moreover, all 11 patients became paralytic for lateral rotation of the humerus. When the surgeons pronated the hands of these patients, we assume they sensed no or minimal muscular resistance. Hence, we believe that this has probably facilitated an improved hand position and favored a positive score from the surgeons.

## 12.2 Suprascapular nerve block (SSNB) - the new approach

The classic SSNB been performed via a posterior approach targeting the nerve close to the suprascapular notch or within the supraspinatous fossa. In 2012 Siegenthaler et al. presented an alternative method with an anterior access<sup>42</sup>. It was based on ultrasound studies of volunteers (without using needles) and cadaver dissections with needle insertions to assess the precision of their new approach. In study II we chose the Siegenthaler method, primarily because it offered better sonographic visualization of the nerve than the classic method. A case report with favorable use of the new method was published by Hackworth et al 2013<sup>60</sup> and followed by Rothe et al. who performed a study on volunteers without subsequent surgery<sup>61</sup>. Their LA dose was 1 ml lidocaine 20 mg/ml and the blocks were successful in 8 of 11 attempted cases. To our knowledge, we were the first to investigate Siegenthaler’s block in a clinical study of elective surgical patients.

The LA dose was semi-arbitrarily chosen as 4 ml ropivacaine 5 mg/ml. Nevertheless, 3 out of 15 patients did not meet the success criteria. This could be explained by a rather strict success criterion. The SSNB was judged as successful only if the motor score was  $\leq 2$  after 30 min. This is a very demanding criterion that has retrospectively been challenged by ourselves<sup>53</sup> and others<sup>31</sup>. The MEV<sub>95</sub> for the SSNB is not known and should be determined in order to define the most appropriate dose. In our study SSN was completely surrounded by LA in all patients and should therefore be successfully anesthetized. Of interest in this context is the observation that the SSN was, in many of the study patients, embraced by a hyperechoic 1 to 2 mm thick ring. We believe this could represent dense perineural connective tissue, which may have impeded LA penetration to the nerve. Unfortunately, we did not systematically record the presence of this ring in all patients. We can therefore not make any firm conclusion on the relation between perineural connective tissue and effects of LA.

### 12.3 The block combination and the phrenic nerve

The SSNB could potentially affect the phrenic nerve by medial or cranial spread of LA. A chest radiograph was therefore taken as soon as possible after the block measurements at 60 min. Although this investigation delayed start of surgery, we found it both necessary and useful to document diaphragm function in both groups. All chest radiographs were assessed by a radiology consultant who was blinded for the randomization code. No signs of asymmetry of the diaphragm was detected in any of the 30 patients, which made any phrenic nerve involvement unlikely. Today we would probably use US to measure diaphragm excursion for this purpose<sup>62</sup>.

We chose the anterior supraclavicular approach to the SSN in both study II and study III.

Relevant for anterior SSNB is the position of SSN lateral to the supraclavicular clusters of the brachial plexus. The phrenic nerve is located on the anterior surface of the scalenus anterior muscle. Both of these structures are medial to the mentioned clusters, and not far from the injection site of SSNB. In study II ultrasound-guided anterior SSNB and LSIB was administered in 15 patients in the intervention group, while 15 patients in the control group received LSIB and a sham SSNB. In all 30 patients we measured the distance from SSN (medial aspect) to the brachial plexus (lateral aspect). Median distance was measured as 6.5 mm (range 2 – 17 mm), which again reminded us about the potential for LA spread to the phrenic nerve when performing this block.

For the SSNB we slowly injected 4 ml ropivacaine 5 mg/ml and aimed to get a circumferential LA distribution around the nerve and avoiding spillover to the brachial plexus.

Regrettably, both blocks were administrated before sensory-motor testing was performed.

Therefore, we could not determine if SSNB had a true selective effect on SSN, without effect on the other brachial plexus nerves.

Rothe et al. did find that the anterior approach for SSNB also had an effect on other brachial plexus nerves, where one of 11 volunteers temporarily experienced an effect on the musculocutaneous and radial nerves<sup>61</sup>. Whether LA also reached the phrenic nerve (by medial or cranial spread), could not be determined since the authors did not investigate diaphragmatic motility by ultrasound or chest x-rays.

For ultrasound-guided LSIB we administered 31 ml ropivacaine 7.5 mg/ml. As described above all 30 patients had normal chest radiography approximately 75 minutes after block completion. No patient developed respiratory difficulty.

To our knowledge, there is only one case report of transient hemidiaphragmatic paresis after ultrasound-guided LSIB described in literature<sup>63</sup>. The patient received an ultrasound-guided LSIB with a volume of 30 ml ropivacaine, 5 mg/ml. The block was successful after 30 minutes, but the patients reported respiratory discomfort after 40 minutes. Supine chest x-ray after surgery showed an elevated hemidiaphragm which returned to normal position after block resolution. Because of the long distance between the needle insertion point and the course of the phrenic nerve and a low volume of LA used, the authors suggested with the existence of an accessory phrenic nerve (anatomical variation) in this patient.

We do recognize that the effect on the phrenic nerve from SSNB and/or LSIB should be examined by large scaled studies, ideally using sonography or possibly respiratory function tests.

#### 12.4 Limitations

The block sequence of our study was SSNB before LSIB. Measurement of the wrist angle and the sensorimotor status was obtained after both blocks. Therefore, we could not determine the precise degree to which a SSNB reduces the supination associated with LSIB. Another limitation was that data related to our primary (wrist angulation) and secondary (hand position) aims were not obtained at the same time point. Hence, this study did not allow us to perform direct comparisons at 30 minutes. However, we consider wrist angulation and power of lateral rotation of the humerus to be the main determinants of optimal hand/forearm positioning for dorsal hand surgery.



## 13 Discussion study III

### 13.1 The novel block combination for arthroscopic shoulder surgery

Theoretically, each component of our triple block may affect the phrenic nerve. The SSNB and LSIB are discussed earlier. To our knowledge, there are no reports of phrenic nerve block due to ultrasound-guided SCPB. For LA to reach the phrenic nerve, it would primarily have to penetrate the prevertebral fascia, then diffuse into the interscalene cleft and to the superficial aspect of the anterior scalene muscle. This seems unlikely as long as LA is carefully injected the intermuscular plane between the sternocleidomastoid and the the scalene muscles. Confident in identifying this space and inserting the needle into it, we have not been concerned about the risk of phrenic nerve effect, when performing this block. Nevertheless, to minimize any risk of phrenic nerve block we piloted different volumes and found 5 ml ropivacaine 5 mg/ml appropriate. This was a smaller LA volume (dose) than in SCPB studies by Tran et al. and Gürkan et al.<sup>52,64</sup>.

Several variants of ISB have been studied to reduce the incidence of hemidiaphragmatic paralysis. They included proximal digital compression of the interscalene cleft to inhibit cranial distribution of LA, low volume or low concentration of LA and administration of LA lateral to the sheath of the brachial plexus. None of them reduced the incidence of paralysis to below 20%<sup>26</sup>. We believe that the diaphragmatic risk of our alternative block (the triple block) is smaller, but this needs to be confirmed in a large-scaled study.

The novel combination of a SCPB, a SSNB, and an LSIB provides an alternative anesthetic modality for arthroscopic shoulder surgery. The need of three injections and change of patient's body position make the block procedure time longer than for ISB<sup>31</sup>. However, also low volume ISB requires the addition of SCPB to provide surgical anesthesia, in the area of the supraclavicular nerves. Diaphragm-sparing alternatives to ISB are requested for patients with reduced respiratory function. We think that any prolongation in block performance of the alternative method is then justified.

Our novel block combination causes palsy/paresis of the four sensorimotor nerves distal to the elbow (the musculocutaneous, radial, median and ulnar nerves), which makes the hand less functional during the day of operation. In contrast, the ISB does usually not affect all distal peripheral nerves, especially not the ulnar nerve<sup>31</sup>. Minimal motor power in the operated limb is actually a small concern of our surgeons since they do not recommend active or passive mobilization of the shoulder before postoperative day one. We do recognize that a few patients are uncomfortable about having a powerless limb for hours after the operation, but our impression is that this was considered a minor problem. To our experience good preoperative information is paramount to avoid any misunderstandings related to postoperative upper limb function and such information may also have a significant impact on how satisfied they are with the patient experience.

### 13.2 SSNB success criterion

ISB has a very high success rate which has been reported to be close to 100%<sup>26</sup>. In our study we found a success rate for the primary aim of 95% (19 out of 20 patients could be operated). The irregular patient received GA because of discomfort, not block failure. But four patients did not fulfill the block success criteria at 30 minutes, which resulted in a block success rate of 80%. Three of the 4 patients failed the SSN test. We think that our original success criterion ( $\leq 2$ ) may have been more strict than necessary. A less demanding power score  $\leq -4$  may be acceptable, which agrees with our later clinical experience and seems to be in line with the success definition of Rothe et al<sup>61</sup>.

### 13.3 Adverse events

Postoperatively, none of our patients suffered from nausea/vomiting and only one patient reported a pain score of 2 (numeric rating scale 0-10), while the others were pain free in the post anesthesia care unit. Neither dyspnea, hoarseness or dysphagia was observed. One patient had temporary Horner's syndrome. The low incidence of side effects and adverse events in our study underline the feasibility of the triple block method and should be confirmed in a future randomized study.

Regarding the risk of LAST, the total LA dose in the current study (including three blocks) was 277.5 mg ropivacaine. This is slightly below the commonly referred maximal dose of 300 mg for peripheral nerve blocks in Norway ([www.felleskatalogen.no](http://www.felleskatalogen.no)). None of the patients showed signs of LAST. Wank et al.<sup>65</sup> used a similar high dose of ropivacaine without any serious side effects. We

think that the LSIB-dose may be reduced for shoulder patients, further minimizing the risk of LAST.

#### 13.4 Limitations

The sample size in study III was only 20 patients, based on a power calculation assuming a block success rate of 90% with a confidence interval of  $\pm 13\%$ . A larger patient number from other centers will be a nice supplement to this first feasibility study of a novel method.

The SSN seldom has cutaneous innervation<sup>66,67</sup>. A motor test was therefore used to test SSNB. This was done by testing the force of lateral rotation of the humerus, while the arm was adducted and the elbow flexed at 90°. The infraspinatus muscle is most important for this movement. The other external rotators of the shoulder are the teres minor muscle and posterior fibers of the deltoid muscle, both innervated by the axillary nerve. However, the axillary nerve was regularly blocked by the LSIB and should not have an effect on the SSNB motor test.

In our shoulder study we did not examine the patients for phrenic nerve block. In future investigations of our triple block method, the diaphragmatic function should be sonographically controlled in all patients and a large-scaled study.

## 14 Conclusions

### 14.1 Study I

For hand and forearm surgery using the ultrasound-guided LSIB with ropivacaine 7.5 mg/ml the MEV<sub>50</sub> and the MEV<sub>95</sub> were 19 ml (95% CI, 14-27) and 31 ml (95% CI, 18-45), respectively.

### 14.2 Study II

The addition of a SSNB to a LSIB results in less wrist supination and an improved hand/forearm position in patients scheduled for dorsal hand surgery when compared to conditions after infraclavicular block alone.

### 14.3 Study III

The novel combination of SCPB, SSNB and LSIB, is feasible and provides surgical anesthesia and satisfactory postoperative analgesia in patients scheduled for arthroscopic shoulder surgery.

## 15 Perspectives

Data from study I-III should be followed up by future clinical trials. The following issues are of particular interest:

### Study I

- a) Sonographic techniques are continuously improving and users are increasingly able to identify structures of the plexus brachialis in more details. Recognition of the individual cords will most likely contribute to further reduction in MEV for the LSIB as LA may be injected selectively to/around the cords. Furthermore, a more selective block will most likely also allow us to use a lower concentration of LA. Further MEV studies with a selective block of the cords should be undertaken.
- b) The number of elderly patients is increasing and this will be reflected in the operating room. The influence of patient age on the required volume/dose of LA for our triple block should be determined.

### Study II

- c) MEV<sub>95</sub> for the SSNB using ropivacaine 5 mg/ml is not known and should be investigated.

### Study III

- d) Our study showed that arthroscopic shoulder surgery is possible using the novel shoulder block without GA. For both arthroscopic and open shoulder surgery, ISB and our novel shoulder block should be compared by a randomized controlled trial. The studies should analyze peroperative anesthesia, postoperative analgesia and the incidence of hemidiaphragmatic paralysis.

## 16 References

1. Waldeyer A. *Anatomi des Menschen*. Berlin: Walter de Gruyter & Co, 1965.
2. Woodburne R. *Essentials of human anatomy*. Oxford: Oxford University Press, 1978.
3. Casati A, Fanelli G, Cedrati V, Berti M, Aldegheri G, Torri G. Pulmonary function changes after interscalene brachial plexus anesthesia with 0.5% and 0.75% ropivacaine: a double-blinded comparison with 2% mepivacaine. *Anesth Analg* 1999; 88: 587-92.
4. Singh R. Variations of Cords of Brachial Plexus and Branching Pattern of Nerves Emanating From Them. *J Craniofac Surg* 2017; 28: 543-47.
5. Ullah H, Samad K, Khan FA. Continuous interscalene brachial plexus block versus parenteral analgesia for postoperative pain relief after major shoulder surgery. *Cochrane Database Syst Rev* 2014: CD007080.
6. Chan EY, Fransen M, Parker DA, Assam PN, Chua N. Femoral nerve blocks for acute postoperative pain after knee replacement surgery. *Cochrane Database Syst Rev* 2014: CD009941.
7. Hadzic A, Arliss J, Kerimoglu B, Karaca PE, Yufa M, Claudio RE, Vloka JD, Rosenquist R, Santos AC, Thys DM. A comparison of infraclavicular nerve block versus general anesthesia for hand and wrist day-case surgeries. *Anesthesiology* 2004; 101: 127-32.
8. O'Donnell BD, Ryan H, O'Sullivan O, Iohom G. Ultrasound-guided axillary brachial plexus block with 20 milliliters local anesthetic mixture versus general anesthesia for upper limb trauma surgery: an observer-blinded, prospective, randomized, controlled trial. *Anesth Analg* 2009; 109: 279-83.



9. Grauman S, Boethius J, Johansson J. Regional Anaesthesia Is Associated with Shorter Postanaesthetic Care and Less Pain Than General Anaesthesia after Upper Extremity Surgery. *Anesthesiol Res Pract* 2016; 2016: 6308371.
10. Ting PL, Sivagnanaratnam V. Ultrasonographic study of the spread of local anaesthetic during axillary brachial plexus block. *Br J Anaesth* 1989; 63: 326-9.
11. Wu TJ, Lin SY, Liu CC, Chang HC, Lin CC. Ultrasound imaging aids infraclavicular brachial plexus block. *Ma Zui Xue Za Zhi* 1993; 31: 83-6.
12. Ootaki C, Hayashi H, Amano M. Ultrasound-guided infraclavicular brachial plexus block: an alternative technique to anatomical landmark-guided approaches. *Reg Anesth Pain Med* 2000; 25: 600-4.
13. Kapral S, Krafft P, Eibenberger K, Fitzgerald R, Gosch M, Weinstabl C. Ultrasound-guided supraclavicular approach for regional anesthesia of the brachial plexus. *Anesth Analg* 1994; 78: 507-13.
14. Hadzic A. Hadzic's Peripheral Nerve Blocks and Anatomy for Ultrasound-Guided Regional Anesthesia In: Hadzic A, ed. 2nd edn: McGraw-Hill Education 2011.
15. Barrington MJ, Kluger R. Ultrasound guidance reduces the risk of local anesthetic systemic toxicity following peripheral nerve blockade. *Reg Anesth Pain Med* 2013; 38: 289-99.
16. Dickerson DM, Apfelbaum JL. Local anesthetic systemic toxicity. *Aesthet Surg J* 2014; 34: 1111-9.
17. Borgeat A, Ekatodramis G. Anaesthesia for shoulder surgery. *Best Pract Res Clin Anaesthesiol* 2002; 16: 211-25.
18. Chan CW, Peng PW. Suprascapular nerve block: a narrative review. *Reg Anesth Pain Med* 2011; 36: 358-73.

19. Fredrickson MJ, Kennedy RR. Regional anaesthesia and pain relief after surgery. *N Z Med J* 2010; 123: 9-11.
20. Fredrickson MJ, Krishnan S, Chen CY. Postoperative analgesia for shoulder surgery: a critical appraisal and review of current techniques. *Anaesthesia* 2010; 65: 608-24.
21. Lee JH, Cho SH, Kim SH, Chae WS, Jin HC, Lee JS, Kim YI. Ropivacaine for ultrasound-guided interscalene block: 5 mL provides similar analgesia but less phrenic nerve paralysis than 10 mL. *Can J Anaesth* 2011; 58: 1001-6.
22. Conroy PH, Awad IT. Ultrasound-guided blocks for shoulder surgery. *Curr Opin Anaesthesiol* 2011; 24: 638-43.
23. Riazi S, Carmichael N, Awad I, Holtby RM, McCartney CJ. Effect of local anaesthetic volume (20 vs 5 ml) on the efficacy and respiratory consequences of ultrasound-guided interscalene brachial plexus block. *Br J Anaesth* 2008; 101: 549-56.
24. Sites BD, Taenzer AH, Herrick MD, Gilloon C, Antonakakis J, Richins J, Beach ML. Incidence of local anesthetic systemic toxicity and postoperative neurologic symptoms associated with 12,668 ultrasound-guided nerve blocks: an analysis from a prospective clinical registry. *Reg Anesth Pain Med* 2012; 37: 478-82.
25. Urmey WF, Talts KH, Sharrock NE. One hundred percent incidence of hemidiaphragmatic paresis associated with interscalene brachial plexus anesthesia as diagnosed by ultrasonography. *Anesth Analg* 1991; 72: 498-503.
26. Tran DQ, Elgueta MF, Aliste J, Finlayson RJ. Diaphragm-Sparing Nerve Blocks for Shoulder Surgery. *Reg Anesth Pain Med* 2017; 42: 32-38.
27. Kaufman MR, Elkwood AI, Rose MI, Patel T, Ashinoff R, Fields R, Brown D. Surgical treatment of permanent diaphragm paralysis after interscalene nerve block for shoulder surgery. *Anesthesiology* 2013; 119: 484-7.

28. Sinha SK, Abrams JH, Barnett JT, Muller JG, Lahiri B, Bernstein BA, Weller RS. Decreasing the local anesthetic volume from 20 to 10 mL for ultrasound-guided interscalene block at the cricoid level does not reduce the incidence of hemidiaphragmatic paresis. *Reg Anesth Pain Med* 2011; 36: 17-20.
29. Renes SH, van Geffen GJ, Rettig HC, Gielen MJ, Scheffer GJ. Minimum effective volume of local anesthetic for shoulder analgesia by ultrasound-guided block at root C7 with assessment of pulmonary function. *Reg Anesth Pain Med* 2010; 35: 529-34.
30. Renes SH, Rettig HC, Gielen MJ, Wilder-Smith OH, van Geffen GJ. Ultrasound-guided low-dose interscalene brachial plexus block reduces the incidence of hemidiaphragmatic paresis. *Reg Anesth Pain Med* 2009; 34: 498-502.
31. Dhir S, Sondekoppam RV, Sharma R, Ganapathy S, Athwal GS. A Comparison of Combined Suprascapular and Axillary Nerve Blocks to Interscalene Nerve Block for Analgesia in Arthroscopic Shoulder Surgery: An Equivalence Study. *Reg Anesth Pain Med* 2016; 41: 564-71.
32. Dixon WJ. Staircase bioassay: the up-and-down method. *Neurosci Biobehav Rev* 1991; 15: 47-50.
33. Tran DQ, Dugani S, Dyachenko A, Correa JA, Finlayson RJ. Minimum effective volume of lidocaine for ultrasound-guided infraclavicular block. *Reg Anesth Pain Med* 2011; 36: 190-4.
34. Sandhu NS, Capan LM. Ultrasound-guided infraclavicular brachial plexus block. *Br J Anaesth* 2002; 89: 254-9.
35. Klaastad O, Smith HJ, Smedby O, Winther-Larssen EH, Brodal P, Breivik H, Fosse ET. A novel infraclavicular brachial plexus block: the lateral and sagittal technique, developed by magnetic resonance imaging studies. *Anesth Analg* 2004; 98: 252-6, table of contents.

36. Koscielniak-Nielsen ZJ, Rasmussen H, Hesselbjerg L, Gurkan Y, Belhage B. Clinical evaluation of the lateral sagittal infraclavicular block developed by MRI studies. *Reg Anesth Pain Med* 2005; 30: 329-34.
37. Gurkan Y, Hosten T, Solak M, Toker K. Lateral sagittal infraclavicular block: clinical experience in 380 patients. *Acta Anaesthesiol Scand* 2008; 52: 262-6.
38. Sauter AR, Smith HJ, Stubhaug A, Dodgson MS, Klaastad O. Use of magnetic resonance imaging to define the anatomical location closest to all three cords of the infraclavicular brachial plexus. *Anesth Analg* 2006; 103: 1574-6.
39. O'Donnell BD, Iohom G. An estimation of the minimum effective anesthetic volume of 2% lidocaine in ultrasound-guided axillary brachial plexus block. *Anesthesiology* 2009; 111: 25-9.
40. Casati A, Baciarello M, Di Cianni S, Danelli G, De Marco G, Leone S, Rossi M, Fanelli G. Effects of ultrasound guidance on the minimum effective anaesthetic volume required to block the femoral nerve. *Br J Anaesth* 2007; 98: 823-7.
41. Sauter AR, Dodgson MS, Stubhaug A, Halstensen AM, Klaastad O. Electrical nerve stimulation or ultrasound guidance for lateral sagittal infraclavicular blocks: a randomized, controlled, observer-blinded, comparative study. *Anesth Analg* 2008; 106: 1910-5.
42. Siegenthaler A, Moriggl B, Mlekusch S, Schliessbach J, Haug M, Curatolo M, Eichenberger U. Ultrasound-guided suprascapular nerve block, description of a novel supraclavicular approach. *Reg Anesth Pain Med* 2012; 37: 325-8.
43. Flohr-Madsen S, Ytrebo LM, Valen K, Wilsgaard T, Klaastad O. A randomised placebo-controlled trial examining the effect on hand supination after the addition of a suprascapular nerve block to infraclavicular brachial plexus blockade. *Anaesthesia* 2016; 71: 938-47.

44. Paternostro-Sluga T, Grim-Stieger M, Posch M, Schuhfried O, Vacariu G, Mittermaier C, Bittner C, Fialka-Moser V. Reliability and validity of the Medical Research Council (MRC) scale and a modified scale for testing muscle strength in patients with radial palsy. *J Rehabil Med* 2008; 40: 665-71.
45. Flohr-Madsen S, Ytrebo LM, Kregnes S, Wilsgaard T, Klaastad O. Minimum effective volume of ropivacaine 7.5 mg/ml for an ultrasound-guided infraclavicular brachial plexus block. *Acta Anaesthesiol Scand* 2013; 57: 495-501.
46. Martinez J, Sala-Blanch X, Ramos I, Gomar C. Combined infraclavicular plexus block with suprascapular nerve block for humeral head surgery in a patient with respiratory failure: an alternative approach. *Anesthesiology* 2003; 98: 784-5.
47. Sala-Blanch X, Lazaro JR, Correa J, Gomez-Fernandez M. Phrenic nerve block caused by interscalene brachial plexus block: effects of digital pressure and a low volume of local anesthetic. *Reg Anesth Pain Med* 1999; 24: 231-5.
48. Stundner O, Meissnitzer M, Brummett CM, Moser S, Forstner R, Kokofer A, Danninger T, Gerner P, Kirchmair L, Fritsch G. Comparison of tissue distribution, phrenic nerve involvement, and epidural spread in standard- vs low-volume ultrasound-guided interscalene plexus block using contrast magnetic resonance imaging: a randomized, controlled trial. *Br J Anaesth* 2016; 116: 405-12.
49. Boezaart AP, de Beer JF, du Toit C, van Rooyen K. A new technique of continuous interscalene nerve block. *Can J Anaesth* 1999; 46: 275-81.
50. Palhais N, Brull R, Kern C, Jacot-Guillarmod A, Charmoy A, Farron A, Albrecht E. Extrafascial injection for interscalene brachial plexus block reduces respiratory complications compared with a conventional intrafascial injection: a randomized, controlled, double-blind trial. *Br J Anaesth* 2016; 116: 531-7.
51. Thackeray EM, Swenson JD, Gertsch MC, Phillips KM, Steele JW, Burks RT, Tashjian RZ, Greis PE. Diaphragm function after interscalene brachial plexus block: a double-blind,

- randomized comparison of 0.25% and 0.125% bupivacaine. *J Shoulder Elbow Surg* 2013; 22: 381-6.
52. Tran DQ, Dugani S, Finlayson RJ. A randomized comparison between ultrasound-guided and landmark-based superficial cervical plexus block. *Reg Anesth Pain Med* 2010; 35: 539-43.
53. Musso D, Flohr-Madsen S, Meknas K, Wilsgaard T, Ytrebo LM, Klaastad O. A novel combination of peripheral nerve blocks for arthroscopic shoulder surgery. *Acta Anaesthesiol Scand* 2017; 61: 1192-202.
54. Klaastad O, Dodgson MS, Stubhaug A, Sauter AR. Lateral sagittal infraclavicular block (LSIB). *Reg Anesth Pain Med* 2006; 31: 86; author reply 86-7.
55. Soththisopha T, Elgueta MF, Samerchua A, Leurcharusmee P, Tiyaprasertkul W, Gordon A, Finlayson RJ, Tran DQ. Minimum Effective Volume of Lidocaine for Ultrasound-Guided Costoclavicular Block. *Reg Anesth Pain Med* 2017; 42: 571-74.
56. Musso D, Klaastad O, Wilsgaard T, Ytrebo LM. Brachial plexus block of the posterior and the lateral cord using ropivacaine 7.5 mg/mL. *Acta Anaesthesiol Scand* 2018.
57. Pavicic Saric J, Vidjak V, Tomulic K, Zenko J. Effects of age on minimum effective volume of local anesthetic for ultrasound-guided supraclavicular brachial plexus block. *Acta Anaesthesiol Scand* 2013; 57: 761-6.
58. Saranteas T, Finlayson RJ, Tran DQ. Dose-finding methodology for peripheral nerve blocks. *Reg Anesth Pain Med* 2014; 39: 550-5.
59. Pace NL, Stylianou MP. Advances in and limitations of up-and-down methodology: a precis of clinical use, study design, and dose estimation in anesthesia research. *Anesthesiology* 2007; 107: 144-52.

60. Hackworth RJ. A new and simplified approach to target the suprascapular nerve with ultrasound. *J Clin Anesth* 2013; 25: 347-8.
61. Rothe C, Steen-Hansen C, Lund J, Jenstrup MT, Lange KH. Ultrasound-guided block of the suprascapular nerve - a volunteer study of a new proximal approach. *Acta Anaesthesiol Scand* 2014; 58: 1228-32.
62. Haji K, Royse A, Green C, Botha J, Canty D, Royse C. Interpreting diaphragmatic movement with bedside imaging, review article. *J Crit Care* 2016; 34: 56-65.
63. Yang CW, Jung SM, Kwon HU, Kang PS, Cho CK, Choi HJ. Transient hemidiaphragmatic paresis after ultrasound-guided lateral sagittal infraclavicular block. *J Clin Anesth* 2013; 25: 496-8.
64. Gurkan Y, Tas Z, Toker K, Solak M. Ultrasound guided bilateral cervical plexus block reduces postoperative opioid consumption following thyroid surgery. *J Clin Monit Comput* 2015; 29: 579-84.
65. Wank W, Buttner J, Maier KR, Emanuelson BM, Selander D. Pharmacokinetics and efficacy of 40 ml ropivacaine 7.5 mg/ml (300 mg), for axillary brachial plexus block--an open pilot study. *Eur J Drug Metab Pharmacokinet* 2002; 27: 53-9.
66. Horiguchi M. The cutaneous branch of some human suprascapular nerves. *J Anat* 1980; 130: 191-5.
67. Ajmani ML. The cutaneous branch of the human suprascapular nerve. *J Anat* 1994; 185 ( Pt 2): 439-42.

# Minimum effective volume of ropivacaine 7.5 mg/ml for an ultrasound-guided infraclavicular brachial plexus block

S. FLOHR-MADSEN<sup>1,2</sup>, L. M. YTREBØ<sup>1,2</sup>, S. KREGNES<sup>1,2</sup>, T. WILSGAARD<sup>3</sup> and Ø. KLAASTAD<sup>1,2</sup>

<sup>1</sup>Department of Anaesthesiology, University Hospital of North Norway Tromsø, Norway, <sup>2</sup>Institute of Clinical Medicine, University of Tromsø, Tromsø, Norway and <sup>3</sup>Department of Community Medicine, University of Tromsø, Tromsø, Norway

**Background:** Ultrasound guidance has been shown to reduce the minimum effective volume (MEV) of local anaesthetics for several peripheral nerve blocks. Although the lateral sagittal infraclavicular block (LSIB) is a well-established anaesthesia method, MEV for this technique has not been established. Our aim with this study was to determine the MEV using ropivacaine 7.5 mg/ml for the LSIB method.

**Methods:** Twenty-five adult American Society of Anesthesiologists physical status I-II patients scheduled for hand surgery received an ultrasound-guided LSIB with ropivacaine 7.5 mg/ml. A successful block was defined as anaesthesia or analgesia for all five sensory nerves distal to the elbow, 30 min after local anaesthetic injection. The MEV for a successful block in 50% of the patients was determined by using the staircase up-and-down method introduced by Dixon and Massey. Logistic regression and probit transformation were applied to estimate the MEV for a successful block in 95% of the patients.

**Results:** The patients received ropivacaine 7.5 mg/ml volumes in the range of 12.5–30 ml. The MEVs in 50% and 95% of the patients were 19 ml [95% confidence interval (CI), 14–27] and 31 ml (95% CI, 18–45), respectively.

**Conclusions:** For surgery distal to the elbow, the MEV in 95% of patients for an ultrasound-guided LSIB with ropivacaine 7.5 mg/ml was estimated to be 31 ml (95% CI, 18–45 ml). Further studies should determine the factors that influence the volume of local anaesthetic required for a successful infraclavicular block.

Accepted for publication 2 January 2013

© 2013 The Acta Anaesthesiologica Scandinavica Foundation  
Published by Blackwell Publishing Ltd.

**P**ERFORMING regional anaesthesia with a minimum effective volume (MEV) of a local anaesthetic (LA), may reduce the risk of systemic LA toxicity.<sup>1</sup> This is of particular interest if a patient requires more than one block. Ultrasound guidance for peripheral nerve blocks may reduce the volume of LA required, because it allows real-time observation of the needle, nerves and LA distribution.

Minimal volumes of LA have been reported for interscalene<sup>2–5</sup> and axillary<sup>6–8</sup> blocks, but not for supraclavicular<sup>9,10</sup> and not consistently for infraclavicular methods.<sup>11,12</sup> The lateral sagittal infraclavicular plexus block (LSIB) is a well-established method for surgery distal to the elbow.<sup>13–16</sup> However, its MEV for a given LA has not yet been determined. The goal of the present study was to estimate this volume for ropivacaine 7.5 mg/ml, when given for an ultrasound-guided LSIB.

## Methods

The study was in accordance with the Helsinki declaration, approved by the regional ethical committee of North Norway, and registered at Clinical Trials.gov (NCT01493986). Twenty-five patients scheduled for hand surgery gave written informed consent to participate in this prospective study. They were to undergo either excision of the trapezium bone for carpometacarpal arthrosis or open fasciectomy for Dupuytren's contracture. The other inclusion criteria were American Society of Anesthesiologists (ASA) physical status I-II, age between 18 and 65 years and body mass index (BMI) between 20 and 35 kg/m<sup>2</sup>. Exclusion criteria were pregnancy, patients with contraindications to regional anaesthesia, allergy to LAs, patients on major opioids because of chronic pain,



atrioventricular block, drug-treated diabetes and peripheral neuropathy.

The blocks were performed in a separate room close to the operating theatre. Standard monitoring included electrocardiogram, non-invasive arterial pressure and pulse oximetry. Intravenous midazolam or fentanyl was administered as required before, or during, the block procedure to reduce anxiety or ameliorate procedural pain. Midazolam was titrated using 0.5–1.0 mg and fentanyl 25–50 µg increments.

Ultrasound-guided LSIB was performed by one of two investigators who had considerable experience with the method. The patients were supine with the arm to be blocked adducted. We used a SonoSite M-Turbo unit (SonoSite, Inc., Bothell, WA, USA) with a C11x, 8–5 MHz broadband curved array probe. A skin wheal was raised with 1 ml lidocaine 20 mg/ml before insertion of an ultrasound echogenic 22Gx80mm needle (PAJUNK® GmbH Medizintechnologie, Geisingen, Germany).

The needle insertion point was at the intersection between the lower edge of the clavicle and the medial surface of the coracoid process.<sup>14</sup> Needle advancement was in the parasagittal plane, with continuous observation of the needle tip, using the in-plane technique. Considering the artery as a clock face (Fig. 1) with 12 o'clock ventral, the cords are normally found inside a periarterial sector from 3 to 11 o'clock and within 2 cm from the midaxis of the axillary artery.<sup>17</sup> The aim for the injections was an even distribution of LA inside this sector only. We did not selectively inject towards objects which were assumed to be cords, even if they were located outside the sector. The first deposit was, as a rule, at 8 o'clock and close to the artery. An MRI study has shown that this site is, on average, closest to all the cords.<sup>17</sup> Subsequent injections were most often made at 6–7 o'clock and 9 o'clock, and usually also at a fourth position, depending on the observed spread of LA. Finally, we did not make a subcutaneous infiltration in the axilla to block the intercostobrachial nerve.

Triple monitoring was applied to reduce the risk of intraneural needle tip position. Firstly, by ultrasound, when the relationship between needle and nerve was carefully observed. Secondly, a nerve stimulator (Stimuplex® HNS12, B. Braun, Melsungen, Germany) was continuously active after insertion of the block needle, using a current of 0.2 mA and 0.1 ms duration at 2 Hz. If a motor response was obtained, the needle was withdrawn in steps of 1 mm until the response disappeared. Thirdly, we

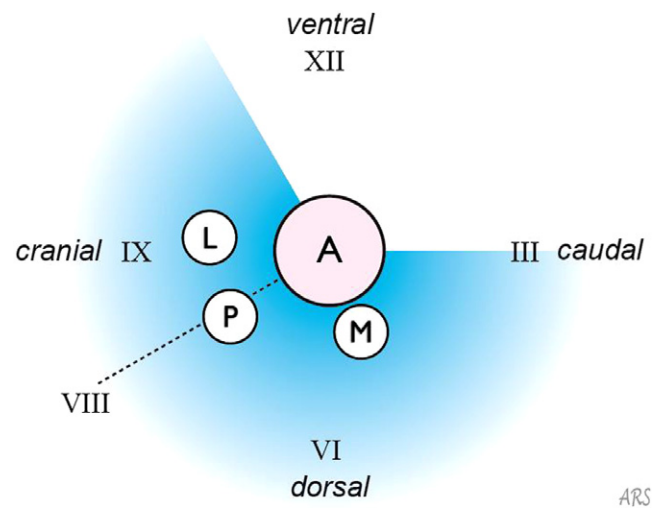


Fig. 1. The periarterial sector. Schematic drawing in the parasagittal plane of the lateral sagittal infraclavicular block, showing the axillary artery (A) with clock face orientation (XII o'clock ventral), the cords and a blue-coloured periarterial sector. The sector extends from III to XI o'clock and radially 2 cm from the midaxis of the artery. It usually includes the lateral (L), posterior (P) and medial (M) cords, indicated in their average periarterial positions. The point on average closest to the cords is at VIII o'clock, immediately outside the arterial wall. The study protocol implied filling up the sector with local anaesthetic. The drawing is made by Axel R. Sauter, based on data and a figure from a previous study.<sup>17</sup>

assessed the resistance to injection manually, and never injected if there was increased resistance.

Ropivacaine 7.5 mg/ml was administered in a pre-determined volume for each patient, according to the methodology described in Statistics and Power Analysis. The first patient received a volume of 30 ml, which, based on our experience, was expected to be sufficient in most patients. The volume for consecutive patients was defined by the block effect in the preceding patient. A successful block was followed by a reduction of the volume by 2.5 ml, whereas a failed block caused a 2.5 ml volume increase. To reduce the risk of systemic LA toxicity, we decided a priori not to exceed 40 ml injectate.

An observer blinded for the block procedure and the injected volume assessed the sensory status of the limb to be operated while consecutively comparing with the contralateral arm. Testing times were before the block and every fifth minute for 30 min after finishing LA administration. Ice cubes were repeatedly applied to the skin at pre-marked points in the areas of the radial, median, ulnar, musculocutaneous and medial antebrachial cutaneous nerves. These points (Fig. 2) were between the 1 and

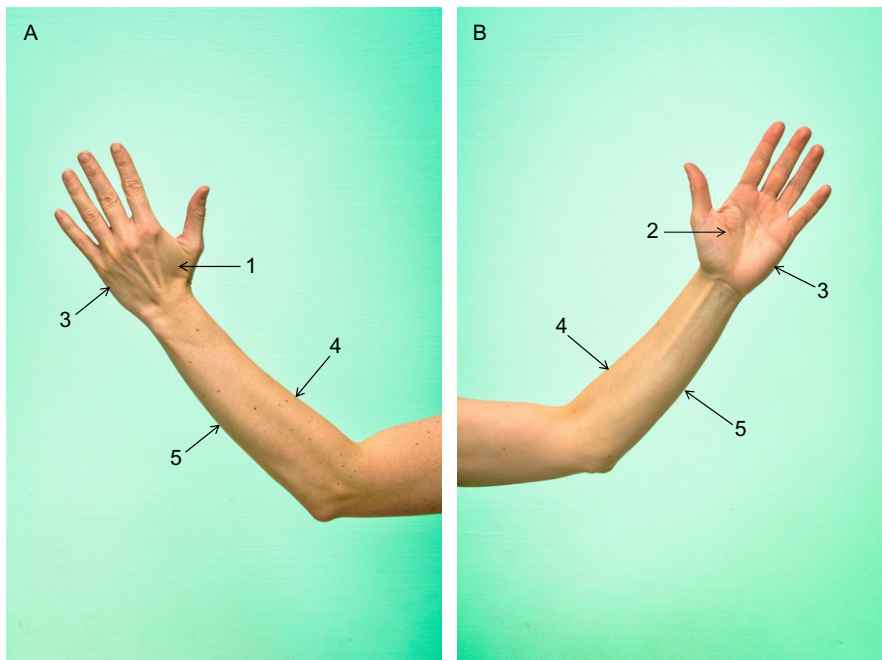


Fig. 2. Sensory testing points. Photos of the hand and forearm, (A) from the dorsal (extensor) and (B) from the volar (flexor) surface. The arrows indicate the points for testing the sensory state in the innervation areas of five terminal nerves. Each nerve is indicated by a number. 1: N. radialis, 2: N. medianus, 3: N. ulnaris, 4: N. musculocutaneus, 5: N. cutaneus antebrachii medialis.

2. metacarpals dorsally, between the 1 and 2. metacarpals on the palm, on the ulnar side of the 5. metacarpal, over the most prominent part of the brachioradial muscle and in the middle of the forearm on the ulnar side, respectively. A four-divided sensory scale was used:<sup>14</sup> 0 = normal cold feeling, 1 = hypoalgesia (patient feels coldness, but less than on the contralateral side), 2 = analgesia (patient feels touch, but not coldness), 3 = anaesthesia (no feeling of coldness or touch). A block was defined as successful if all five nerves had a score of 2 or 3 within 30 min after completed LA injection. The block was a failure if one or more nerves had a score of 1 or 0. Patients with incomplete blocks would, on indication, receive supplementary peripheral nerve blocks or general anaesthesia.

During the block procedure, we recorded paraesthesia, motor response to the nerve stimulator, vessel puncture by the block needle, the number of needle passes, the block performance time and the injection time. Block performance time was defined as the time from insertion to final withdrawal of the block needle. The injection time was the interval between start and end of LA injection. An additional needle pass was defined as needle retraction of at least 10 mm prior to further needle insertion. Patients were also monitored for signs of systemic LA toxicity, pneumothorax and the occurrence of tourniquet pain.

Hospital discharge on the day of surgery was planned for all patients. The day after surgery, we

telephoned the patients to learn about their block recovery. Additionally, the surgeons were required to report sensory or motor deficits observed post-operatively at outpatient consultations. Patients with Dupuytren's contracture were seen approximately 1 week post-operatively, and patients with carpometacarpal arthrosis were seen 5 weeks after surgery.

#### Statistics and power analysis

The primary outcome measure was the MEV of ropivacaine 7.5 mg/ml required for successful LSIB in 50% of the patients (MEV<sub>50</sub>). For sample size calculation, we applied the formula by Dixon and Massey,  $n = 2(\text{SD}/\text{SEM})^2$  where SD is standard deviation and SEM the standard error of the mean.<sup>18</sup> Assuming a 5 ml SD and 1.5 ml SEM, the formula then suggests 22 patients for the study. Anticipating a dropout of three patients, we decided to enrol 25 patients.

The staircase up-and-down method for large samples introduced by Dixon and Massey<sup>18</sup> was used to estimate the MEV<sub>50</sub> and its 95% confidence interval (95% CI). For this plot, we also required a priori a minimum of five negative-positive up-and-down deflections.<sup>5,19</sup> To estimate the MEV in 95% of patients (MEV<sub>95</sub>), our secondary outcome measure, logistic regression and probit transformation were used, applying the SAS statistical software package (SAS®, V9.2, SAS Institute Inc., Cary, NC, USA). The binary response in the logistic regression model was failed block (yes/no) with LA volume as the

Table 1

Patient characteristics and surgical data (n = 25).	
Age, mean (SD), years	57.6 (7.7)
Gender (male/female), n	14/11
BMI, mean (SD), kg/m <sup>2</sup>	26 (3.9)
ASA physical status (I/II), n	7/18
Types of surgery (trapezius excision/fasciectomy Dupuytren), n	13/12
Tourniquet time *	
Excision of the trapezium bone, median (range), min	73 (49–134)
Fasciectomy Dupuytren, median (range), min	99 (49–193)
Duration of surgery	
Excision of the trapezium bone, median (range), min	80 (39–132)
Fasciectomy Dupuytren, median (range), min	92 (43–207)

Continuous variables are presented as mean (standard deviation) or median (range). Categorical variables are presented as counts.

\*Some of the patients had tourniquet for more than one period. Periods of deflated tourniquet were then not included in their tourniquet time.

ASA, American Society of Anesthesiologists; BMI, body mass index; fasciectomy Dupuytren, open fasciectomy in patients with Dupuytren's contraction.

independent variable. Continuous data are presented as mean (SD) or median (range) as appropriate. Categorical data are presented as n (%).

## Results

The patients were recruited and operated during the period March–May 2012. All 25 of subjects completed the study. Their characteristics are shown in Table 1. Block performance data are summarised in Table 2. LA was injected in a volume range from 12.5 ml to 30 ml. The sequence of successful and failed blocks is illustrated in Fig. 3. It shows seven deflections from failed to successful block. MEV<sub>50</sub> was 19 ml (95% CI, 14–27) and the calculated MEV<sub>95</sub> 31 ml (95% CI, 18–45).

As foreseen by the study design, a large portion of the patients had a failed block. This was the case in 10 out of 25 patients, (Table 3). However, comparing the area that was blocked with the area of planned surgery, only 2 of these 10 patients required supplemental peripheral nerve blocks.

Intraoperatively, intravenous fentanyl was given to nine patients and midazolam to eight patients because of patient discomfort, but never because of surgical pain. The amounts of fentanyl and midazolam to these patients had means of 58 (25) µg and 1.4 (0.7) mg, respectively. Four patients reported tourniquet pain. This required intravenous fentanyl

Table 2

Block data.	
Midazolam (mg), n = 20*	1.5 (0.7)
Fentanyl (µg), n = 10†	60 (20.7)
Performance time, median (range), min	7.9 (4.8–14.2)
Injection time, median (range), min	5.9 (3.6–10.1)
Number of injections (deposits)	4 (2–7)
No. needle passes, n (%)	
1	16 (64)
2	2 (8)
3	3 (12)
4	4 (16)
Paraesthesia, n (%)	8 (32)
Nerve stimulation, n (%)	3 (12)
Vascular puncture‡, n (%)	2 (8)
Systemic toxicity to LA, n (%)	0 (0)
Clinical signs of pneumothorax, n (%)	0 (0)

Continuous variables are presented as means [standard deviation (SD)] or median (range). Categorical variables are presented as count (percentage).

\*Mean and SD based on 20 patients who received midazolam, before or during the block procedure.

†Mean and SD based on 10 patients who received fentanyl, before or during the block procedure. All 25 patients received at least one of the two drugs.

‡One puncture of a skin vessel and one of the axillary vein. LA, local anaesthetic.

in only one of the patients, a single dose of 50 µg with good effect. None of the 25 patients received deep sedation or general anaesthesia.

Adverse events and side-effects are listed in Table 2. Among the three patients with a motor response to the nerve stimulator, ultrasound did not suggest an intraneural position of the needle tip. Nevertheless, the needle was slightly withdrawn. All 25 patients reported complete recovery of sensory and motor functions the day after surgery. Also, during the surgical ambulatory controls, there were no signs of nerve dysfunction caused by anaesthesia.

## Discussion

In the present study of ultrasound-guided LSIB with ropivacaine 7.5 mg/ml, we found a MEV<sub>50</sub> of 19 ml (95% CI, 14–27) and a calculated MEV<sub>95</sub> of 31 ml (95% CI, 18–45).

The wide CI indicates uncertainty about the accuracy of MEV<sub>95</sub>. Nevertheless, we believe in reporting the MEV<sub>95</sub>, due to its clinical relevance and, potentially, to compare it with results from other similar studies. The MEV<sub>95</sub> may change with arm position, e.g. 90° arm abduction instead of LSIB's standard with adducted arm. It may also vary for other types and concentrations of LAs, plus admixtures to the LA.

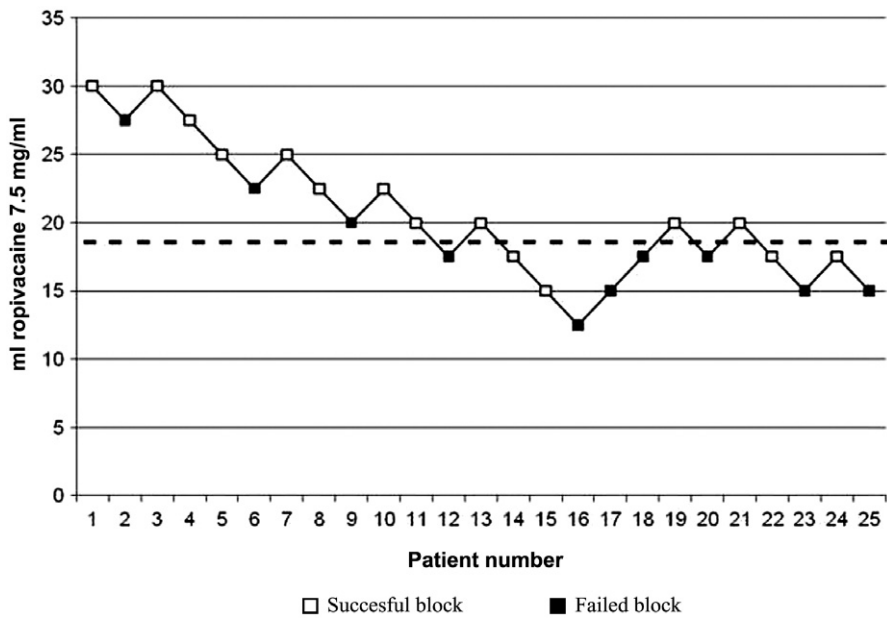


Fig. 3. Sequential block results of the ultrasound-guided lateral sagittal infraclavicular block using ropivacaine 7.5 mg/ml according to the staircase up-and-down method. The horizontal dashed line (---) represents the minimum effective volume in 50% of the patients, 19 ml.

Table 3

Details of the individual blocks.

Patient number	Surgical procedure	Anaesthesiologist	Volume, ml	Block success 30 min post-injection	Supplemental LA* required for surgery
1	Trapezium excision	A	30	Yes	No
2	Trapezium excision	A	27.5	No	No
3	Trapezium excision	B	30	Yes	No
4	Trapezium excision	B	27.5	Yes	No
5	Trapezium excision	B	25	Yes	No
6	Trapezium excision	B	22.5	No	No
7	Trapezium excision	B	25	Yes	No
8	Fasciectomy Dupuytren	A	22.5	Yes	No
9	Fasciectomy Dupuytren	A	20	No	Yes†
10	Trapezium excision	B	22.5	Yes	No
11	Trapezium excision	A	20	Yes	No
12	Fasciectomy Dupuytren	B	17.5	No	Yes‡
13	Fasciectomy Dupuytren	A	20	Yes	No
14	Fasciectomy Dupuytren	B	17.5	Yes	No
15	Fasciectomy Dupuytren	A	15	Yes	No
16	Fasciectomy Dupuytren	A	12.5	No	No
17	Fasciectomy Dupuytren	B	15	No	No
18	Fasciectomy Dupuytren	A	17.5	No	No
19	Fasciectomy Dupuytren	B	20	Yes	No
20	Trapezium excision	A	17.5	No	No
21	Trapezium excision	B	20	Yes	No
22	Fasciectomy Dupuytren	B	17.5	Yes	No
23	Trapezium excision	A	15	No	No
24	Trapezium excision	A	17.5	Yes	No
25	Fasciectomy Dupuytren	B	15	No	No

The layout of this table is modified from a table by E. Duggan et al.<sup>9</sup>

\*LA = ropivacaine 5 mg/ml.

†Ulnar and radial nerves.

‡Ulnar, radial, median and musculocutaneous nerves.

Fasciectomy Dupuytren, open fasciectomy in patients with Dupuytren's contraction; LA, local anaesthetic.

We think, in line with Renes et al.,<sup>5</sup> that the small number of patients, particularly at the higher volume end, may have contributed to the wide CI in our and several other studies.<sup>2,5,9,19</sup> Patient variability may also have added to the extensive CI. Although our patients were all ASA class I or II, their age and BMI had a wide range.

MEV and CI may also be dependent on the validity of the described periarterial sector in including the cords.<sup>17</sup> It was based on magnetic resonance imaging of only 20 volunteers. However, sector considerations were beneficial in a subsequent study by Sauter et al., when not all cords could be identified.<sup>14</sup> This also corresponds to our usual clinical experience with LSIB. We therefore think that in the parasagittal plane of LSIB, in most patients, the sector includes the cords.

The MEV<sub>95</sub> of our study corresponds to our current practice using LSIB. Taken together, we think that injection of 31 ml of ropivacaine 7.5 mg/ml is a recommendable volume when performing LSIB, as described in this paper.

The MEV has been assessed for another infraclavicular block, the 'double bubble' method described by Tran et al.<sup>20</sup> Performing the block, LA is injected at a single site immediately dorsal to the axillary artery. This creates a double bubble sign. As described by the authors, the sign 'consists superiorly of the axillary artery (in short axis) superimposed on an inferior bubble created by the LA injection'. If necessary, the needle is repositioned to obtain the double bubble. The LA bubble then contacts or is close to only a small dorsal segment of the artery. This contrasts our method where the LA initially covers 2/3 of the arterial circumference, in a sector usually including the cords.<sup>17</sup>

Tran et al. calculated a MEV<sub>90</sub> of 35 ml (95% CI, 30–37.5 ml) for the double bubble method using lidocaine 15 mg/ml with epinephrine 5 µg/ml.<sup>12</sup> It may possibly indicate a higher volume requirement than for the LSIB. However, differences between the studies in choices of LAs, definition of successful block and statistical workout make an appropriate comparison impossible.

Sandhu and Capan established an infraclavicular block method with selective LA injections towards each of the cords more than a decade ago.<sup>21</sup> In a report of bilateral blocks, although not a MEV study, they found 20 ml for each side sufficient when using 20 mg/ml lidocaine with sodium bicarbonate (0.9 mEq/10 ml) and epinephrine 5 µg/ml.<sup>11</sup> Again, the difference of LAs used makes a comparison with our LSIB study difficult.

We assume that continued improvement of ultrasound apparatuses and user competence will enable most practitioners to identify all the cords. Whether this will result in further reduction of MEV for LSIB and other infraclavicular methods, by selective injections towards the cords, remains to be studied.

In conclusion, for hand or forearm surgery using the ultrasound-guided LSIB with ropivacaine 7.5 mg/ml, the MEV<sub>95</sub> was 31 ml (95% CI, 18–45 ml). Future studies should determine factors that influence the volume of LA required for a successful infraclavicular block.

## Acknowledgements

We thank Axel R. Sauter, MD, PhD (Oslo, Norway), for discussions of our study and for having drawn Fig. 1. We thank Hossam El Beheiry, MB, BCh, PhD, FRCPC (Toronto, Canada), for clarifying features of Dixon and Massey's method as applied in a former study.<sup>9</sup>

*Conflicts of interest:* The authors have no conflicts of interest.

*Funding:* This study received departmental funding only.

## References

1. Sites BD, Taenzer AH, Herrick MD, Gilloon C, Antonakakis J, Richins J, Beach ML. Incidence of local anesthetic systemic toxicity and postoperative neurologic symptoms associated with 12,668 ultrasound-guided nerve blocks: an analysis from a prospective clinical registry. *Reg Anesth Pain Med* 2012; 37: 478–82.
2. McNaught A, Shastri U, Carmichael N, Awad IT, Columb M, Cheung J, Holtby RM, McCartney CJ. Ultrasound reduces the minimum effective local anaesthetic volume compared with peripheral nerve stimulation for interscalene block. *Br J Anaesth* 2011; 106: 124–30.
3. Gautier P, Vandepitte C, Ramquet C, DeCoopman M, Xu D, Hadzic A. The minimum effective anesthetic volume of 0.75% ropivacaine in ultrasound-guided interscalene brachial plexus block. *Anesth Analg* 2011; 113: 951–5.
4. Renes SH, Rettig HC, Gielen MJ, Wilder-Smith OH, van Geffen GJ. Ultrasound-guided low-dose interscalene brachial plexus block reduces the incidence of hemidiaphragmatic paresis. *Reg Anesth Pain Med* 2009; 34: 498–502.
5. Renes SH, van Geffen GJ, Rettig HC, Gielen MJ, Scheffer GJ. Minimum effective volume of local anesthetic for shoulder analgesia by ultrasound-guided block at root C7 with assessment of pulmonary function. *Reg Anesth Pain Med* 2010; 35: 529–34.
6. O'Donnell BD, Iohom G. An estimation of the minimum effective anesthetic volume of 2% lidocaine in ultrasound-guided axillary brachial plexus block. *Anesthesiology* 2009; 111: 25–9.
7. Harper GK, Stafford MA, Hill DA. Minimum volume of local anaesthetic required to surround each of the constituent nerves of the axillary brachial plexus, using ultrasound guidance: a pilot study. *Br J Anaesth* 2010; 104: 633–6.
8. Marhofer P, Eichenberger U, Stockli S, Huber G, Kapral S, Curatolo M, Kettner S. Ultrasonographic guided axillary plexus blocks with low volumes of local anaesthetics: a crossover volunteer study. *Anaesthesia* 2010; 65: 266–71.
9. Duggan E, El Beheiry H, Perlas A, Lupu M, Nuica A, Chan V, Brull R. Minimum effective volume of local anesthetic for

- ultrasound-guided supraclavicular brachial plexus block. *Reg Anesth Pain Med* 2009; 34: 215–18.
10. Tran de QH, Dugani S, Correa JA, Dyachenko A, Alsenosy N, Finlayson RJ. Minimum effective volume of lidocaine for ultrasound-guided supraclavicular block. *Reg Anesth Pain Med* 2011; 36: 466–9.
  11. Sandhu NS, Maharlouei B, Patel B, Erkulwater E, Medabalmi P. Simultaneous bilateral infraclavicular brachial plexus blocks with low-dose lidocaine using ultrasound guidance. *Anesthesiology* 2006; 104: 199–201.
  12. Tran de QH, Dugani S, Dyachenko A, Correa JA, Finlayson RJ. Minimum effective volume of lidocaine for ultrasound-guided infraclavicular block. *Reg Anesth Pain Med* 2011; 36: 190–4.
  13. Koscielniak-Nielsen ZJ, Rasmussen H, Hesselbjerg L, Gurkan Y, Belhage B. Clinical evaluation of the lateral sagittal infraclavicular block developed by MRI studies. *Reg Anesth Pain Med* 2005; 30: 329–34.
  14. Sauter AR, Dodgson MS, Stubhaug A, Halstensen AM, Klaastad O. Electrical nerve stimulation or ultrasound guidance for lateral sagittal infraclavicular blocks: a randomized, controlled, observer-blinded, comparative study. *Anesth Analg* 2008; 106: 1910–15.
  15. Klaastad O, Sauter AR, Dodgson MS. Brachial plexus block with or without ultrasound guidance. *Curr Opin Anaesthesiol* 2009; 22: 655–60.
  16. Gurkan Y, Tekin M, Acar S, Solak M, Toker K. Is nerve stimulation needed during an ultrasound-guided lateral sagittal infraclavicular block? *Acta Anaesthesiol Scand* 2010; 54: 403–7.
  17. Sauter AR, Smith HJ, Stubhaug A, Dodgson MS, Klaastad O. Use of magnetic resonance imaging to define the anatomical location closest to all three cords of the infraclavicular brachial plexus. *Anesth Analg* 2006; 103: 1574–6.
  18. Dixon WJ, Massey FJ. *Introduction to statistical analysis*, 4th edn. New York: McGraw-Hill, 1983.
  19. Casati A, Baciarello M, Di Cianni S, Danelli G, De Marco G, Leone S, Rossi M, Fanelli G. Effects of ultrasound guidance on the minimum effective anaesthetic volume required to block the femoral nerve. *Br J Anaesth* 2007; 98: 823–7.
  20. Tran de QH, Clemente A, Tran DQ, Finlayson RJ. A comparison between ultrasound-guided infraclavicular block using the ‘double bubble’ sign and neurostimulation-guided axillary block. *Anesth Analg* 2008; 107: 1075–8.
  21. Sandhu NS, Capan LM. Ultrasound-guided infraclavicular brachial plexus block. *Br J Anaesth* 2002; 89: 254–9.

**Address:**

*Dr Sandra Flohr-Madsen*  
 Department of Anaesthesiology  
 University Hospital of North Norway  
 9038 Tromsø  
 Norway  
 e-mail: sandra.flohr-madsen@unn.no

# Original Article

## A randomised placebo-controlled trial examining the effect on hand supination after the addition of a suprascapular nerve block to infraclavicular brachial plexus blockade

S. Flohr-Madsen,<sup>1</sup> L. M. Ytrebø,<sup>2</sup> K. Valen,<sup>3</sup> T. Wilsgaard<sup>4</sup> and Ø. Klaastad<sup>2</sup>

*1 Consultant Anaesthetist, 2 Consultant Anaesthetist and Professor of Anaesthesiology, 3 Consultant Plastic Surgeon, 4 Professor of Statistics, University Hospital of North Norway and UiT-The Arctic University of Norway, Tromsø, Norway*

### Summary

Some surgeons believe that infraclavicular brachial plexus blocks tends to result in supination of the hand/forearm, which may make surgical access to the dorsum of the hand more difficult. We hypothesised that this supination may be reduced by the addition of a suprascapular nerve block. In a double-blind, randomised, placebo-controlled study, our primary outcome measure was the amount of supination (as assessed by wrist angulation) 30 min after infraclavicular brachial plexus block, with (suprascapular group) or without (control group) a supplementary suprascapular block. All blocks were ultrasound-guided. The secondary outcome measure was an assessment by the surgeon of the intra-operative position of the hand. Considering only patients with successful nerve blocks, mean (SD) wrist angulation was lower (33 (27) vs. 61 (44) degrees;  $p = 0.018$ ) and assessment of the hand position was better (11/11 vs. 6/11 rated as 'good';  $p = 0.04$ ) in the suprascapular group. The addition of a suprascapular nerve block to an infraclavicular brachial plexus block can provide a better hand/forearm position for dorsal hand surgery.

Correspondence to: S. Flohr-Madsen

Email: [sandra.flohr@gmx.de](mailto:sandra.flohr@gmx.de)

Accepted: 29 March 2016

Presented in part at the Federation of European Societies for Surgery of the Hand in Santander, Spain, June 2016.

Keywords: *infraclavicular nerve block; peripheral nerves: anatomy; suprascapular nerve block; ultrasound; upper extremity nerve blocks: indications*

### Introduction

Infraclavicular brachial plexus blocks can provide anaesthesia and analgesia for surgical procedures distal to the shoulder. However, for dorsal hand surgery, some surgeons have observed that lateral sagittal infraclavicular brachial plexus blocks [1] tend to result in supination of the hand, thereby making surgical access awkward.

The usual practical solution is that the surgical assistant manually maintains the patient's hand in

pronation, but this limits the assistant's capacity for other intra-operative tasks. An alternative solution is the use of a surgical hand immobiliser (lead hand). This, however, impedes the surgeon's ability to easily assess the hand in different positions and may strain the dorsal skin of the fingers, which is more vulnerable than the palmar side to the effects of pressure. To our knowledge, the reasons for hand supination following infraclavicular brachial plexus block have not been described in the literature.

Supination of the hand and forearm usually occurs by lateral rotation of the radius, but when the upper limb is extended, supination may also be caused by lateral rotation of the humerus. The responsible distal muscles are supinator and biceps brachii, which are innervated by the radial and musculocutaneous nerves, respectively. These nerves are blocked by infraclavicular brachial plexus blocks [1, 2] and, therefore, should not cause supination. The relevant proximal muscles for supination are infraspinatus, supraspinatus, posterior fibres of deltoid, teres minor and the long head of triceps [3, 4]. Contraction of the latter three muscles is also inhibited during lateral sagittal infraclavicular brachial plexus block via its effect on the axillary and radial nerves [2]. However, the main lateral rotator of the humerus is the infraspinatus muscle, which along with the supraspinatus muscle, is innervated by the suprascapular nerve. This nerve has not been reported to be affected by lateral sagittal infraclavicular brachial plexus block.

We, therefore, hypothesised that the addition of a suprascapular nerve block to lateral sagittal infraclavicular brachial plexus block would reduce supination and thereby improve upper limb positioning for dorsal hand surgery. Our primary outcome measure was the amount of supination (as assessed by wrist angulation) in patients 30 min after lateral sagittal infraclavicular brachial plexus block, with and without an additional suprascapular nerve block. Our secondary outcome measure was the surgeons' rating of the adequacy of intra-operative hand/forearm position.

## Methods

The study was approved by the regional ethical committee of North Norway. The trial was performed at the University Hospital of North Norway in Tromsø from January to April 2014 in accordance with the Helsinki Declaration. After written informed consent, we recruited patients scheduled for dorsal hand surgery under brachial plexus block using the following inclusion criteria: age 18–70 years; BMI 20–36 kg.m<sup>-2</sup>; and ASA physical status 1–3. We did not study patients who were not able to fully extend and abduct their arm or pronate their hand  $\leq 15^\circ$ . Other exclusion criteria included: pregnancy; coagulation disorders; allergy to local anaesthetics; atrioventricular block;

cardiac pacemaker; peripheral neuropathy; drug-treated diabetes; and use of anticoagulation drugs other than acetylsalicylic acid or dipyridamol.

Participants were randomly allocated on a 1:1 basis to the suprascapular or the control groups using computer-generated patient numbers in sealed envelopes. The suprascapular group had suprascapular nerve block (4 ml ropivacaine 5 mg.ml<sup>-1</sup>) and the control group had a sham suprascapular nerve block (4 ml saline 0.9%). Both groups then had a lateral sagittal infraclavicular brachial plexus block (31 ml ropivacaine 7.5 mg.ml<sup>-1</sup>). A study nurse opened the randomisation envelope and provided either ropivacaine or saline in an unlabelled syringe for the suprascapular nerve block procedure. Thus, the patient, block performer, assistant and assessor were all blinded to group allocation.

The first author, who was experienced in both techniques, performed all blocks. Standard monitoring included pulse oximetry, electrocardiogram and non-invasive blood pressure. The patients received intravenous midazolam (0–2 mg) and/or fentanyl (0–50  $\mu$ g) for comfort. The suprascapular nerve block was performed according to the method described by Siegenthaler et al. [5] with small modifications; we preferred having the patients in a semi-lateral position with a slightly elevated upper body. For ultrasound guidance, we used the SonoSite Edge unit (SonoSite, Inc., Bothell, WA, USA) with a 50 mm linear array transducer (Hfl50x, 15–6 MHz). It was initially positioned immediately cranial and parallel to the middle of the clavicle to provide a cross-sectional view of the subclavian artery and the brachial plexus. Maintaining a short-axis view of the brachial plexus, the transducer was moved cranially to identify the superior trunk. By slowly returning the transducer to the initial position, we could observe the suprascapular nerve diverging from its trunk (Video S1). The suprascapular nerve was identified in the most craniolateral part of the brachial plexus cluster area. Tracing it laterally, we slowly slid the transducer to an oblique sagittal position, in the posterior cervical triangle. The position of accompanying vessels, ribs and pleura were carefully observed during the procedure. Before insertion of the block needle, the skin was infiltrated with 2 ml lidocaine (10 mg.ml<sup>-1</sup>) and then, using an in-plane



technique, the block needle tip (SonoPlex Stim cannula 22-G × 80 mm; Pajunk<sup>®</sup>, GmbH, Geisingen, Germany) was positioned just caudal or lateral to the suprascapular nerve. Correct identification of the nerve, caudal to the omohyoid muscle, was confirmed by nerve stimulation (Stimuplex<sup>®</sup> HNS12; B.Braun, Melsungen, Germany), eliciting palpable contractions of the infra- and supraspinatus muscles. We aimed to surround the nerve with 4 ml of the study fluid (ropivacaine or saline), if necessary by repositioning the needle (Video S2). The needle tip position relative to the suprascapular nerve was monitored by ultrasound, nerve stimulation and measurement of the injection pressure (B-Smart<sup>™</sup>; Concert Medical LLC, Norwell, MA, USA). Motor response at a current of < 0.5 mA, 0.1 ms or injection pressure ≥ 103 kPa (15 psi) necessitated a small retraction of the needle. All patients subsequently received ultrasound-guided lateral sagittal infraclavicular block as described previously [1].

We recorded the sensory-motor status of the upper limb and wrist angle before the blocks (baseline), 15 min, 30 min and 60 min after the blocks, and then before the start of surgery. An electronic water level apparatus (Limit; Luna AB, Alingsås, Sweden) was used to measure wrist angle. The measurement device was positioned dorsally on the wrist, between the styloid processes of the radius and the ulna. The patient was placed supine on a horizontal table and the upper limb fully extended in 75° abduction, whereas the hand was voluntarily and maximally pronated. The wrist angle was the angle between the table plane (at 0°) and the plane contacting the dorsal aspect of the wrist at the interstyloid level, and was recorded as the mean of three measurements.

We performed sensory testing of all nerves distal to the elbow and the axillary nerve with ice cubes in a glove using the following scale: 3 = normal cold feeling; 2 = reduced cold feeling (hypoalgesia); 1 = no cold feeling, but feels touch (analgesia); and 0 = no cold or touch feeling (anaesthesia). Muscle strength was assessed using a modified five-point scale [6] (Table 1). Suprascapular nerve power was tested by lateral rotation of the humerus against manual resistance, while the arm was adducted and the elbow flexed at 90°. The other motor nerves tested were the axillary, musculocutaneous, radial, median and ulnar.

**Table 1** Modified Medical Research Council scale of muscle power.

5	Normal power
4+	Active movement against gravity and resistance (> 50% of normal power)
4–	Active movement against gravity and resistance (< 50% of normal power)
3	Active movement against gravity
2	Active movement with gravity eliminated
1	Flicker or trace contraction
0	No contraction

The suprascapular nerve block was judged as successful if the motor score was ≤ 2 after 30 min and infraclavicular brachial plexus block successful if the sensory score for each of the five nerves distal to the elbow was 0 or 1 [1, 2]. Patients with an incomplete infraclavicular block received supplementary peripheral nerve block(s), as indicated by the site of surgery. The surgeons assessed the intra-operative position of the hand/forearm as either ‘good’ or ‘poor’ without knowing the group allocation of the patients.

We recorded the incidence of adverse events including paraesthesia, vessel puncture, systemic local anaesthesia toxicity and Horner’s syndrome. Respiratory function was assessed clinically and by a chest radiograph taken approximately 75 min after block completion. All patients were followed up either in the surgical outpatient clinic or by a telephone call, 1–2 weeks after the operation.

The study was powered to show a difference in wrist angulation 30 min after completion of the two nerve blocks. Clinical experience indicated that surgeons would not be satisfied with a wrist angle greater than 20°. We assumed the suprascapular group would achieve a wrist angle of ≤ 20° and performed a power calculation anticipating a minimal angle difference of 20° between the suprascapular and the control group using a standard deviation equal to 5° and 10° in the groups, respectively. The study only needed five patients in each group when using a significance level of 5% and a power of 80%. However, the number of participants was increased to 30 patients to ensure sufficient power to detect a smaller group difference and to account for dropouts. With 11 patients in each group, the study had 80% power to detect a difference

of approximately 10°. Ordinary linear regression models were used to assess changes in wrist angulation from baseline to follow-up measurement at 30 min. Linear mixed models were used to test for differences in wrist angulation from baseline over four repeated measures (15 min, 30 min, 60 min and before surgery in theatre). An unstructured covariance matrix was specified to control for dependencies between repeated observations. In separate models, two-way interactions were assessed by including cross-product terms between group and indicator variables of time. In all regression models with wrist angulation as the dependent variable, we adjusted for the baseline value of angle. Residual analyses verified the model assumptions. The Mann-Whitney U-test was used to assess differences in lateral rotation force of the humerus at each time point and the surgeons' evaluation of the hand position was analysed using the Fischer's exact test. In separate analyses, we used the intention-to-treat principle and assessed group differences for all 30 patients who were randomly allocated, without exclusion of patients with unsuccessful suprascapular and/or lateral sagittal infraclavicular brachial plexus blocks. Statistical analyses were performed using the Statistical Package for Social Sciences (SPSS) program version 21.0 for Windows (SPSS Inc., Chicago, IL, USA).

## Results

We screened 31 patients and recruited 30 to this study. One of the screened patients was not studied because she was not able to pronate the hand  $\leq 15^\circ$  (Fig. 1). Baseline patient characteristics were similar in both groups (Table 2).

The suprascapular nerve was identified in all patients using ultrasound and confirmed by nerve stimulation. The nerve was successfully blocked in 12 of 15 patients in the suprascapular group and in 2 of 15 patients in the control group. Medial spread of local anaesthetic to the lateral aspect of the plexus was noted in three patients from the suprascapular group and in four patients from the control group. Suprascapular nerve block characteristics are presented in Table 3.

The infraclavicular brachial plexus block was successful in 24 of 30 patients. For the subsequent main

analyses of the primary and secondary aims, we did not include patients with a failed suprascapular nerve block and/or lateral sagittal infraclavicular brachial plexus block.

When only considering the patients with successful nerve blocks, we found a significantly lower mean (SD) wrist angulation at 30 min in the suprascapular group compared with the control group, when adjusted for baseline (33 (27) vs. 61 (44) degrees;  $p = 0.018$ ) (Fig. 2a). Mean wrist angulation adjusted for baseline was also lower in the suprascapular group over all repeated time points (Fig 2a;  $p = 0.014$ ). The difference between the two groups did not vary over time as the test of interaction between time and group was not significant ( $p = 0.23$ ). However, when all patients were considered in the intention-to-treat analysis, the observed reduction in wrist angulation at 30 min in the suprascapular group was no longer significant (35 (28) vs. 52 (41);  $p = 0.12$ ), nor was the test for group difference over all repeated time points ( $p = 0.23$ ) (Fig. 2b).

As shown in Table 4, we found a reduction in power of lateral rotation of the humerus in the suprascapular group at 30 min ( $p < 0.0001$ ); this difference was also significant for other time points ( $p < 0.001$ ). Muscle force decreased more rapidly in the suprascapular group compared with the control group. The intention-to-treat analysis showed a similar reduction in power of lateral rotation of the humerus in the suprascapular group at 30 min ( $p < 0.001$ ) and at all time points thereafter ( $p \leq 0.002$ ) (Table 5).

The surgeons' assessment of the hand/forearm position was rated as good for all 11 patients in the suprascapular group. This was in contrast to the control group, where only 6 of 11 achieved a good position ( $p = 0.04$ ). In the intention-to-treat analysis, more patients in the suprascapular group were rated by the surgeon as having a good hand position (15/15 vs. 10/15, respectively;  $p = 0.04$ ).

None of the patients in either group required supplementary peripheral nerve blocks for surgery. Interestingly, the axillary nerve was well blocked in all patients. Thirty minutes after the blocks and in the operating theatre, all patients demonstrated anaesthesia or analgesia in this nerve's innervation area and were paralytic for elevation of the upper limb in the

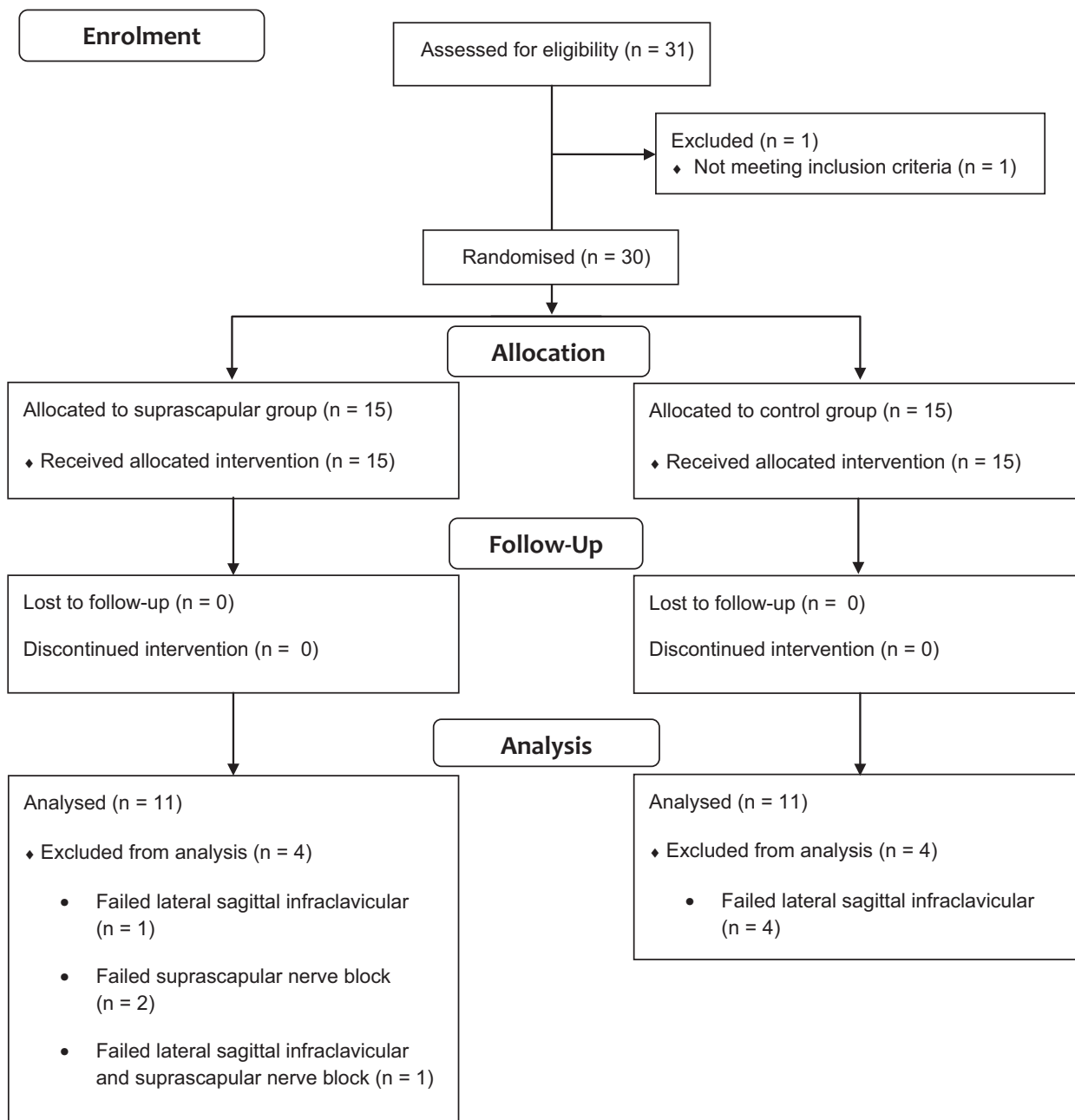


Figure 1 CONSORT flow diagram.

parasagittal plane (Fig. S1). Regarding other terminal nerves potentially allowing supination, in both groups the musculocutaneous (Fig. S2) and the radial (Fig. S3) nerves had reductions in power (power score  $\leq 2$ ) when tested at 30 min and in theatre.

No patient demonstrated signs of systemic local anaesthetic toxicity. In the suprascapular group, there was one vascular puncture of the axillary artery and transient paraesthesia in two other patients. None of

the patients complained of respiratory distress. Chest radiograph did not demonstrate pneumothorax or signs of phrenic nerve palsy in any patient. Three patients in the control group demonstrated temporary Horner’s syndrome. All patients except one expressed a wish for a similar anaesthetic technique should they require similar surgery. Follow-up by the surgeons revealed no patients with sensory/motor deficit or soft tissue injury.

**Table 2** Characteristics of study patients scheduled for dorsal hand surgery. Values are mean (SD) or number.

	Suprascapular group n = 15	Control group n = 15
Age	52.9 (14.5)	45.2 (17.4)
Male sex	6	5
BMI; kg.m <sup>-2</sup>	26.7 (3.0)	25.2 (4.1)
Left handed	9	9

All patients received a lateral sagittal infraclavicular brachial plexus block. Patients in the suprascapular group received an additional suprascapular nerve block, whereas the control group patients had a sham suprascapular nerve block performed.

**Table 3** Suprascapular nerve block characteristics. Values are median (IQR [range]).

Suprascapular nerve diameter; mm	1.3 (1.2–1.4 [1.0–1.7])
Distance from the suprascapular nerve to the brachial plexus*; mm	6.5 (5.0–10.5 [2.0–17.0])
Depth from the skin to the suprascapular nerve†; mm	10.5 (9.0–14.0 [5.0–17.0])
Nerve stimulator current response; mA	0.5 (0.5–0.7 [0.3–1.7])
Pre-scanning time‡; min	5.6 (4.7–6.8 [3.7–8.2])
Block performance time§; min	5.0 (3.5–6.0 [2.6–13.6])
Time from end of local anaesthetic injection until start of surgery; h	2.3 (2.0–3.2 [1.7–4.4])

\*Distance from the most medial aspect of the suprascapular nerve to the most lateral aspect of the brachial plexus.

†Measured to the closest aspect of the suprascapular nerve.

‡Pre-scan time was the time from the first ultrasound view until insertion of the needle.

§Block performance time was the time from first insertion to final withdrawal of the block needle.

## Discussion

When considering only those patients with successful nerve blocks, our study confirmed the surgical observation that lateral sagittal infraclavicular brachial plexus blockade is likely to cause supination, as demonstrated by the increase in wrist angulation (supination) in the control group. The novel combination of a suprascapular nerve block and infraclavicular brachial plexus block reduced the amount of supination allowing a superior intra-operative hand position. However, in both groups in this study, there was a large amount of variability in wrist angulation after the nerve blocks. In

**Table 4** Power for lateral rotation of the humerus at different time points for patients in the suprascapular and the control groups who had successful nerve blocks. Values are median (IQR [range]).

	Suprascapular group	Control group
Baseline	5 (5–5 [5–5])*	5 (5–5 [5–5])*
15 min	2 (1–4 [1–4])	4.5 (4–4.5 [4–5])
30 min	1 (0–1 [0–2])	4 (4–4.5 [1–5])
60 min	0 (0–0 [0–1])	4 (4–4.5 [0–4.5])
Theatre	0 (0–0 [0–1])	4 (2–4 [0–4.5])

All patients received a lateral sagittal infraclavicular brachial plexus block. Patients in the suprascapular group received an additional suprascapular nerve block, whereas the control group patients had a sham suprascapular nerve block performed.

\*All patients had a power score of 5 at baseline before performance of the block (s).

**Table 5** Power for lateral rotation of the humerus at different time points for all patients in the suprascapular and the control groups. Values are median (IQR [range]).

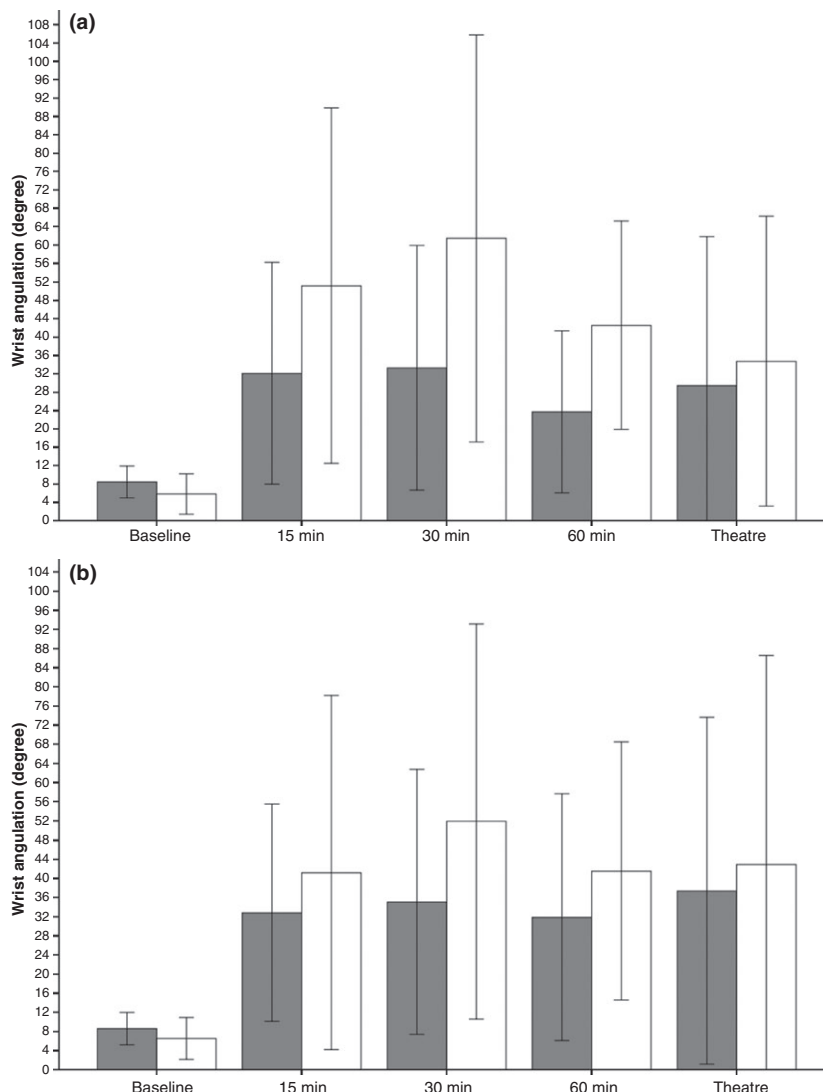
	Suprascapular group	Control group
Baseline	5 (5–5 [5–5])*	5 (5–5 [5–5])*
15 min	4 (1–4 [1–4.5])	4.5 (4–4.5 [4–5])
30 min	1 (0–2 [0–4])	4 (4–4.5 [0–5])
60 min	0 (0–1 [0–4])	4 (4–4.5 [0–4.5])
Theatre	0 (0–0 [0–4])	4 (2–4.5 [0–4.5])

All patients received a lateral sagittal infraclavicular brachial plexus block. Patients in the suprascapular group received an additional suprascapular nerve block, whereas the control group patients had a sham suprascapular nerve block performed.

\*All patients had a power score of 5 at baseline before performance of the block (s).

an attempt to explain this, it is necessary to review some functional shoulder anatomy.

The two major muscular forces that determine the position of the scapula in the transverse plane are serratus anterior (innervated by the long thoracic nerve) and pectoralis minor (innervated by lateral and medial pectoral nerves). These muscles pull the scapula anteriorly along the rib cage, whereas trapezius (innervated by the accessory nerve) and rhomboid major and minor (innervated by the dorsal scapular nerve) pull it posteromedially. Infraclavicular brachial plexus blocks, which target the cords of the brachial plexus, are likely to have an effect on the lateral and medial pectoral nerves, as they originate from these structures. In some



**Figure 2** Mean wrist angulation (degrees) at different time points: (a) patients with successful blocks (suprascapular group (filled bars, n = 11) and control group (open bars, n = 11)) and (b) all patients, including those with a failed suprascapular nerve block or lateral sagittal infraclavicular block (suprascapular group (filled bars, n = 15) and control group (open bars, n = 15)). Error bars indicate 1 SD. In the first group, the patients received both a suprascapular nerve block and a lateral sagittal infraclavicular block. In the control group, the patients had a sham suprascapular nerve block and a lateral sagittal infraclavicular block. Baseline indicates status before the nerve blocks.

patients, the local anaesthetic theoretically may also reach the long thoracic nerve, but is unlikely to reach the more distant dorsal scapular and accessory nerves. This could result in posteromedial displacement of the scapula (which is associated with lateral orientation of the glenoid cavity and lateral rotation of the humerus/supination of the forearm and hand when the elbow is extended) and might explain why some of the patients in the suprascapular group developed a large degree of supination.

Thirty minutes after the nerve blocks, 7 of 11 patients in the suprascapular group had wrist angles above 20° (Table S1a and b). All of them obtained a ‘good’ rating by the surgeons for their intra-operative hand/forearm position. This can be explained by the fact that the surgeons’ assessment of hand position was undertaken sometime after performance of the nerve blocks (median 2.3 h). By that time, wrist angulation had improved and only three patients had angles above 20°. Moreover, all 11 patients had

become paralytic for lateral rotation of the humerus. When the surgeons pronated the hands of these patients, we assume that they sensed no or minimal muscular resistance and this probably facilitated hand positioning and favoured a positive score. The delay in starting of surgery was due to two factors. First, we were interested in the effect of the suprascapular nerve block and lateral sagittal infraclavicular brachial plexus block on supination over different time periods up to 60 min after nerve blockade. Second, our method for the suprascapular nerve block lacked documentation as to whether it affected the phrenic nerve. We, therefore, took a chest radiograph as soon as possible after the measurements at 60 min. The combination of these two variables resulted in a marked delay in starting surgery.

The results from the intention-to-treat analyses showed no differences in wrist angulation between the groups. However, the power of lateral rotation of the humerus and surgeons' assessment of the hand/forearm position were significantly different between the two groups. We only included patients with successful blocks in the statistical analyses of the primary and secondary outcome measures. This was done to detect group differences that could not be explained by unsuccessful nerve blocks. Clinicians should be aware of this difference when they consider whether this novel nerve block combination would be a useful addition to their clinical practice.

To block the suprascapular nerve, we chose the novel ultrasound-guided method described by Siegenthaler et al. with an anterior supraclavicular approach [5]. Their study was based on investigations using both cadavers and volunteers, but needles were only inserted in the cadavers. They found that their method offered easier identification of the nerve than the classical posterior approach [7, 8]. Before the start of our study, there was only one single case study published in which a method very similar to that of Siegenthaler et al. had been applied [9]. After completion of our study, Rothe et al. published encouraging results in 12 volunteers who, in the sitting position, received suprascapular blocks using 1 ml lidocaine ( $20 \text{ mg.ml}^{-1}$ ) [10]. Their blocks were successful in 8 of 11 attempted cases. The minimum effective dose/volume for successful suprascapular nerve block is currently not known.

We chose 4 ml ropivacaine ( $5.0 \text{ mg.ml}^{-1}$ ), which may be larger than required [10]. However, the higher volume was selected to minimise the risk of a failed suprascapular nerve block. Nevertheless, three of 15 patients had failed suprascapular nerve blocks in spite of the nerve being completely surrounded by local anaesthetic in all patients. Interestingly, in some patients, we observed that the suprascapular nerve was surrounded by a hyperechoic, 1- to 2-mm thick ring. This is most likely to represent dense perineural connective tissue, which would be expected to impede local anaesthetic penetration to the nerve. Unfortunately, we did not systematically record the presence of such a ring, so whether it is causally related to block failure remains an open question. Regarding the lateral sagittal infraclavicular brachial plexus block, we surprisingly experienced several failures. Our dose was 31 ml ropivacaine ( $7.5 \text{ mg.ml}^{-1}$ ), which is in accordance with our recently published study on minimum effective volume [1]. The high number of failures questions if that volume is too low and underlines the uncertainty in making estimates of the true minimum effective volume [11].

Two limitations of our study should be discussed. First, supination was not measured between performance of the two nerve blocks. Therefore, we could not determine the precise degree to which a suprascapular nerve block reduces the supination associated with infraclavicular brachial plexus blockade. Second, data related to our primary (wrist angulation) and secondary (hand position) aim were not obtained at the same time point after the nerve blocks. However, we consider wrist angulation and power of lateral rotation of the humerus to be the main determinants of optimal hand/forearm positioning for dorsal hand surgery.

This study also demonstrates that our block combination has a satisfactory effect on the two most important nerves of the shoulder, namely the suprascapular axillary nerves. We, therefore, believe that the novel combination of suprascapular nerve block and infraclavicular brachial plexus block should be assessed for use as an analgesic technique for shoulder surgery and shoulder pain states, as a potentially useful peripheral alternative to the interscalene brachial plexus block [12, 13].

In conclusion, the addition of a successful suprascapular block to a successful lateral sagittal infraclavicular brachial plexus block results in less wrist supination and an improved hand/forearm position in patients scheduled for dorsal hand surgery.

## Acknowledgements

The trial was registered at [www.clinicaltrials.gov](http://www.clinicaltrials.gov) (NCT02035774) on 1 April 2016. Per Brodal, Professor of Anatomy, Department of Anatomy, University of Oslo, Norway and Jan Due, Associated Professor of Surgery, Department of Urology and Endocrinology, University Hospital of North Norway contributed substantially to this article with stimulating discussions and suggestions. Frode Abrahamsen, web designer and Jan Fredrik Franzen, photographer, University Hospital of North Norway edited video files and took photographs during this study. Simon Davis, Senior Lecturer, University of Tromsø, The Arctic University of Norway edited the English language.

## Competing interests

This study received departmental funding from the Department of Anaesthesiology, University Hospital of North Norway. Secma AS, Trondheim, Norway provided the ultrasound unit. Concert Medical LLC provided the B-smart pressure manometers. No competing interests declared.

## References

- Flohr-Madsen S, Ytrebo LM, Kregnes S, Wilsgaard T, Klaastad Ø. Minimum effective volume of ropivacaine 7.5 mg/ml for an ultrasound-guided infraclavicular brachial plexus block. *Acta Anaesthesiologica Scandinavica* 2013; **57**: 495–501.
- Sauter AR, Dodgson MS, Stubhaug A, Halstensen AM, Klaastad Ø. Electrical nerve stimulation or ultrasound guidance for lateral sagittal infraclavicular blocks: a randomized, controlled, observer-blinded, comparative study. *Anesthesia and Analgesia* 2008; **106**: 1910–5.
- Waldeyer A. *Anatomie des menschen*. Berlin: Walter de Gruyter & Co, 1965.
- Woodburne R. *Essentials of Human Anatomy*, 6th edn. Oxford: Oxford University Press, 1978.
- Siegenthaler A, Moriggl B, Mlekusch S, et al. Ultrasound-guided suprascapular nerve block, description of a novel supraclavicular approach. *Regional Anesthesia and Pain Medicine* 2012; **37**: 325–8.
- Paternostro-Sluga T, Grim-Stieger M, Posch M, et al. Reliability and validity of the Medical Research Council (MRC) scale and a modified scale for testing muscle strength in patients with radial palsy. *Journal of Rehabilitation Medicine* 2008; **40**: 665–71.
- Harmon D, Hearty C. Ultrasound-guided suprascapular nerve block technique. *Pain Physician* 2007; **10**: 743–6.
- Peng PW, Wiley MJ, Liang J, Bellingham GA. Ultrasound-guided suprascapular nerve block: a correlation with fluoroscopic and cadaveric findings. *Canadian Journal of Anesthesia* 2010; **57**: 143–8.
- Hackworth RJ. A new and simplified approach to target the suprascapular nerve with ultrasound. *Journal of Clinical Anesthesia* 2013; **25**: 347–8.
- Rothe C, Steen-Hansen C, Lund J, Jenstrup MT, Lange KH. Ultrasound-guided block of the suprascapular nerve – a volunteer study of a new proximal approach. *Acta Anaesthesiologica Scandinavica* 2014; **58**: 1228–32.
- Saranteas T, Finlayson RJ, Tran DQ. Dose-finding methodology for peripheral nerve blocks. *Regional Anesthesia and Pain Medicine* 2014; **39**: 550–5.
- Liu SS, Gordon MA, Shaw PM, Wilfred S, Shetty T, Yadeau JT. A prospective clinical registry of ultrasound-guided regional anesthesia for ambulatory shoulder surgery. *Anesthesia and Analgesia* 2010; **111**: 617–23.
- Price DJ. The shoulder block: a new alternative to interscalene brachial plexus blockade for the control of postoperative shoulder pain. *Anaesthesia and Intensive Care* 2007; **35**: 575–81.

## Supporting Information

Additional supporting information may be found in the online version of this article:

**Figure S1.** Axillary nerve function. The axillary nerve was tested by elevation of extended arm in the parasagittal plane. Suprascapular group (filled bars, n = 11) and control group (open bars, n = 11). Error bars indicate 1 SD. In the first group, the patients received both a suprascapular nerve block and a lateral sagittal infraclavicular block. In the control group, the patients had a sham suprascapular nerve block and a lateral sagittal infraclavicular block. Baseline indicates status before the blocks. We applied the modified Medical Research Council scale to assess muscle power (Table 1). Normal muscle power = 5 and no muscle contraction = 0.

**Figure S2.** Musculocutaneous nerve function. The musculocutaneous nerve was tested by flexion of the elbow, while avoiding pronation of the forearm. Suprascapular group (filled bars, n = 11) and control group (open bars, n = 11). Error bars indicate 1 SD. In the first group, the patients received both a suprascapular nerve block and a lateral sagittal infraclavicular block. In the control group, the patients had a sham suprascapular nerve block and a lateral sagittal infraclavicular block. Baseline indicates status before the blocks. We applied the modified Medical Research

Council scale to assess muscle power (Table 1). Normal muscle power = 5 and no muscle contraction = 0.

**Figure S3.** Radial nerve function. The radial nerve was tested by extension of the wrist. Suprascapular group (filled bars, n = 11) and control group (open bars, n = 11). Error bars indicate 1 SD. In the first group, the patients received both a suprascapular nerve block and a lateral sagittal infraclavicular block. In the control group, the patients had a sham suprascapular nerve block and a lateral sagittal infraclavicular block. Baseline indicates status before the blocks. We applied the modified Medical Research Council scale to assess muscle power (Table 1). Normal muscle power = 5 and no muscle contraction = 0.

**Table S1.** Wrist angulation, power for lateral rotation of the humerus and surgical assessment of intra-

operative hand position for all patients in the suprascapular (a) and control (b) groups.

**Video 1.** For ultrasound guidance, we used the SonoSite Edge unit (SonoSite, Inc., Bothell, WA, USA) with a 50-mm linear array transducer (Hfl50x, 15–6 MHz). It was initially positioned immediately cranial and parallel to the middle of the clavicle to provide a cross-sectional view of the subclavian artery and the brachial plexus. Maintaining a short-axis view of the brachial plexus, the transducer was moved cranially to identify the superior trunk. By slowly returning the transducer to the initial position, we could observe the suprascapular nerve diverging from its trunk.

**Video 2.** We aimed to surround the suprascapular nerve with 4 ml of the study fluid (ropivacaine or saline).



# A novel combination of peripheral nerve blocks for arthroscopic shoulder surgery

D. Musso<sup>1</sup>, S. Flohr-Madsen<sup>2</sup>, K. Meknas<sup>3</sup>, T. Wilsgaard<sup>4</sup>, L. M. Ytrebø<sup>1</sup>  and Ø. Klaastad<sup>1</sup>

<sup>1</sup>Department of Anesthesiology, University Hospital of North Norway and UiT-The Arctic University of Norway, Tromsø, Norway

<sup>2</sup>Department of Anesthesiology, Sykehuset Sørlandet, Kristiansand, Norway

<sup>3</sup>Department of Orthopedic Surgery, University Hospital of North Norway and UiT-The Arctic University of Norway, Tromsø, Norway

<sup>4</sup>Department of Community Medicine, UiT-The Arctic University of Norway, Tromsø, Norway

## Correspondence

L. M. Ytrebø, Department of Anesthesiology, University Hospital of North Norway, N-9038 Tromsø, Norway  
E-mail: lars.marius.ytrebo@unn.no

## Conflict of interest

Concert Medical LLC provided the B-smart pressure manometers.

Submitted 2 May 2017; accepted 2 July 2017; submission 27 February 2017.

## Citation

Musso D, Flohr-Madsen S, Meknas K, Wilsgaard T, Ytrebø LM, Klaastad Ø. A novel combination of peripheral nerve blocks for arthroscopic shoulder surgery. *Acta Anaesthesiologica Scandinavica* 2017

doi: 10.1111/aas.12948

**Background:** Interscalene brachial plexus block is currently the gold standard for intra- and post-operative pain management for patients undergoing arthroscopic shoulder surgery. However, it is associated with block related complications, of which effect on the phrenic nerve have been of most interest. Side effects caused by general anesthesia, when this is required, are also a concern. We hypothesized that the combination of superficial cervical plexus block, suprascapular nerve block, and infraclavicular brachial plexus block would provide a good alternative to interscalene block and general anesthesia.

**Methods:** Twenty adult patients scheduled for arthroscopic shoulder surgery received a combination of superficial cervical plexus block (5 ml ropivacaine 0.5%), suprascapular nerve block (4 ml ropivacaine 0.5%), and lateral sagittal infraclavicular block (31 ml ropivacaine 0.75%). The primary aim was to find the proportion of patients who could be operated under light propofol sedation, without the need for opioids or artificial airway. Secondary aims were patients' satisfaction and surgeons' judgment of the operating conditions.

**Results:** Nineteen of twenty patients (95% CI: 85–100) underwent arthroscopic shoulder surgery with light propofol sedation, but without opioids or artificial airway. The excluded patient was not comfortable in the beach chair position and therefore received general anesthesia. All patients were satisfied with the treatment on follow-up interviews. The surgeons rated the operating conditions as good for all patients.

**Conclusion:** The novel combination of a superficial cervical plexus block, a suprascapular nerve block, and an infraclavicular nerve block provides an alternative anesthetic modality for arthroscopic shoulder surgery.

## Editorial comment

In this feasibility study including 20 patients, the authors present a novel combination of a superficial cervical plexus block, suprascapular nerve block, and infraclavicular nerve block for arthroscopic shoulder surgery. Results are encouraging, but need confirmation in large scale studies.

Interscalene brachial plexus block remains the gold standard for intraoperative and post-operative pain management in patients undergoing arthroscopic shoulder surgery. In expert hands, it has a very high success rate,<sup>1</sup> but may cause a wide spectrum of complications and undesired side effects.<sup>2–6</sup> The risk of neurological complications, particularly concerning the phrenic nerve,<sup>7,8</sup> has encouraged the development of alternative peripheral block methods for arthroscopic shoulder surgery.<sup>9</sup>

The shoulder joint is innervated by a few nerves: subscapular, axillary, lateral pectoral, and suprascapular nerve. The subscapular, axillary, and lateral pectoral nerve can be blocked with the infraclavicular block, while the suprascapular nerve must be blocked separately. Two nerves provide the cutaneous innervation of the shoulder: the supraclavicular and the axillary nerves. The supraclavicular nerves are not derived from the brachial plexus, but arise from the superficial cervical plexus.<sup>9–11</sup> Novel block methods should block all these nerves in order to provide effective intraoperative anesthesia and post-operative analgesia.

Several alternatives to the interscalene block have been proposed in order to avoid the effect on the diaphragmatic function, yet many of them require further confirmatory trials. In the last years some authors have proposed a C7 root block,<sup>12,13</sup> an alternative supraclavicular block limited to the distal upper extremity,<sup>14</sup> and an axillary-suprascapular block.<sup>15</sup>

We hypothesized that a combination of superficial cervical plexus block, suprascapular nerve block, and lateral sagittal infraclavicular brachial plexus block would provide intraoperative anesthesia and post-operative analgesia for patients undergoing arthroscopic shoulder surgery. To test this hypothesis we performed a feasibility study in 20 patients scheduled for arthroscopic shoulder surgery. The primary aim was the proportion of patients who could be operated under light propofol sedation, but without the need for opioids or artificial airway. Secondary aims were patients' satisfaction and surgeons' judgment of the operating conditions.

## Methods

The study was approved by the Institutional Board at the University Hospital of North Norway (registration number 0472) and registered at [www.clinicaltrials.gov](http://www.clinicaltrials.gov) (NCT02809144). The trial was performed at the University Hospital of North Norway (Tromsø and Narvik) from April to November 2016, in accordance with the Helsinki Declaration. Written informed consent was obtained from patients scheduled for arthroscopic shoulder surgery using the following inclusion criteria: age 18–70 years, BMI 20–35 kg/m<sup>2</sup> and ASA physical status 1–3. Exclusion criteria included: pregnancy, coagulation disorders, allergy to local anesthetics, atrioventricular block, peripheral neuropathy and use of anticoagulation drugs other than acetylsalicylic acid or dipyridamol.

All blocks were performed by DM with assistance from LMY. For the two-first blocks (the superficial cervical and suprascapular nerve blocks) the patients were in semilateral position with slightly elevated upper body. Subsequently the patients were supine for the infraclavicular block. All blocks were ultrasound-guided, using either a SonoSite Edge unit or a SonoSite M-Turbo (SonoSite, Inc., Bothell, WA, USA). A 50 mm linear array probe 6–15 MHz was applied for the superficial cervical and the suprascapular nerve blocks, while a C11x broadband curved array probe 5–8 MHz was used for the lateral sagittal infraclavicular block. For the two-first blocks, correct nerve identification by ultrasound was confirmed by nerve stimulator response (Stimuplex HNS 12, B. Braun AG, Melsungen, Germany). To reduce the risk of intraneural needle tip position, for all blocks, the relationship between needle and nerve was carefully observed by ultrasound. Moreover, a nerve stimulator response by a current  $\leq 0.3$  mA, 0.1 ms and 2 Hz or an injection pressure (measured by B-Smart<sup>TM</sup>; Concert Medical LLC, Norwell, MA, USA)  $\geq 103$  kPa (15 psi) defined the need for a small retraction of the needle. The initial needle insertion was counted as the first pass. An additional needle pass was defined as needle retraction of at least 10 mm prior to further needle insertion.

Standard monitoring included pulse oximetry, electrocardiogram and non-invasive blood pressure. All patients received oxygen supplementation by a nasal cannula.

### Superficial cervical plexus block

We used a slight modification of the method first described by Tran et al.<sup>16</sup> Before the insertion of the block needle, the skin was infiltrated with 1–2 ml lidocaine 10 mg/ml. The probe was placed axially, just below the midpoint of the sternocleidomastoid muscle, to visualize the intermuscular plane between the sternocleidomastoid and the scalene muscles (between the deep part of the superficial cervical fascia and the prevertebral fascia). The needle was slowly advanced from posterolateral to anteromedial in this potential space, using the in-plane technique. The patient was instructed to signal paresthesia toward the clavicle or shoulder, while receiving a current of 0.3–0.8 mA, 0.1 ms, 2 Hz. Five ml ropivacaine 0.5% was injected in the described interfascial space while trying to avoid distribution medial to the interscalene groove. Although the supraclavicular nerves can often be visualized, a systematical search for them was not done because the technique relied on injection of local anesthetic agents in the intermuscular space.

### Suprascapular nerve block

The anterior suprascapular block was first described by Siegenthaler et al.<sup>17</sup> and has since then undergone some modifications.<sup>18,19</sup> The suprascapular nerve is usually the most cranio-lateral nerve emerging from the supraclavicular plexus. Sonographically the nerve can be traced laterally in the posterior cervical triangle, deep to the omohyoid muscle, by tilting the probe incrementally steeper in the caudal direction. This ultrasonographic observation agrees with anatomical studies by Leung et al.<sup>20</sup> The local anesthetic was injected at the most lateral short-axis view of the nerve that we could obtain, with an in-plane technique, while advancing the needle from posterolateral to anteromedial. During injection we tried to avoid fluid distribution to the supraclavicular brachial plexus cluster and (more medially) to the phrenic

nerve. Electric nerve stimulation (0.3–0.8 mA, 0.1 ms, 2 Hz) served to confirm the sonographic identification of the nerve, by palpable contractions of the infra- and supraspinatus muscles. The local anesthetic dose was 4 ml ropivacaine 0.5%, as recently described by Flohr-Madsen et al.<sup>19</sup>

### Lateral sagittal infraclavicular block

A periarterial injection technique was used, slightly modified from the method described by Flohr-Madsen et al.<sup>21</sup> Usually, the dose was administered by three local anesthetic deposits. Considering the artery as a clock face with 12 o'clock ventral, the aim was to cover the artery by fluid from 3 to 11 o'clock. The needle insertion point was 0.5–1.0 cm caudal to the lower edge of the clavicle, just medial to the coracoid process. The needle was carefully advanced in the sagittal plane with the in-plane technique, between the artery and the lateral cord, tangential to the cranial aspect of the artery. The first deposit was at 6 o'clock, the second on withdrawal of the needle between 9 and 11 o'clock and the third at 3 o'clock. The latter deposit required a needle pass ventral to the artery. Total local anesthetic dose was 31 ml ropivacaine 0.75%. The volume of each injection varied depending on observed fluid distribution, but the largest volume (15–18 ml) regularly at 6 o'clock.

Total block performance time was the time from the probe was placed on the neck for the superficial cervical plexus block to final withdrawal of the block needle after the lateral sagittal infraclavicular block.

### Block assessment

Neurologic status of the upper limb and the cervical area was assessed before the blocks (baseline) and 15 and 30 min after completion of the blocks. We performed sensory testing by applying an ice cube on pre-marked points in the areas of the supraclavicular nerves, intercostobrachial, axillary, medial brachial cutaneous, musculocutaneous, medial antebrachial cutaneous, radial, median and ulnar nerves. Supraclavicular test points were at the soft spot and at the upper border of the clavicle in

the midclavicular line. The soft spot is the posterior portal used for shoulder arthroscopy. It is formed by the interval between the infraspinatus and teres minor muscles, approximately 2 cm caudal and 1 cm medial to the posterolateral tip of the acromion. The following scale was used: 3 = normal cold feeling; 2 = reduced cold feeling (hypoalgesia); 1 = no cold feeling, but feels touch (analgesia); and 0 = no cold or touch feeling (anesthesia). Muscle power was assessed using a modified seven-point scale (Table 1).<sup>22</sup> Axillary nerve block was tested by elevation of the extended upper limb in the sagittal plane. Suprascapular nerve block was tested by the force for lateral rotation of the humerus against manual resistance, while the arm was adducted and the elbow flexed at 90°. Subscapular nerve block was tested by the force for medial rotation of the humerus against manual resistance, while the arm was adducted and the elbow flexed at 90°. The other motor nerve tests were for the musculocutaneous, radial, median, and ulnar nerves.<sup>23</sup>

Block success was assessed 30 min after withdrawal of the needle upon the last of the three blocks. The superficial cervical plexus block was judged successful if the sensory score at both of its test points was 0 or 1. The suprascapular nerve block was successful if the motor score was  $\leq 2$ . The lateral sagittal infraclavicular block was successful if the axillary sensory score was 0 or 1. Patients who failed the success criteria were followed up with repeated assessments until admittance to the operation theatre. Patients # 1–7 were accepted for surgery if the sensory score was  $\leq 1$  (the supraclavicular and axillary nerves) and the motor test score was  $\leq 2$

(the suprascapular nerve). Patients # 8–20 were accepted for surgery if the sensory score was  $\leq 1$  (the supraclavicular and axillary nerves) and the motor test score was  $\leq 4$ – (the suprascapular nerve).

We recorded the incidence of adverse events including paresthesia, vessel puncture, systemic local anesthesia toxicity, Horner's syndrome, dyspnea, hoarseness, and dysphagia. To detect pneumothorax, ultrasound was used within 15 min after completed procedure.

### Intraoperative treatment

All patients were offered propofol sedation to maintain a score between  $-2$  and  $0$  on the Richmond Agitation and Sedation Scale. The protocol required that other sedatives or analgesics were not administered.

### Post-operative assessment

All patients were interviewed in the recovery room and by phone approximately 24 h after the surgery was completed. In the recovery room, post-operative nausea and vomiting (PONV), pain at rest (numerical rating scale, 1–10), medication, signs of Horner's syndrome, hoarseness, dyspnea, or dysphagia were recorded. The same questions were repeated on day one. Additionally, we asked about time to pain debut, average and maximum pain scores at rest (numerical rating scale, 1–10) and patients' total intake of analgesics. Analgesics were converted to oral morphine equivalents.

Patients' overall satisfaction score was assessed by asking them, both in the recovery room and during the follow-up telephone call, if they would like to receive the same type of anesthetic technique for a similar operation in the future. Surgeons' judgement of the operative conditions was given by the operator in the recovery room, immediately after surgery.

A priori, we assumed a block success rate of 90% with a confidence of interval of  $\pm 13\%$ . This would require a total number of 20 patients included. Descriptive characteristics are presented as mean (standard deviation), median (interquartile range and range), or number, as appropriate. The primary aim is presented as

**Table 1** Modified Medical Research Council scale of muscle power.

5	Normal power
4+	Active movement against gravity and resistance (> 50% of normal power)
4–	Active movement against gravity and resistance (< 50% of normal power)
3	Active movement against gravity
2	Active movement with gravity eliminated
1	Flicker or trace contraction
0	No contraction

proportion with 95% confidence interval. Analyses were performed using the Statistical Package for Social Sciences (SPSS) program version 23.0 for Windows (SPSS Inc., Chicago, IL, USA).

## Results

Twenty-six consecutive patients scheduled for arthroscopic shoulder surgery were screened and 20 patients fulfilled the inclusion criteria. Patient characteristics are presented in Table 2.

Patient flow chart is presented in Fig. 1. One patient (#5) had successful blocks, but felt uneasy in the beach chair position. After starting light propofol sedation, she became restless and therefore received general anesthesia. The other 19 out of 20 patients (95% CI: 85–100) underwent arthroscopic shoulder surgery with light propofol sedation, but without any need for opioids or artificial airway. Propofol dose given was 1.4 (0.4–2.6 [0.0–3.4]), median (IQR [range]) mg/kg/t. Two patients reported slight discomfort intraoperatively (numerical rating scale 1–2) located at the posterior portal (soft spot). Both were offered analgesics, but refused. None of the patients required additional local anesthetic.

Four patients did not fulfill the block success criteria at 30 min, which resulted in a block success rate of 80%. One patient (#7) failed the midclavicular superficial cervical plexus block test at 30 min, but met the success criteria 10 min later. Three patients (#8, #9, and #20) failed the SSN test. Patient #20 and patient #9

met the success criteria 45 and 90 min after the last block, respectively.

Patient #8 retained suprascapular nerve mediated muscle power score 4– up to the time of surgery. In spite of this suboptimal score, we decided to proceed to surgery. The precondition was, by the slightest intraoperative pain, to convert to general anesthesia. The patient did not experience pain during surgery and received only propofol according to the protocol.

Summary data of block performance of the three blocks are presented in Table 3. None of the patients showed sonographic signs of pneumothorax. Total block performance time was 21.8 (20.4–26.7 [15.9–34.5]), median (IQR [range]) minutes. Time from end of local anesthetic injection until start of surgery was 118 (92–150 [71–200]), median (IQR [range]) minutes. Tables 4 and 5 show the individual sensory-motor status of all patients 15 and 30 min after the blocks.

The duration of surgery was 49 (24–63 [18–85]), median (IQR [range]) minutes. Surgeons were satisfied with the working conditions in 19 of 20 patients (all except patient #5) and would recommend this novel block combination to all new patients scheduled for arthroscopic shoulder surgery.

In the post-anesthesia care unit (PACU) none of the patients suffered from nausea/vomiting, dyspnea, hoarseness, or dysphagia. One patient demonstrated temporary Horner's syndrome and another patient reported a pain score of 2 (numeric rating scale 0–10), while the others were pain free. No drugs were required. Accordingly, in the PACU all the patients were very satisfied with the regional anesthesia. Furthermore, all of them wished to receive the same regional anesthesia, should they require the same type of surgery in the future.

Patient #3 was excluded from post-operative day one data analyses because of protocol violation. This patient was given 16 mg dexamethasone i.v. intraoperatively. During the telephone interview on the first post-operative day, no patient reported PONV, dysphagia, dyspnea, or hoarseness. Time to pain debut was 12.5 (11.7–14.8 [7.6–15.6]), median (IQR [range]) hours. Average pain score at rest was 0 (0–2.3 [0–6]), median (IQR [range]). Maximum pain score was 5 (3.5–8.5 [0–10]), median (IQR [range]).

**Table 2** Characteristics of study patients scheduled for arthroscopic shoulder surgery ( $n = 19$ ).

Age (yrs)	55.7 (11.9)
Gender (male/female)	12/7
BMI; kg/m <sup>2</sup>	26.0 (3.4)
ASA physical status (I/II/III)	6/12/1
Types of surgery (acromioplasty/supraspinatus suture/intraarticular surgery)	9/6/4
Side (right/left)	9/10

Mean (SD) or number ( $n$ ). Continuous variables are presented as mean (standard deviation); categorical variables are presented as counts. ASA, American Society of Anesthesiologists; BMI, mass body index.

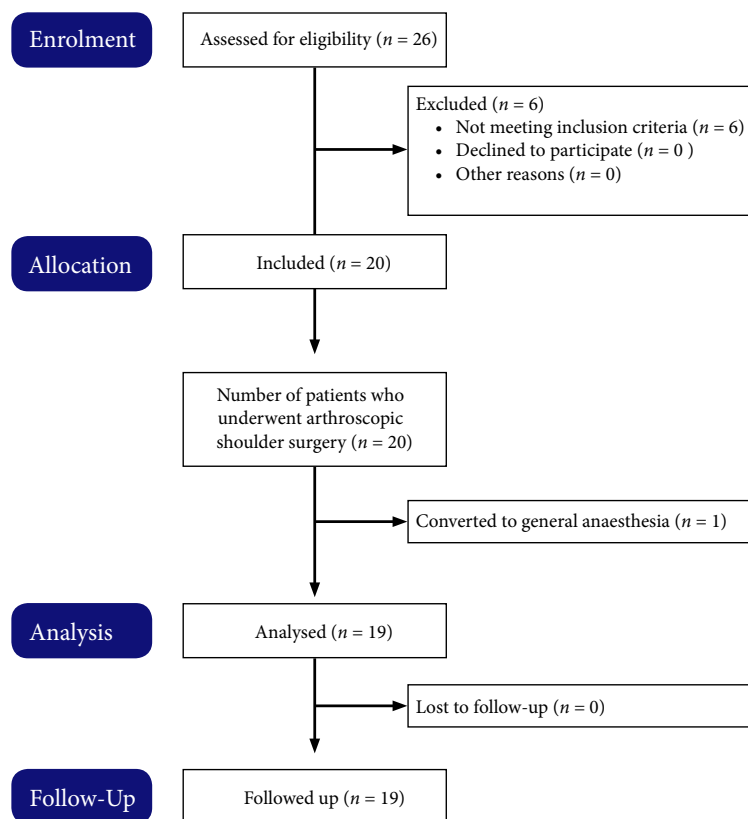


Fig. 1. CONSORT flow diagram.

**Table 3** Summary data of block performance of the three blocks (n = 19).

	SCPB	SSNB	LSIB
Performance time (min)	6.0 (5.4–8.0 [3.6–11.2])	5.0 (3.9–7.9 [2.8–14.8])	6.5 (5.5–7.1 [4.7–12.0])
Number of needle passes (n)	1 (1–1 [1–2])	1 (1–1 [1–3])	2 (2–3 [2–3])
Paresthesia (n)	1	2	1
Vascular puncture (n)	0	0	1
Local anesthetic systemic toxicity (n)	0	0	0

Values are median (IQR [range]) or number (n). SCPB, Superficial cervical plexus block; SSNB, Suprascapular nerve block; LSIB, Lateral sagittal infraclavicular block.

Analgesic consumption was 40 (30–60 [0–100]), median (IQR [range]) mg oral morphine equivalents during the first 24 h after surgery.

## Discussion

The study shows that this novel combination of peripheral nerve blocks is feasible and provides surgical anesthesia and satisfactory post-

operative analgesia in patients scheduled for arthroscopic shoulder surgery.

The superficial cervical plexus block can potentially affect the brachial plexus and the phrenic nerve<sup>24</sup> if local anesthesia penetrates the prevertebral fascia and diffuses into the interscalene groove and to the superficial aspect of the anterior scalene muscle. Nevertheless, to our knowledge there are no reports of phrenic nerve

**Table 4** Individual sensory test data 15 and 30 min after the blocks (N = 20).

Patient id	Supraclavicular nerve (soft spot)		Supraclavicular nerve (midclavicular)		Axillary nerve		Intercostobrachial nerve		Medial brachial cutaneous nerve		Musculocutaneous nerve		Medial antebrachial cutaneous nerve		Radial nerve		Median nerve		Ulnar nerve	
	15 min	30 min	15 min	30 min	15 min	30 min	15 min	30 min	15 min	30 min	15 min	30 min	15 min	30 min	15 min	30 min	15 min	30 min	15 min	30 min
1	0	0	0	0	1	0	3	1	0	0	0	0	0	0	1	0	0	0	1	1
2	0	0	1	1	1	3	3	3	2	1	0	1	0	1	1	1	0	1	1	1
3	1	0	0	0	0	2	2	2	1	1	0	0	0	0	0	0	0	0	0	0
4	0	0	0	0	0	0	0	0	0	0	0	0	0	0	2	0	1	0	0	0
5	1	1	0	1	1	3	3	3	2	2	1	0	0	0	0	0	0	0	1	0
6	0	0	0	0	0	2	1	1	0	0	0	0	0	0	0	0	0	0	0	0
7	0	0	2	2	0	0	2	2	0	0	0	0	0	0	0	0	0	0	0	0
8	0	0	0	0	1	0	3	3	2	1	1	1	1	0	1	1	1	1	1	0
9	0	0	1	1	0	0	2	2	0	0	0	1	0	1	1	1	0	2	1	0
10	0	0	0	0	1	0	3	2	0	0	1	1	0	0	1	0	0	0	1	0
11	1	1	0	0	0	0	3	2	1	0	0	1	0	0	0	0	0	0	0	0
12	0	0	0	0	1	0	1	2	0	0	1	1	1	1	1	1	2	2	2	0
13	0	0	0	0	0	0	0	0	0	0	0	0	0	0	0	0	0	0	1	0
14	0	0	1	1	1	0	1	2	1	1	1	1	1	0	1	0	1	0	2	1
15	1	0	1	1	1	0	1	0	1	0	2	0	0	0	1	0	1	0	0	0
16	0	0	0	0	0	1	1	1	1	1	1	0	0	0	0	0	0	0	0	0
17	0	0	0	0	1	0	3	2	0	0	2	1	0	0	1	0	1	0	1	0
18	0	0	0	0	0	0	3	3	2	1	1	0	0	0	0	0	0	0	1	0
19	1	0	0	0	1	0	2	2	0	0	1	0	0	0	1	1	1	0	1	0
20	0	0	0	0	1	0	0	0	1	0	0	0	0	0	1	1	1	0	0	0

Supraclavicular test points were at the soft spot and at the upper border of the clavicle in the midclavicular line. The soft spot is the posterior portal used for shoulder arthroscopy. It is formed by the interval between the infraspinatus and teres minor muscles, approximately 2 cm caudal and 1 cm medial to the posterolateral tip of the acromion. The following scale was used: 3 = normal cold feeling; 2 = reduced cold feeling (hypoalgesia); 1 = no cold feeling, but feels touch (analgesia); and 0 = no cold or touch feeling (anesthesia).

**Table 5** Individual motor power data 15 and 30 min after the blocks (N = 20).

Patient id	Axillary nerve		Suprascapular nerve		Subscapular/lateral pectoral nerve		Musculocutaneous nerve		Radial nerve (elbow)		Radial nerve (wrist)		Median nerve		Ulnar nerve	
	15 min	30 min	15 min	30 min	15 min	30 min	15 min	30 min	15 min	30 min	15 min	30 min	15 min	30 min	15 min	30 min
1	0	0	0	0	3	3	1	0	0	0	4-	3	4-	4-	4-	4-
2	2	0	1	1	3	0	4-	0	4-	2	4-	4-	1	0	4-	4-
3	0	0	2	0	0	0	0	0	0	0	0	0	0	0	0	0
4	0	0	0	0	2	0	0	0	0	0	1	0	4-	4-	1	0
5	0	0	1	0	0	0	0	0	1	0	1	0	0	0	0	0
6	0	0	0	0	0	0	1	0	0	0	0	0	0	0	0	0
7	0	0	1	0	0	0	2	0	1	0	1	0	0	0	0	0
8	2	1	4-	4-	0	0	4-	1	0	0	4-	1	4-	4-	1	1
9	2	1	4+	4-	4-	0	1	0	1	0	4-	1	1	0	4-	1
10	1	0	2	1	0	0	1	0	4-	1	4-	3	4-	0	4-	1
11	1	0	4-	1	0	0	0	0	0	0	0	0	0	0	1	0
12	4-	1	4-	1	4-	4-	4-	4-	1	1	4-	4-	4-	4-	1	1
13	0	0	1	0	0	0	3	0	1	0	1	0	0	0	1	0
14	1	0	2	0	4-	0	4-	2	1	1	4-	1	5	4-	4-	1
15	2	1	2	1	3	0	4-	4-	4-	4-	4-	4-	3	0	4-	1
16	1	0	1	0	0	0	1	0	1	0	1	0	0	0	1	0
17	1	0	2	1	4-	0	4-	2	4-	2	4-	1	0	0	4-	0
18	1	0	0	0	0	0	2	1	1	0	1	0	0	0	0	0
19	4-	1	4-	1	4-	0	4-	1	4-	1	4-	4-	1	0	4-	0
20	1	0	4+	4-	4-	4-	4-	4-	2	1	4-	4-	4-	0	4-	0

The nerve motor power was tested using the Modified Medical Research Council scale (Table 1). Axillary nerve: elevation of the extended upper limb in the sagittal plane. Suprascapular nerve: lateral rotation of the humerus. Subscapular/lateral pectoral nerve: medial rotation of the humerus. Musculocutaneous nerve: elbow flexion. Radial nerve: elbow and wrist extension. Median nerve: flexion of the second finger's distal interphalangeal joint. Ulnar nerve: finger abduction.



block associated with ultrasound-guided superficial cervical plexus block<sup>16,25</sup> and the incidence of this event is historically very low.<sup>26</sup> To reduce the risk of phrenic nerve block, we used a lower volume of local anesthetic than in the studies by Tran et al. and Gürkan et al.<sup>16,25</sup>

In our former study on supination of the hand after ultrasound-guided infraclavicular block, 15 patients received infraclavicular block alone and 15 combined infraclavicular and suprascapular nerve block.<sup>19</sup> Chest radiographs were taken approximately 75 min after the blocks. There were no signs of diaphragmatic paresis or paralysis. This may suggest that neither infraclavicular nor suprascapular block, or the combination of them, challenges the phrenic nerve. However, in a recent study of 32 patients receiving ultrasound-guided infraclavicular block, one patient developed hemidiaphragmatic paralysis and three patients hemidiaphragmatic paresis, as diagnosed by M-mode ultrasonography.<sup>27</sup> Based on data from these two studies, clinicians should be aware of the potential risk of infraclavicular block in patients with impaired respiratory function.

The suprascapular nerve seldom has sensory branches to the skin.<sup>28,29</sup> We therefore used a muscle power test to evaluate the suprascapular nerve block. Interestingly, surgery could be performed successfully even in patients with suprascapular nerve block failure after 30 min. Most remarkable was patient #8 who failed the suprascapular nerve test until start of surgery. We allowed this patient to be operated in accordance to protocol because of two considerations. First, there may be a significant disparity between motor power and sensory function after a peripheral nerve block.<sup>30</sup> Second, our success criterion may be too strict.<sup>18</sup> The patient did not experience any pain and received propofol only according to the protocol. In future studies we will consider using a more liberal success criterion (motor score  $\leq 4$ ) for the suprascapular nerve block.

Premedication was not administered for two reasons. First of all, because the superficial cervical plexus block anesthetizes the supraclavicular nerves and thus the injection sites of the subsequent blocks. Secondly, our study required an accurate and timely performed neurological assessment before and after the blocks. Therefore,

we did not want any sedative or opioid to confound the interpretation of the data.

The need for three injections, change of patient's body position, and change of needle type during the procedure, make our triple block method more time consuming compared to the interscalene block.<sup>15</sup> However, in order to provide surgical anesthesia, the alternative of low volume interscalene block, requires an additional anesthesiological technique (general anesthesia, local skin infiltration or a supraclavicular nerve block), which is time consuming as well. This novel block combination might reduce costs spent on personnel and supplies, but such benefit over the interscalene block must be tested in a randomized controlled study.

The incidence of intraoperative cerebral desaturation in patients receiving general anesthesia in the beach-chair position is of great concern.<sup>6</sup> A major advantage of this novel block combination is that general anesthesia could be omitted in 19 out of 20 patients. By using only light propofol sedation, we could easily communicate with the patient and thereby directly monitor cerebral function intraoperatively.

In conclusion, this novel combination of peripheral nerve blocks provides surgical anesthesia and satisfactory post-operative analgesia for patients scheduled for arthroscopic shoulder surgery. A randomized controlled trial should be undertaken to compare this shoulder block with the interscalene block.

### Acknowledgments

None.

### References

1. Liu SS, Gordon MA, Shaw PM, Wilfred S, Shetty T, Yadeau JT. A prospective clinical registry of ultrasound-guided regional anesthesia for ambulatory shoulder surgery. *Anesth Analg* 2010; 111: 617–23.
2. Lee JH, Cho SH, Kim SH, Chae WS, Jin HC, Lee JS, Kim YI. Ropivacaine for ultrasound-guided interscalene block: 5 mL provides similar analgesia but less phrenic nerve paralysis than 10 mL. *Can J Anaesth* 2011; 58: 1001–6.
3. Riaz S, Carmichael N, Awad I, Holtby RM, McCartney CJ. Effect of local anaesthetic volume

- (20 vs 5 ml) on the efficacy and respiratory consequences of ultrasound-guided interscalene brachial plexus block. *Br J Anaesth* 2008; 101: 549–56.
4. Conroy PH, Awad IT. Ultrasound-guided blocks for shoulder surgery. *Curr Opin Anaesthesiol* 2011; 24: 638–43.
  5. Sites BD, Taenzer AH, Herrick MD, Gilloon C, Antonakakis J, Richins J, Beach ML. Incidence of local anesthetic systemic toxicity and postoperative neurologic symptoms associated with 12,668 ultrasound-guided nerve blocks: an analysis from a prospective clinical registry. *Reg Anesth Pain Med* 2012; 37: 478–82.
  6. Nielsen HB. Systematic review of near-infrared spectroscopy determined cerebral oxygenation during non-cardiac surgery. *Front Physiol* 2014; 5: 93.
  7. Hogan QH. Phrenic nerve function after interscalene block revisited: now, the long view. *Anesthesiology* 2013; 119: 250–2.
  8. Jules-Elysee K, Reid SC, Kahn RL, Edmonds CR, Urban MK. Prolonged diaphragm dysfunction after interscalene brachial plexus block and shoulder surgery: a prospective observational pilot study. *Br J Anaesth* 2014; 112: 950–1.
  9. Tran DQ, Elgueta MF, Aliste J, Finlayson RJ. Diaphragm-sparing nerve blocks for shoulder surgery. *Reg Anesth Pain Med* 2017; 42: 32–8.
  10. Borgeat A, Ekatothramis G. Anaesthesia for shoulder surgery. *Best Pract Res Clin Anaesthesiol* 2002; 16: 211–25.
  11. Aszmann OC, Dellon AL, Birely BT, McFarland EG. Innervation of the human shoulder joint and its implications for surgery. *Clin Orthop Relat Res* 1996; 330: 202–7.
  12. Renes SH, Rettig HC, Gielen MJ, Wilder-Smith OH, van Geffen GJ. Ultrasound-guided low-dose interscalene brachial plexus block reduces the incidence of hemidiaphragmatic paresis. *Reg Anesth Pain Med* 2009; 34: 498–502.
  13. Renes SH, van Geffen GJ, Rettig HC, Gielen MJ, Scheffer GJ. Minimum effective volume of local anesthetic for shoulder analgesia by ultrasound-guided block at root C7 with assessment of pulmonary function. *Reg Anesth Pain Med* 2010; 35: 529–34.
  14. Renes SH, Spoormans HH, Gielen MJ, Rettig HC, van Geffen GJ. Hemidiaphragmatic paresis can be avoided in ultrasound-guided supraclavicular brachial plexus block. *Reg Anesth Pain Med* 2009; 34: 595–9.
  15. Dhir S, Sondekoppam RV, Sharma R, Ganapathy S, Athwal GS. A comparison of combined suprascapular and axillary nerve blocks to interscalene nerve block for analgesia in arthroscopic shoulder surgery: an equivalence study. *Reg Anesth Pain Med* 2016; 41: 564–71.
  16. Tran DQ, Dugani S, Finlayson RJ. A randomized comparison between ultrasound-guided and landmark-based superficial cervical plexus block. *Reg Anesth Pain Med* 2010; 35: 539–43.
  17. Siegenthaler A, Moriggl B, Mlekusch S, Schliessbach J, Haug M, Curatolo M, Eichenberger U. Ultrasound-guided suprascapular nerve block, description of a novel supraclavicular approach. *Reg Anesth Pain Med* 2012; 37: 325–8.
  18. Rothe C, Steen-Hansen C, Lund J, Jenstrup MT, Lange KH. Ultrasound-guided block of the suprascapular nerve - a volunteer study of a new proximal approach. *Acta Anaesthesiol Scand* 2014; 58: 1228–32.
  19. Flohr-Madsen S, Ytrebo LM, Valen K, Wilsgaard T, Klaastad O. A randomised placebo-controlled trial examining the effect on hand supination after the addition of a suprascapular nerve block to infraclavicular brachial plexus blockade. *Anaesthesia* 2016; 71: 938–47.
  20. Leung S, Zlotolow DA, Kozin SH, Abzug JM. Surgical anatomy of the supraclavicular brachial plexus. *J Bone Joint Surg Am* 2015; 97: 1067–73.
  21. Flohr-Madsen S, Ytrebo LM, Kregnes S, Wilsgaard T, Klaastad O. Minimum effective volume of ropivacaine 7.5 mg/ml for an ultrasound-guided infraclavicular brachial plexus block. *Acta Anaesthesiol Scand* 2013; 57: 495–501.
  22. Paternostro-Sluga T, Grim-Stieger M, Posch M, Schuhfried O, Vacariu G, Mittermaier C, Bittner C, Fialka-Moser V. Reliability and validity of the Medical Research Council (MRC) scale and a modified scale for testing muscle strength in patients with radial palsy. *J Rehabil Med* 2008; 40: 665–71.
  23. Compston A. Aids to the investigation of peripheral nerve injuries. Medical Research Council: Nerve Injuries Research Committee. His Majesty's Stationery Office: 1942; pp. 48 (iii) and 74 figures and 7 diagrams; with aids to the examination of the peripheral nervous system. By Michael O'Brien for the Guarantors of Brain. Saunders Elsevier: 2010; pp. [8] 64 and 94 Figures. *Brain* 2010; 133: 2838–44.
  24. Shih ML, Duh QY, Hsieh CB, Liu YC, Lu CH, Wong CS, Yu JC, Yeh CC. Bilateral superficial cervical plexus block combined with general anesthesia administered in thyroid operations. *World J Surg* 2010; 34: 2338–43.

25. Gurkan Y, Tas Z, Toker K, Solak M. Ultrasound guided bilateral cervical plexus block reduces postoperative opioid consumption following thyroid surgery. *J Clin Monit Comput* 2015; 29: 579–84.
26. Pandit JJ, Satya-Krishna R, Gration P. Superficial or deep cervical plexus block for carotid endarterectomy: a systematic review of complications. *Br J Anaesth* 2007; 99: 159–69.
27. Petrar SD, Seltnerich ME, Head SJ, Schwarz SK. Hemidiaphragmatic paralysis following ultrasound-guided supraclavicular versus infraclavicular brachial plexus blockade: a randomized clinical trial. *Reg Anesth Pain Med* 2015; 40: 133–8.
28. Horiguchi M. The cutaneous branch of some human suprascapular nerves. *J Anat* 1980; 130: 191–5.
29. Ajmani ML. The cutaneous branch of the human suprascapular nerve. *J Anat* 1994; 185(Pt 2): 439–42.
30. Hemmings HC, Egan TD. *Pharmacology and physiology for anesthesia: foundations and clinical application*. Philadelphia, PA: Elsevier/Saunders, 2013.