

Fracture of the base of the fifth metatarsal in athletes treated with intramedullary AO cancellous screw fixation

Tromsø 05.09.2010

5. års oppgave i stadium IV- Profesjonsstudiet i medisin ved Universitetet i Tromsø

Stud. Med. Anneli Giske, Mk -05

Veileder og medforfatter: Dr. Erik A. Rosenlund
Volvat Medisinske Senter, Oslo
Adresse: Pb 5280 Majorstua, 0303 Oslo
Tlf: 93033075

Nøkkelord: Brudd, idrett, ortopedi.

Contents:

Abstract:	2
Fracture of the base of the fifth metatarsalin athletes treated with intramedullary AO cancellous screw fixation.....	3
Material and methods:.....	5
Results:.....	7
Discussion:	8
Conclusion:	12
Illustrations:	13
References:.....	14

Abstract:

Background: Stress fracture of the fifth metatarsal bone is a common injury in athletes. The purpose to this study was to review the long-term clinical results of internal fixation with a solid 6.5 mm cancellous AO screw in active patients.

Materials and methods: Retrospective study of all patients treated surgically at Volvat Medical Centre in Oslo from 1995 – 2006. 37 patients with 40 stress fractures of the fifth metatarsal bone were treated with AO screw fixation. 36 patients with 39 fractures were available for interviews. 29 were soccer players, four team handball players, two long distance runners and one was played basketball. The group consisted of two female and 35 male athletes. The average age was 23.7 years (17-32) and average follow up time was 5.3 years (10.1 – 146.2 months). 30 of the fractures were previously treated conservatively (76.9%), leading either to delayed union, refracture, non-union or pseudoarthrosis.

Results: All fractures healed and there were no recurrence of fracture. Treatment was rated successful if the patient was able return to full pre-injury level. 36 of 39 (92.3%) cases returned to full level of activity. The time from surgery until return to pre-injury level varied from 5.6-22.4 weeks, median 8.6 weeks. There were no infections. 10 patients felt tenderness when kicked or stepped on, but this did not limit their activity. 38 out of 39 operations resulted in patient satisfaction and they would have gone through the same treatment again. Of the 39 operations, 36 of the patients came to the conclusion that they would have preferred surgical treatment as the first treatment option.

Conclusion: Athletes with stress fracture of the fifth metatarsal bone can be successfully treated with AO 6.5 mm cancellous screw fixation. Athletes with a refracture or failed conservative treatment should be treated this way.

Fracture of the base of the fifth metatarsal in athletes treated with intramedullary AO cancellous screw fixation.

The optimal treatment of proximal fifth metatarsal fractures is a topic of great debate. Use of the term "Jones fracture" to describe all such injuries in orthopaedic literature and among treating physicians has added confusion to the topic. Because of circulatory differences, knowledge of anatomy is vital in distinguishing the fracture types [1-3]. The base of the fifth metatarsal has three anatomic fracture zones and each has its distinct characteristics (Figure 1). Zone 1: Tuberosity avulsion fracture, caused by forces exerted to the peroneus brevis tendon or the lateral band of the plantar fascia with inversion of the foot. Zone 2: Fractures in the metaphyseal-diaphyseal junction, also known as Jones fracture. This is a stress fracture which typically occurs as the result of indirect trauma, due to overload or overuse [4]. And zone 3: Diaphyseal stress fracture.

In 1984 Torg et al classified the Jones fracture into subtypes based on the age of the fracture [5] (Table 1). The acute fracture (Type I) was defined as a narrow fracture line with no intramedullary sclerosis. The distinguishing features that defined the delayed union (Type II) were a previous fracture, a widened fracture line, and evidence of intramedullary sclerosis. The features that defined the non-union (Type III) were a history of repetitive trauma, a wide fracture line with periosteal new bone and complete obliteration of the medullary canal at the fracture site by sclerotic bone.

Stress fracture of the fifth metatarsal bone is a common injury among athletes, especially in soccer players. Soccer boots have its flexpoint just beneath the base of fifth metatarsal, which gives extra stress. Also one of the studs is often localized in this area, and worsens the stress. A Jones fracture occurs with the elevation of the heel, hyperextension of the metatarsophalangeal joints, and loading of the lateral aspect of the foot

[5,6]. Inversion of the foot is not necessary to produce the fracture [6]. The criteria for a stress fracture, established by DeLee et al [7], are pain before the onset of acute fracture, radiographic evidence of stress phenomenon, and no prior treatment.

Sir Robert Jones originally described the fracture in 1902 [8]. In 1927 Carp noted the difficulty in achieving union of proximal fifth metatarsal fractures [9]. The fracture has been treated operatively and conservatively. Conservative treatment has a high incidence of delayed healing, pseudoarthrosis and refracture [6, 7, 10-16], although some have reported good results [5, 13, 17, 18]. This type of fracture presents a difficult treatment dilemma in the active patients.

Surgical fixation for managing fractures of fifth metatarsal bone was first described by Kavanaugh et al in 1978 [6]. In recent years surgical management of fifth metatarsal fracture has been advocated, [7, 13-15, 19-24]. The clinical studies following intramedullary screw fixation have reported good results with shortened clinical and radiographic union time as compared to the traditional cast immobilization method [7, 13-16, 22, 24-27]. Most authors have recommended this treatment only for competitive athletes [6, 7, 12, 13, 19, 20, 24, 25], but Portland et al recommended intramedullary screw fixation in nonathletes as well [26]. Intramedullary screws offer the added benefits of compression across the fracture without the need to open the fracture site, strip the periostum or remove hardware.

Internal fixation has become the treatment of choice among athletes and active patients, because return to pre-injury activity level can be quicker as compared to conservative treatment. However, refracture has been reported [28-30], and the optimal type of screw fixation remains controversial [23, 28].

The purpose of this study was to review the long-term clinical results of internal fixation with a solid 6.5 mm cancellous AO screw in active patients.

Material and methods:

This was a retrospective study using a phone survey, of 39 athletes who were treated by the same two surgeons with fixation for a fifth metatarsal bone fracture. From April 1995 through September 2006 every patient with a fracture in the proximal fifth metatarsal bone were treated surgically by the co-writer and his colleague. Follow up was performed during July 2007.

Inclusion criteria for the study were fractures in the proximal fifth metatarsal. All fractures were localized in zone 2, and all fractures were stress fractures or refracture to a prior stress fracture. According to the classification mentioned above, our material is defined as Jones fractures in all three sub-categories.

We used the same procedure, internal fixation with a solid 6.5mm cancellous AO screw, for all the patients. The group consisted of two females, one of them with bilateral fractures, and 35 male athletes, including two with bilateral fractures. 36 patients with 39 fractures were available for interview. The player not available for interview at the time of follow up, was playing professional soccer in China. For 28 patients the level of activity at the time the injury occurred, was reported to be over seven times per week. 10 patients' activity level ranged from 5-7 times per week, while the last one reported an activity level of 1-4 times per week. 29 patients were soccer players, four team handball players, two long distance runners and one played basketball. 16 right feet and 23 left feet were involved. The age ranged from 17-32 years, mean 23.7 years.

The sample of patients was selected from a difficult group, since Volvat Medical Center is a private clinic, where secondary intervention is common.

Surgical technique

All patients underwent the same surgical procedure. Surgery was performed on an outpatient basis using general anesthesia, tourniquet and radiological control. The patient was placed in a semi lateral decubitus position so

adequate internal rotation of the hip could be obtained. The foot was placed under a fluoroscopy machine, and the surgeon confirmed that clear AP, lateral, and oblique views of the fifth metatarsal were obtained.

Approximately a 1,5 cm long incision was made starting just posterior to the proximal tip of the fifth metatarsal and extending posteriorly along the lateral border of the foot. Care was taken to avoid branches of the sural nerve which can run dorsally and laterally over the metatarsal [31]. The fascia was split and a self-holding retractor was used to pull the peroneal tendon aside.

The medullary canal was opened with an awl. Then drilling started, using a 3.2 mm drill, advancing to a 4.5mm drill for larger canals. A solid 6.5mm partly threaded AO cancellous screw with a long neck (Figure 2), was then inserted under fluoroscopic guidance over the guide pin to ensure intramedullary placement. The goal was rigid fixation of the fracture with compression across the fracture site. We ensured that the head of the screw was secured into the bone, but did not penetrating. Routine closure was undertaken.

Rehabilitation

Immobilization with a cast or orthosis was not required. The post-operative rehabilitation included elevation of the foot for the first three days, then partial weight bearing and crutches for three weeks. Cycling, swimming and other non-weight bearing activities were allowed as tolerated. The next three weeks the patients were allowed to increase activity, and after 6 weeks they were allowed to resume activity as tolerated.

Follow up

Average follow up time was mean 5.4 years (median 4.9 years), ranging from 10.2 to 146.5 months. To minimize errors in source as a consequence at long follow-up time, letters where first sent out to the patients so they could prepare their answers. Phone surveys were conducted with a series of objective and subjective questions.

Results:

At the time of injury, all subjects were involved in athletic activities that required running and jumping. 30 of the fractures were previously treated conservatively (76.9%), leading either to delayed union, non-union, refracture or pseudoarthrosis. One patient was previously treated with a thin screw which led to an unstable fixation and lack of healing, while eight fractures (20.5%) had no prior treatment and were treated early, less than 16 days after injury occurred. Considering all the cases, except those eight patients who received early intervention, the time from first fracture to surgery had a mean of 25.9 weeks (median 33.1 weeks) ranging from 3.9-163.3 weeks. 17 (43.5%) of the actual fractures were refractures, while 22 (56.4%) were first-time fractures. Of those with refracture, 9 (52.9%) experienced their first refracture, seven (41.2%) reported their second refracture, while for one this was the fifth refracture. In 22 cases (56.4%), the patients had prodromal symptoms from the lateral part of the foot. Median time between the last fracture and surgical treatment was 4.7 weeks, ranging from 0.1-48.3 weeks. Mean time was 9.2 weeks, but there were some high outliers.

The average time from surgical treatment and return to full activity level (figure 3), was a median of 8.6 weeks (5.6-22.4), mean 9.6 weeks. All fractures healed and there were no recurrence of fracture. Treatment was rated successful if the patient was able return to pre-injury level of activity. 36 of 39 cases (92.3%) returned to full level of activity. Three patients used more than 13 weeks until they returned to full level of activity and therefore was rated as “delayed unions” (Table 2). 10 patients felt tenderness when kicked or stepped on, but this did not limit their activity. There were no infections and no refractures.

38 out of 39 operations resulted in patient satisfaction and they would undergo the same treatment again. Of the 39 operations, 36 patients came to the conclusion that they would have preferred surgical treatment as the first treatment option.

Discussion:

Jones fractures can be challenging to treat and can result in a significant disability for active patients. Some of the discussion around treatment of fifth metatarsal fracture compares conservative and surgical treatment.

In 1984 Torg et al achieved a 93% healing rate for treatment of acute Jones fractures in a non-weight bearing cast for 8 weeks [4]. However, with non-weight bearing cast treatment, treatment failure is reported up to 50 % [12], 44% [14] and 28% [10], whereas several clinical studies following intramedullary screw fixation results in quicker time to union and return to sports, and a lower refracture rate [5-7, 10, 11, 13-16, 21-28, 32-34].

In our study, return to pre-injury level of activity was defined from the date the patients participated in competition without problems. In some cases the patient was able to participate in sports, but did not participate due to off-season. In those cases the date reported was when the patient was rehabilitated and fully able to participate in competitions.

Considering the cases except from those eight who were treated early, the patients experienced what an insufficient treatment can cause. In this group there were 31 cases. During the period of insufficient treatment these patients were forced into a long period of not being able to train and compete at the desired level. After surgery 29 of these 31 cases returned to pre-injury level (Table 2).

Three patients never returned to pre-injury level and were rated as “non-succesful”. One of them retired due to other causes while waiting for surgery, but was able to compete after 8.0 weeks without any pain. The two others had pain limiting their activity post-operatively. Pain from the head of the screw was rated as a possible cause, and the screws were removed. Despite the fact that the fractures were radiologically healed, these two never returned because of pain and other injuries.

Two other cases experienced post-operative complications due to the screw size. The most plausible explanation was that the screw was too long and made the fracture gap. One of the patients had the screw removed, and then returned to previous level of activity after 14.9 weeks from the first surgery, while the other fracture healed in spite of the long screw and he returned to pre-injury level in 10.6 weeks.

Delayed union was defined as cases where the patient used more than 13 weeks before they returned to pre-injury level of activity. All fractures were by this time radiologically healed. Three patients were classified in this group (Table 2). One of the patients had to have the screw removed, as mentioned above. This can explain the delayed rehabilitation time. One other patient had earlier experienced a refracture and therefore took extra caution not to refracture again, influencing his activity. The last one reported that the fracture healed, but he could not participate at pre-injury level without pain before 22.4 weeks after the surgery. We did not find any medical reason for this.

Screw head discomfort, seen in 10 of the 39 cases (25.6%) in our study and in 3 of 10 patients (30%) in the study of DeLee et al [7], appears to be the most common problem. In our study this discomfort did not prevent patients from participating at pre-injury level.

Refracture has been reported with internal fixation [28-30], and the optimal screw fixation remains controversial [23, 28]. We used a solid 6.5 mm AO cancellous screw, which has the best mechanical properties. It is strong and has good fatigue resistance, large threads gives it a good grip to the bone intramedullary and a long neck and large head provides good compression. Many refuse to use an AO cancellous screw because they believe it is too thick. In the literature, however, authors are very concerned that the screw must have sufficient diameter [21, 23, 27-30]. Wright et al reported six refractures after complete radiographic and clinical union utilizing cannulated screw fixation of Jones fractures in athletes [30], and

recommended that screw fixation using a large-diameter screw should be given careful consideration for patients with large body mass.

There are different types of screws. Selection of a cannulated versus a solid screw is based on strength characteristics. There are some studies comparing cannulated to non cannulated screws: Pietropaoli et al conducted a study demonstrating the biomechanical difference between a 4.5 mm malleolar screw and a 4.5 mm partially threaded cancellous cannulated screw [35]. They concluded that solid screws are less likely to break, but it is not clear whether this difference is significant. They stated that either screw should allow for early normal weight bearing and concluded that the choice of screw should be at the surgeon's discretion. Take note that a malleolar screw is thinner than a cannulated cancellous screw. The authors did not mention whether failure at the fracture site was accompanied by bending or breakage of the screws, and in that study they used a three-point bending model, which may not represent the true forces experienced in vivo.

Reese et al compared both screw size and different screw types. Screw fatigue data showed that the number of cycles to failure increased with ascending screw diameter, and the mean number of cycles to failure was 4308 for cannulated titanium screws, 22 012 for cannulated stainless steel screws, and 44 523 for non cannulated stainless steel screws. The laboratory study suggests that the largest screw possible should be used for surgical fixation of these fractures and that screws less than 4 mm in diameter should be used with caution [27]. They stated that non-cannulated stainless steel screws were the strongest, and that cannulated screws may be too weak.

Conversely, Leggon et al noted that the holding strength of cannulated screws is not significantly affected by the changes needed to accommodate cannulation [36]. And Porter et al reported that 23 consecutive athletes treated surgically with a 4.5 cannulated stainless steel screw for Jones fractures [22]. The authors reported a 100% clinical healing rate, a mean radiographic healing rate of 98.9% and a zero incidence of refracture in this series.

Also described in the literature are other different surgical techniques. Most authors refer to an intramedullary method, but there are also surgeons who have used other techniques. Kline used a 3.0 mm cannulated screw, angulated in a proximal-plantar to distal-dorsal direction (figure 4) [37]. The problem is that the screw head is located lateral to the base of the fifth metatarsal and can cause irritation and pain, removal of screw can be required. Another problem is that you can not drill up a marrow canal with intramedullary sclerosis, in those cases the patient have had problems standing for long periods of time or recidive to previously conservatively treated fracture.

Even though surgical treatment is recommended for Jones fractures, there are surgically related complications. Potential technical errors during screw fixation include extension of the fracture during screw insertion, screw threads crossing the fracture site, and penetration of the diaphyseal cortex by the screw. Too thick of a screw may cause a distal fracture and increase the risk of stress shielding across the fracture site. A screw with a long neck gives the best compression over the fracture site, and the screw neck must be long enough so that the threads are distal to the fracture site.

However, too long of a screw may be detrimental because a straight screw passing down curved bone may gap the fracture. Ebraheim et al demonstrated that the intramedullary canal is bowed and the dorsoplantar diameter is more than 1 mm narrower than the mediolateral diameter [38]. Refracture after surgical treatment of a Jones fracture can occur after healing and screw removal, thus, it is recommended that the screw be left in until the end of the patient's athletic career [13].

The draw back of this study is that it is retrospective. Average follow up ranged from 10.2 to 146.5 months. Even though letters where first sent out to the patients so they could prepare their answers, we have to expect some recall bias.

We have not compared conservative treatment to surgical treatment, and can not draw any conclusions about treatment of choice among active patients with a fifth metatarsal fracture. For this a RCT study is needed were the long-time outcome between the two groups can be compared. The findings in this study are based on a sample of patients selected from a difficult group, since Volvat Medical Center is a private clinic, where secondary intervention is common. Thus, we can not recommend this surgical treatment beyond other methods as a first treatment option.

Conclusion:

To summarize, in this study 92.3% returned to pre-injury level of activity with a zero incidence of refracture. Patient satisfaction rate is high, while the complication rate is low. The treatment resulted in short time to clinical union and allowed patients to return to sports and normal daily activities faster than the traditional cast treatment. Athletes with a stress fracture in the fifth metatarsal bone can be successfully treated with AO 6.5 mm cancellous screw fixation. Athletes with a refracture, failed conservative treatment or type III fracture, should be treated this way. This treatment is even a good alternative as first treatment for acute Jones fractures.

Illustrations:

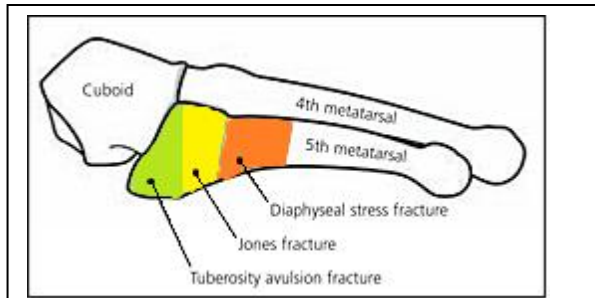


Figure 1:

Demonstrating the three types of proximal fifth metatarsal fracture by zone: 1, tuberosity avulsion; 2, metaphyseal-diaphyseal junction (Jones); and 3, diaphyseal stress.



Figure 2: Partially threaded 6.5 mm cancellous screw

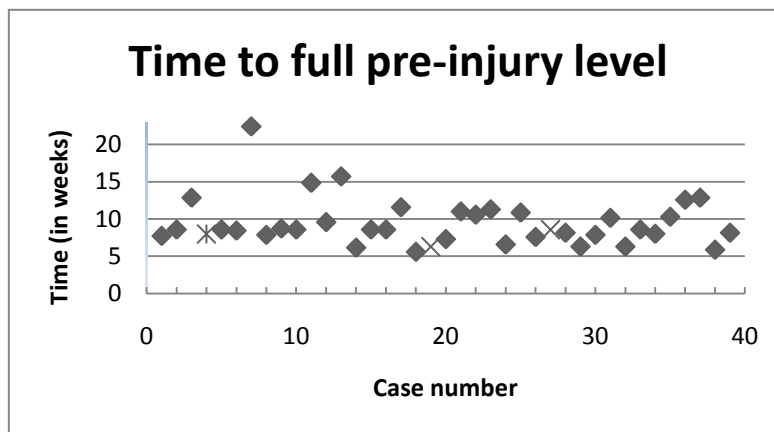


Figure 3: Time to full pre-injury level. Case number 4 retired due to other causes while waiting for surgery, but was able to compete at full level at the given time. Patient number 19 and 27 did not return to full pre-injury level due to this and other injuries. Their given time refers to “radiologically healed”, but is not included in the rest of the data.

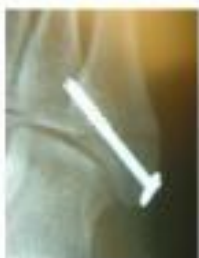

Figure 4: A 3.0mm angulated screw in a proximal-plantar to distal-dorsal direction [37].

Type	Age of Fracture	Characteristics
I	Acute	Narrow fracture line, no intramedullary sclerosis
II	Delayed union	Widened fracture line with intramedullary sclerosis
III	Nonunion	Medullary canal obliterated

Table 1: Torg classification of proximal fifth metatarsal fracture by radiographic appearance [5].

Patient	Category	Prior fracture	Pain limiting activity	Screw removed	No return due to this injury	Satisfied	Same procedure again?	First alternative
4	No return	Yes						No
8	Delayed union	No						
12	Delayed + Complication	No	Yes	Yes				No
14	Delayed union	Yes						
19	No return	No	Yes	Yes	Yes	No	No	No
23	Complication	Yes						
27	No return	No	Yes	Yes	Yes			

Table 2: An extract of the data table which illustrates that the same patients were behind many of the divergent answers. Seven patients which had a complication or delayed union, were arranged in one column. Patients who are not included here, had no abnormal responses in any of the categories. The answers differed from the total patient group, are highlighted in colored

References:

- Den Hartog, B.D., *Fracture of the proximal fifth metatarsal*. J Am Acad Orthop Surg, 2009. **17**(7): p. 458-64.
- Shereff, M.J., et al., *Vascular anatomy of the fifth metatarsal*. Foot Ankle, 1991. **11**(6): p. 350-3.
- Smith, J.W., S.P. Arnoczky, and A. Hersh, *The intraosseous blood supply of the fifth metatarsal: implications for proximal fracture healing*. Foot Ankle, 1992. **13**(3): p. 143-52.
- Torg, J.S., *Fractures of the base of the fifth metatarsal distal to the tuberosity*. Orthopedics, 1990. **13**(7): p. 731-7.
- Torg, J.S., et al., *Fractures of the base of the fifth metatarsal distal to the tuberosity. Classification and guidelines for non-surgical and surgical management*. J Bone Joint Surg Am, 1984. **66**(2): p. 209-14.
- Kavanaugh, J.H., T.D. Brower, and R.V. Mann, *The Jones fracture revisited*. J Bone Joint Surg Am, 1978. **60**(6): p. 776-82.
- DeLee, J.C., J.P. Evans, and J. Julian, *Stress fracture of the fifth metatarsal*. Am J Sports Med, 1983. **11**(5): p. 349-53.
- Jones, R., *I. Fracture of the Base of the Fifth Metatarsal Bone by Indirect Violence*. Ann Surg, 1902. **35**(6): p. 697-700 2.
- Carp, L., *Fracture of the Fifth Metatarsal Bone: With Special Reference to Delayed Union*. Ann Surg, 1927. **86**(2): p. 308-20.
- Clapper, M.F., T.J. O'Brien, and P.M. Lyons, *Fractures of the fifth metatarsal. Analysis of a fracture registry*. Clin Orthop Relat Res, 1995(315): p. 238-41.
- Dameron, T.B., Jr., *Fractures and anatomical variations of the proximal portion of the fifth metatarsal*. J Bone Joint Surg Am, 1975. **57**(6): p. 788-92.
- Fernandez Fairen, M., et al., *Fractures of the fifth metatarsal in basketball players*. Knee Surg Sports Traumatol Arthrosc, 1999. **7**(6): p. 373-7.
- Josefsson, P.O., et al., *Jones fracture. Surgical versus nonsurgical treatment*. Clin Orthop Relat Res, 1994(299): p. 252-5.

14. Mologne, T.S., et al., *Early screw fixation versus casting in the treatment of acute Jones fractures*. Am J Sports Med, 2005. **33**(7): p. 970-5.
15. Yue, J.J. and R.E. Marcus, *The role of internal fixation in the treatment of Jones fractures in diabetics*. Foot Ankle Int, 1996. **17**(9): p. 559-62.
16. Zelko, R.R., J.S. Torg, and A. Rachun, *Proximal diaphyseal fractures of the fifth metatarsal--treatment of the fractures and their complications in athletes*. Am J Sports Med, 1979. **7**(2): p. 95-101.
17. Zogby, R.G. and B.E. Baker, *A review of nonoperative treatment of Jones' fracture*. Am J Sports Med, 1987. **15**(4): p. 304-7.
18. Acker, J.H. and D. Drez, Jr., *Nonoperative treatment of stress fractures of the proximal shaft of the fifth metatarsal (Jones' fracture)*. Foot Ankle, 1986. **7**(3): p. 152-5.
19. Arangio, G.A., *Proximal diaphyseal fractures of the fifth metatarsal (Jones' fracture): two cases treated by cross-pinning with review of 106 cases*. Foot Ankle, 1983. **3**(5): p. 293-6.
20. Hens, J. and M. Martens, *Surgical treatment of Jones fractures*. Arch Orthop Trauma Surg, 1990. **109**(5): p. 277-9.
21. Kelly, I.P., et al., *Intramedullary screw fixation of Jones fractures*. Foot Ankle Int, 2001. **22**(7): p. 585-9.
22. Porter, D.A., M. Duncan, and S.J. Meyer, *Fifth metatarsal Jones fracture fixation with a 4.5-mm cannulated stainless steel screw in the competitive and recreational athlete: a clinical and radiographic evaluation*. Am J Sports Med, 2005. **33**(5): p. 726-33.
23. Shah, S.N., et al., *Intramedullary screw fixation of proximal fifth metatarsal fractures: a biomechanical study*. Foot Ankle Int, 2001. **22**(7): p. 581-4.
24. Traina, S.M. and J.P. McElhinney, *The Herbert screw in closed reduction and internal fixation of the Jones fracture*. Orthop Rev, 1991. **20**(8): p. 713, 716-7.
25. Mindrebo, N., et al., *Outpatient percutaneous screw fixation of the acute Jones fracture*. Am J Sports Med, 1993. **21**(5): p. 720-3.
26. Portland, G., A. Kelikian, and S. Kodros, *Acute surgical management of Jones' fractures*. Foot Ankle Int, 2003. **24**(11): p. 829-33.
27. Reese, K., et al., *Cannulated screw fixation of Jones fractures: a clinical and biomechanical study*. Am J Sports Med, 2004. **32**(7): p. 1736-42.
28. Glasgow, M.T., et al., *Analysis of failed surgical management of fractures of the base of the fifth metatarsal distal to the tuberosity: the Jones fracture*. Foot Ankle Int, 1996. **17**(8): p. 449-57.
29. Larson, C.M., et al., *Intramedullary screw fixation of Jones fractures. Analysis of failure*. Am J Sports Med, 2002. **30**(1): p. 55-60.
30. Wright, R.W., et al., *Refracture of proximal fifth metatarsal (Jones) fracture after intramedullary screw fixation in athletes*. Am J Sports Med, 2000. **28**(5): p. 732-6.
31. Donley, B.G., et al., *Risk of sural nerve injury with intramedullary screw fixation of fifth metatarsal fractures: a cadaver study*. Foot Ankle Int, 1999. **20**(3): p. 182-4.
32. Dameron, T.B., Jr., *Fractures of the Proximal Fifth Metatarsal: Selecting the Best Treatment Option*. J Am Acad Orthop Surg, 1995. **3**(2): p. 110-114.
33. Nunley, J.A., *Fractures of the base of the fifth metatarsal: the Jones fracture*. Orthop Clin North Am, 2001. **32**(1): p. 171-80.
34. O'Shea, M.K., et al., *Clinical perspective of the treatment of fifth metatarsal fractures*. J Am Podiatr Med Assoc, 1995. **85**(9): p. 473-80.
35. Pietropaoli, M.P., et al., *Intramedullary screw fixation of Jones fractures: a biomechanical study*. Foot Ankle Int, 1999. **20**(9): p. 560-3.
36. Leggon, R., et al., *The holding strength of cannulated screws compared with solid core screws in cortical and cancellous bone*. J Orthop Trauma, 1993. **7**(5): p. 450-7.
37. Kline, A., *A case report with special emphasis on fixation placement*. Podiatry Internet Journal, 2006. **1**(12).
38. Ebraheim, N.A., et al., *Anatomical and radiological considerations of the fifth metatarsal bone*. Foot Ankle Int, 2000. **21**(3): p. 212-5.