

Free Vascularized Fibula Graft as Primary Salvage Procedure for Acute Cervical Osteomyelitis Caused by Epidural Abscess

Timothy A. Ciosek, MD*†

Andreas Sørli, MD‡§

Jens Munch-Ellingsen, MD, PhD‡§

Tore K. Solberg, MD, PhD‡§

Sven Weum, MD, PhD¶

Louis de Weerd, MD, PhD*†

Summary: Acute cervical osteomyelitis due to an epidural abscess and pyogenic spondylodiscitis in an immunosuppressed patient with progressive myelopathy is a challenge for the reconstructive surgeon. This report presents our novel approach to treat such a condition in a 56-year-old patient in whom antibiotic treatment and decompression of the medulla by laminectomy of C4–C6 failed. Under general anesthesia, debridement of all infected tissue, including anterior corpectomy of C4–C6, was performed. Simultaneously, a free vascularized fibula graft (FVFG) was harvested, adapted to the bone defect, and anastomosed to the superior thyroid artery and external jugular vein. The graft was stabilized with an anterior plate. A scheduled posterior stabilization was performed 1 week later. *Staphylococcus aureus* was cultured from bone samples and was treated with antibiotics. The postoperative course was uncomplicated besides a dorsal midline defect 6 weeks postoperatively that was closed with a sensate midline-based perforator flap. Five years on, the patient is infection free, and regular control computed tomography and magnetic resonance imaging scan images show progressive fusion and hypertrophy of the fibula to C3/C7 vertebrae. An FVFG combined with posterior stabilization could be a promising primary salvage procedure in cases with progressive myelopathy caused by acute cervical osteomyelitis due to spinal infection. The FVFG contributes to blood circulation, delivery of antibiotics, and an immunological response to the infected wound bed and can stimulate rapid fusion and hypertrophy over time. (*Plast Reconstr Surg Glob Open* 2024; 12:e5837; doi: [10.1097/GOX.0000000000005837](https://doi.org/10.1097/GOX.0000000000005837); Published online 24 May 2024.)

INTRODUCTION

Acute pyogenic cervical spinal infection with concomitant vertebral osteomyelitis is a life-threatening disease with increasing incidence and associated with complications such as sepsis, myelopathy, kyphotic deformity, and

spinal instability.¹ When conservative medical treatment fails, urgent aggressive surgical treatment to avoid paralysis or death is required. The principles of definitive surgical treatment for spinal infection have been described by Ramasastry et al² and are based upon removal of infected tissue, decompression of the medulla, antibiotic treatment, obliteration of dead space, and spinal stabilization. However, compared with thoracic and lumbar regions, acute cervical spinal infection with osteomyelitis is a formidable adversary with potentially ruinous results.³ Reconstruction of the infected cervical column challenges the reconstructive surgeon with compact anatomy, building biomechanical stability, and operating in a field with complicated infectious dissemination. There is also a higher risk for more severe neurological complications compared with thoracic and lumbar regions. The number of reports for cervical reconstruction due to cervical

From the *Department of Plastic and Reconstructive Surgery, University Hospital of North Norway, Tromsø, Norway; †Dermatoplastic Imaging Research Group, Department of Clinical Medicine, UiT The Arctic University of Norway, Tromsø, Norway; ‡Department of Neurosurgery, University Hospital of North Norway, Tromsø, Norway; §Faculty of Health Sciences, Department of Clinical Medicine, UiT The Arctic University of Norway, Tromsø, Norway; and ¶Department of Radiology, University Hospital of North Norway, Tromsø, Norway.

Received for publication November 16, 2023; accepted April 4, 2024.

Copyright © 2024 The Authors. Published by Wolters Kluwer Health, Inc. on behalf of The American Society of Plastic Surgeons. This is an open-access article distributed under the terms of the [Creative Commons Attribution-Non Commercial-No Derivatives License 4.0 \(CCBY-NC-ND\)](https://creativecommons.org/licenses/by-nc-nd/4.0/), where it is permissible to download and share the work provided it is properly cited. The work cannot be changed in any way or used commercially without permission from the journal.

DOI: [10.1097/GOX.0000000000005837](https://doi.org/10.1097/GOX.0000000000005837)

Disclosure statements are at the end of this article, following the correspondence information.

Related Digital Media are available in the full-text version of the article on www.PRSGlobalOpen.com.

spinal infection is limited.⁴ This article describes a novel primary salvage procedure in a patient with progressive myelopathy due to acute cervical osteomyelitis caused by an epidural abscess and pyogenic spondylodiscitis using a free vascularized fibula graft (FVFG) in combination with posterior stabilization.

CASE PRESENTATION

A 56-year-old White man, taking TNF-alpha inhibitor and methotrexate for chronic psoriasis, was referred to the neurosurgical department with progressive myelopathy, sepsis, pyogenic spondylodiscitis of C4–C6, and epidural abscess with osteomyelitis in C4–C6 due to hematogenous spread of a bacterial hand infection. He was immediately treated with laminectomy of C4–C6 to decompress the medulla and temporize the infection. Two months later, he was re-admitted with kyphotic deformity, progressive myelopathy and increasing pain. computed tomography (CT) scan images showed compression of the medulla by collapse of the infected vertebral bodies (Fig. 1). Multidisciplinary evaluation concluded that a surgical procedure in combination with antibiotic treatment based on microbiological cultures was required.

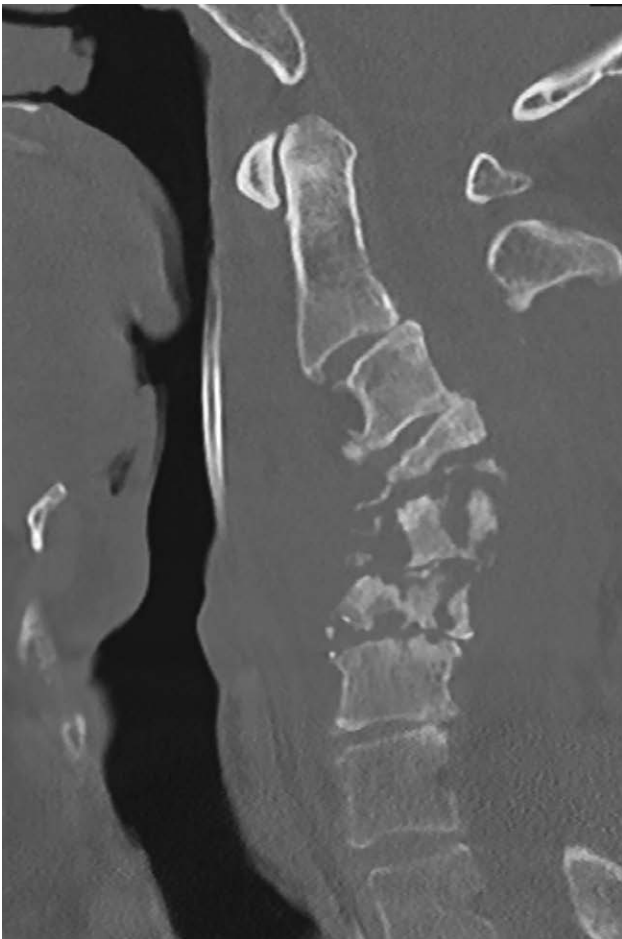


Fig. 1. The CT scan image taken the preoperative day shows collapse of infected vertebrae bodies of C3, C4, and C5, causing a kyphotic deformity leading to progressive myelopathy and pain.

Takeaways

Question: Can a free vascularized fibula graft (FVFG) with posterior instrumental stabilization be used as a primary salvage procedure in the treatment of acute cervical osteomyelitis caused by epidural abscess?

Findings: Stable reconstruction of the cervical column and infection control was obtained with the use of an FVFG in a patient with acute cervical osteomyelitis.

Meaning: An FVFG combined with posterior stabilization could be a promising primary salvage procedure in cases with progressive myelopathy caused by acute cervical osteomyelitis due to spinal infection.

The surgical procedure consisted of debridement of all infected tissue, anterior corpectomy of C4–C6, and anterior stabilization with a free microvascular fibula graft in combination with posterior stabilization. The FVFG was dissected simultaneously during cervical wound debridement. The superior thyroid artery and external jugular vein were selected as recipient vessels. The FVFG was cut down to 4.5 cm to fit the defect and anastomosed to the recipient vessels (Fig. 2). An anteriorly placed 62-mm plate was used to fix the FVFG to C3 and C7. The scheduled posterior stabilization with internal pedicle screw fixation of C2–Th2 was performed 1 week later. Microbiology of bone samples revealed *Staphylococcus aureus*, which was treated with culture-guided antibiotics. Postoperative computed tomographic angiography showed patent anastomoses and a vascularized fibula graft. Six weeks postoperatively, a cerebrospinal fluid leak and associated dorsal midline defect were closed successfully with a previously described sensate medial dorsal intercostal artery perforator (MDICAP) flap.⁵

At 5 years follow-up, the patient had radicular sequelae with reduced flexion ability in his left elbow with atrophy of the biceps musculature and reduced sensibility in the C5–C6 dermatomes. He had no signs of myelopathy, and with rehabilitation he has learned to adapt to these outcomes and manages activities of daily living. There were no donor site morbidities after fibula flap and MDICAP flap harvest. The latest magnetic resonance imaging and CT scans showed continued fusion and hypertrophy of the FVFG with the neighboring C3/C7 vertebral bodies and ample room for the medulla (Figs. 3 and 4). [See Video (online), which displays the three-dimensional CT scan reconstruction that shows the FVFG in place with the anterior and posterior stabilization.]

DISCUSSION

The reconstructive surgeon may encounter the problem of reconstructing the cervical column in case of acute cervical osteomyelitis due to epidural abscess and pyogenic spondylodiscitis. These acute cervical infections have an alarmingly high morbidity and mortality rate as compared with thoracic and lumbar infections, and a reconstructive procedure may put the critically ill, septic patient at high risk. Therefore, the reconstructive surgeon is often left with cases with progressive biomechanical instability and deformity. This may occur especially

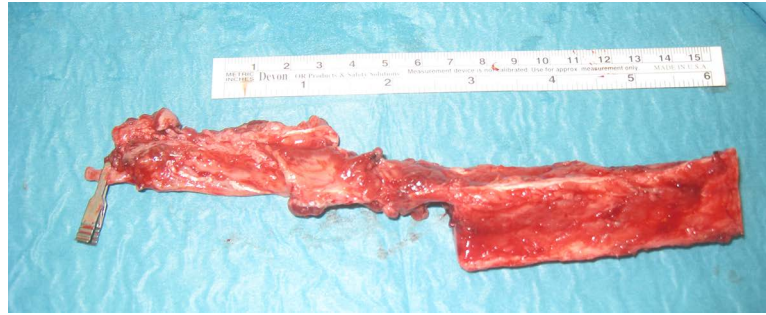


Fig. 2. The harvested FVFG before its size is reduced to fill the defect.

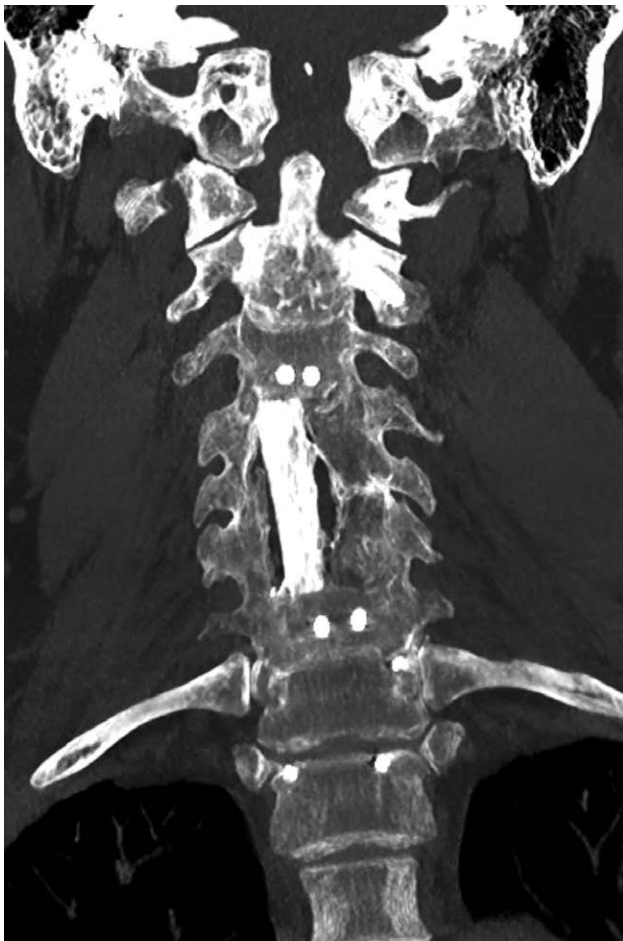

Fig. 3. The CT scan image showing the coronal projection of the FVFG fixated with the anterior plate after 5 years.

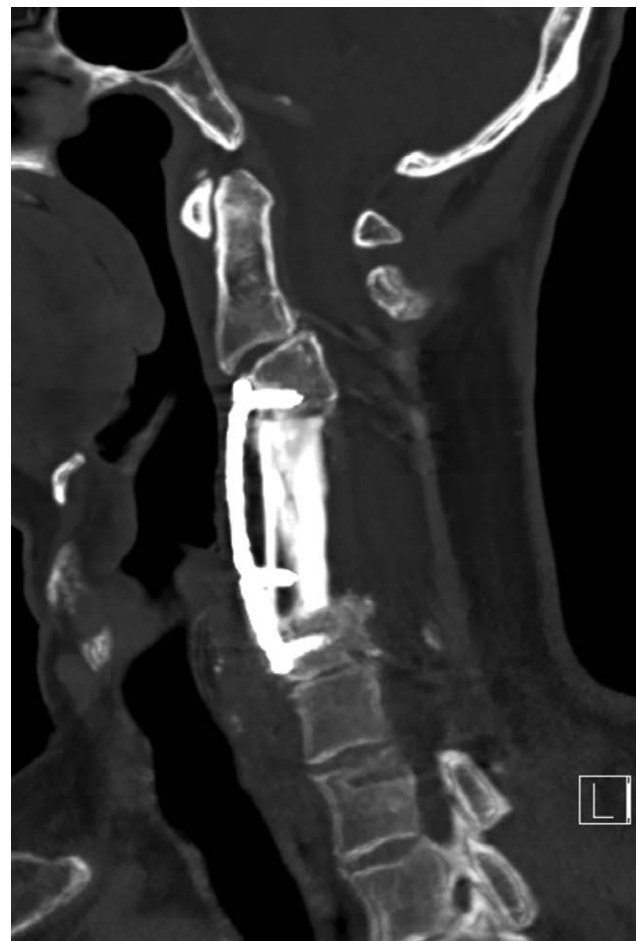

Fig. 4. The CT scan image showing the sagittal projection of the FVFG fixated with the anterior and posterior plate at 5 months.

after failed attempts with instrumentation, allografts, insertion of nonvascularized bone grafts, or having failed with previous surgical decompression or antibiotic treatment. To manage these complex cases, a high level of reconstructive expertise and multidisciplinary cooperation is required. One must control infection, obliterate dead space, provide skeletal stability for the axial load, and reduce deformity while appreciating the wide range of mobility in the neck and its compact and complex neurovascular anatomy.²

To our knowledge, there are no reports describing cervical column reconstruction with an FVFG in combination with posterior stabilization in a case of acute cervical osteomyelitis caused by an epidural abscess and pyogenic spondylodiscitis. However, reports using an autologous vascularized bone graft for other indications such as reconstruction after tumor removal, chronic infection secondary to other causes and myelopathic spinal disease have shown promising results and advantages over other alternatives.^{4,6-8} Several types of vascularized bone grafts

and recipient vessels for these free vascularized grafts have been described for cervical spine reconstruction.^{4,6} Alternatives for free vascularized bone grafts are titanium mesh cages filled with cancellous bone, tantalum mesh cages without bone, antibiotic impregnated polymethylmethacrylate, or nonvascularized fibula grafts. These nonvascularized grafts are mainly used by neurosurgeons and orthopedic surgeons.^{3,9,10} However, the FVFG has achieved growing consensus as the preferred autologous bone graft in general spinal reconstruction due to its versatility; decreased resorption and robust consolidation; low donor site morbidity; and not the least, introducing vascularized tissue to a compromised wound bed.^{4,7,8} In addition, the FVFG introduces blood circulation to the involved area and therewith an immunological response and delivery of antibiotics at the site of infection. Although the above-mentioned qualities are important, drawbacks of the free microvascular fibula graft are that it requires microsurgical skills, longer operation times, and multidisciplinary collaboration. These may not always be available.

CONCLUSIONS

An FVFG combined with posterior stabilization could be a promising primary salvage procedure in cases with progressive myelopathy and deformity caused by acute cervical osteomyelitis due to spinal infection. The blood circulation provided by the microvascular bone graft contributes to the delivery of antibiotics and an immunological response to the infected wound bed and can stimulate rapid fusion and hypertrophy over time.

Professor Louis de Weerd, MD, PhD

Department of Plastic and Reconstructive Surgery
University Hospital of North Norway
Tromsø, Norway
E-mail: louis.deweerd@unn.no

DISCLOSURES

The authors have no financial interest to declare in relation to the content of this article. This study was supported by a grant from the publication fund of UiT, The Arctic University of Norway.

REFERENCES

1. Urrutia J, Zamora T, Campos M. Cervical pyogenic spinal infections: are they more severe diseases than infections in other vertebral locations? *Eur Spine J*. 2013;22:2815–2820.
2. Ramasastry SS, Schlechter B, Cohen M. Reconstruction of posterior trunk defects. *Clin Plast Surg*. 1995;22:167–185.
3. Wang AJ, Huang KT, Smith TR, et al. Cervical spine osteomyelitis: a systematic review of instrumented fusion in the modern era. *World Neurosurg*. 2018;120:e562–e572.
4. Riasa INP, Kawilarang B. The use of free vascularized fibula graft in spinal reconstruction: a comprehensive systematic review. *Plast Reconstr Surg Glob Open*. 2023;11:e5079.
5. de Weerd L, Solberg TK, Weum S. Closure of complex posterior midline defects after spinal surgery with sensate midline-based perforator flaps and the long-term results. *Spine*. 2015;40:E1233–E1238.
6. Winters HA, Kraak J, Oosterhuis JW, et al. Spinal reconstruction with free vascularised bone grafts; approaches and selection of acceptor vessels. *Scand J Surg*. 2013;102:42–48.
7. Moche JA, Chopra K, Gastman B. Vascularized free fibula for cervical spine reconstruction following complicated retropharyngeal abscess. *Otolaryngol Head Neck Surg*. 2011;145:178–199.
8. Lee MJ, Ondra SL, Mindea SA, et al. Indications and rationale for use of vascularized fibula bone flaps in cervical spine arthrodeses. *Plast Reconstr Surg*. 2005;116:1–7.
9. Yang SC, Chen HS, Kao YH, et al. Single-stage anterior debridement and reconstruction with tantalum mesh cage for complicated infectious spondylitis. *World J Orthop*. 2017;8:710–718.
10. Barrett RJ, Sandquist L, Richards BF, et al. Antibiotic-impregnated polymethylmethacrylate as an anterior biomechanical device for the treatment of cervical discitis and vertebral osteomyelitis: technical report of two cases. *Turk Neurosurg*. 2014;24:613–617.