



## **Master thesis**

# **Classification of severe tooth discolorations and treatment options**

Lotte Jenssen and Huy Quoc Tran

Supervisor: Catarina Wallman



**Universitetet i Tromsø  
Det helsevitenskapelige fakultet**

Institutt for Klinisk Odontologi

Juni 2011

## Abstract.

In this literature study, a classification of severe discolorations and a summary over the options for different dental treatments have been described. Various causes of these severe discolorations are presented and how the mechanisms behind tooth discolorations affect the outcome of a treatment or treatment options. Finally, the aesthetic outcome of a possible bleaching treatment of the different classified discolorations is discussed.

In the management of patients with stained teeth it is very important to know and understand the mechanisms behind tooth discolorations as well as the clinical features of different types of tooth staining, in order to make a correct diagnosis.

The teeth are an integrated part of facial aesthetics and are involved in a complex social, cultural and psychological interaction. For people with severe discolorations, bleaching can be an important and valuable treatment.

Brown and yellow staining are easier to change compared to grey and blue stains which are mostly resistant to bleaching. Discolorations located in the gingival area have a poor prognosis. However, recent research has shown that for example tetracycline-stained teeth that often have a grey-blue staining may demand longer bleaching treatments, from one to 12 months, but it is almost impossible to predict the result of such a treatment. Clinical research has shown that it is best to try bleaching first, as a patient may be pleased with the outcome of this treatment and thus the need for veneers or replacement with full crowns will be eliminated.

There are no guidelines telling the dental practitioner when it is correct to carry out bleaching or operative treatment. Therefore, in cases with aesthetic problems, it is important to understand the self-perceived opinion of the patient in the treatment planning.

## Acknowledgement.

**We would like to thank our supervisor Catarina Wallman for all the valuable help and guidance with the master thesis.**

I, Lotte Jensen, would like to thank my family and friends for support and encouragement.

I, Huy Quoc Tran, would like to dedicate this thesis to my Dad who passed away on July 13, 2000. I miss him every day, and I know that he saw this process through to its completion. He is always on my mind.

I wish to thank my Mom for giving me a life of love, unconditional support and encouragement along the way.

I would like to express my gratitude to my sister and her family for offering the support to make it possible, as well as plenty of friendly encouragement.

I have to pay tribute to the support and encouragement of my beautiful wife, Linh. My thanks to her for giving me a love of life, through good times and bad, her kindness and extensive support have been ever-present in my life, for which I am eternally grateful.

My thanks to our lovely daughter, Christina Thy Thy for inspiring me to hold tight to my position no matter how complicated it gets.

Finally, I wish to thank my friends for support and love.

Content

- Abstract. .... 2
- Acknowledgement..... 3
- 1.0 Introduction..... 5
- 2.0 Aims of the study..... 6
- 3.0 Methods..... 6
- 3.1 Literature study..... 6
- 4.0 Tooth structure and color perception. .... 7
- 5.0 Classification of discolorations. .... 9
- 5.1 Intrinsic discoloration..... 10
- 5.2 Internalized discoloration. .... 10
- 5.3 Brief medical history. .... 11
- 6.0 Treatment..... 25
- 6.1 A brief history of tooth bleaching. .... 26
  - 6.1.1 The bleaching materials and their mechanism..... 26
  - 6.1.2 Systems. .... 27
  - 6.1.3 Side effects and recommended treatment. .... 28
  - 6.1.4 Efficacy..... 30
- 6.2 Microabrasion. .... 30
- 6.3 Treatment options. .... 31
  - 6.3.1 Alkaptonuria –management..... 31
  - 6.3.2 Congenital erythropoietic porphyria –management..... 31
  - 6.3.3 Congenital hyperbilirubinaemia –management..... 31
  - 6.3.4 Amelogenesis imperfect –management..... 31
  - 6.3.5 Dentinogenesis imperfecta – management. .... 32
  - 6.3.6 Tetracycline – management. .... 32
  - 6.3.7 Fluorosis – management. .... 33
  - 6.3.8 Pulpal haemorrhagic product – management..... 33
  - 6.3.9 Enamel hypoplasia –management. .... 34
  - 6.3.10 Tooth wear and gingival recession – management..... 34
- 7.0 Discussion. .... 34
- Annex – photos, figures and tables. .... 37
- References..... 48

## 1.0 Introduction.

The tooth has three distinct layers; the enamel which covers the crown, the root cementum on the root surface and an inner layer of dentin in the crown and the root. The pulp, which contains arteries, veins and nerves, is in the inner part of the tooth. Any changes of these structures is likely to cause an alteration in the outward appearance of the tooth caused by changes of its light transmitting and reflecting properties [1].

Some discolorations are located on the outer surface of the tooth structure, others are caused by stain taken up by the enamel or dentin, and some occur during tooth development and result in an alteration of the light transmitting properties of the tooth structures. Tooth discolorations are caused by multiple factors; medications, genetic defects, diseases, trauma, caries and normal aging processes are some examples.

Tetracyclines were introduced in 1948 as a broad-spectrum antibiotic. One of the side-effects of tetracycline is its incorporation into tissues that are calcifying at the time of their administration [2]. In the early 1960's, clinical evidence began to appear suggesting that tetracyclines could cause tooth discolorations, and it is now well-recognized, that they result in discolorations of the tooth substance when administered during tooth development [3].

Today we still meet young people with these types of discolorations with a past medical history with tetracyclines or other systemic medications that have these side-effects. Health care professionals who are prescribing medications should be aware of the fact that special drugs can induce changes of the tooth substance and know how to avoid the problem if possible. But - we also know that the prescribing is not always because of incompetence, but rather that they have no other alternatives.

Tooth discolorations are associated with many clinical and esthetical challenges. They can have an impact on a person's self-image and self-confidence in today's society, where most people place tooth color high. As dental students we are interested in the knowledge that can help these patients with a correct diagnosis and the choice of the most conservative

treatment plan with an aesthetic outcome that is acceptable to the patient and the dental practitioner. This information is also important in order to explain the nature of the condition to the patient and to give him/her help to prevent or limit existing tooth discolorations, and when to consider whether or not to treat the condition.

In order to make a correct diagnosis when examining a stained dentition, it is important to know the etiology and the appearance of various types of tooth staining.

## 2.0 Aims of the study.

The aims of this paper are to give a classification of severe tooth discolorations and a summary over options for different dental treatments. We will also discuss the causes of these severe discolorations, the correct diagnosis and possible treatments.

We have searched the literature to investigate if the mechanism behind discolorations affects the outcome of a treatment, or influences the treatment options. We also wanted to find information about the aesthetic outcome of a bleaching treatment on the different classified discolorations.

## 3.0 Methods.

### 3.1 Literature study.

A Medline search for clinical and in vitro studies in English between 1962 and 2011 was performed and the following keywords and titles were used: discoloration, tetracycline discoloration, tetracycline side-effects on teeth, drug-related tooth discoloration, bleaching, vital tooth bleaching, porphyria, amelogenesis imperfecta, osteogenesis imperfecta, dentinogenesis imperfecta, congenital hyperbilirubinaemia, microabrasion, tooth staining, tooth whitening, fluorosis, intrinsic discoloration, extrinsic discoloration, internalized discoloration.

Studies we included: Critical reviews, longitudinal studies and case reports. When there was limited literature to find on a topic, case reports were used. Rare inherited medical

conditions are only classified and mentioned in the text. We have also used relevant books to complement some topics.

#### 4.0 Tooth structure and color perception.

As earlier mentioned a tooth consists of enamel, dentin, cement and pulp tissue. The structure is layered, with an outer layer consisting of enamel supported by the underlying dentin. Enamel and cementum meet in the cemento-enamel junction (CEJ) on the root surface. The anatomic crown is above the CEJ and enamel covers this part of the tooth. The cementum covers the anatomic part of the root and is found below the CEJ. Most of the root composes of dentin.

The normal dental pulp consists of pulp chamber filled with soft connective tissue.

Dental enamel is a highly mineralized acellular tissue in which microscopic calcium phosphate crystals comprise of some 99% of the dry weight. The crystals resemble the mineral hydroxyapatite,  $\text{Ca}_{10}(\text{PO}_4)_6(\text{OH})_2$  in a way that the calcium, phosphate and hydroxyl ions are arranged in a repeating pattern in the crystal lattice structure. Inclusions of carbonate, sodium, fluoride and other ions make it an impure form of the mineral. The space between the crystals is occupied by water (11% by volume) and organic material (2% by volume)" [4].

The dentinal cells, the odontoblasts, produce dentin. Dentin is comprised of 70% by weight (50% by volume) mineral and 20% by weight (50% by volume) organic matrix [4]. Hydroxyapatite is the mineral phase. The apatite crystallites are held together by collagen. Thus, the structural backbone of dentin is collagen [4]. The dentin consists of dentinal tubules, microscopic canals, that run from the pulp to the enamel and the odontoblasts have cellular extensions into these dentin tubules.

The cementum that covers the root is less mineralized than enamel and dentin and as a result of this, the cementum is also softer.

The pulp chamber is the cavity centrally in dentine, and in the coronal part of the tooth. It has roughly the same shape as the outer form of the tooth, but is about four times smaller. The pulp chamber is connected with the root section via root canal(s) and leaves the tooth at the apical foramen, an opening in the apex of the tooth. As people get older the pulp chamber becomes gradually smaller and this is caused by dentin deposited along the periphery of the pulp, the so called secondary dentin - an age phenomenon. Primary and secondary dentins are types of dentin formed by primary odontoblasts, before and after the termination of root development. When the odontoblasts produce *new dentin* in response to an irritation or an injury, this is called tertiary dentin [5]. The development of these types of hard tissue leads to an increase in dentin thickness [5]. Stimuli that can initiate the formation of tertiary dentin are: attrition, abrasion, erosion, preparation, micro-leakage, progressing caries and trauma.

A variety of colors can typically be seen in a tooth and from the gingival margin to the incisal edge of the tooth a gradation of the color occurs [1]. Normal enamel is colorless and translucent, and the color of the dentin is mainly responsible for the color of the tooth [4]. The dentin influences more on the tooth color where it consists of thick layers and where the enamel layer is thin.

The composition of tooth structures will also affect the outward appearance of a tooth. If structures like the enamel, the dentin or the pulp changes, the light transmitting and light reflecting properties of a tooth are likely to be altered [1].

Different light sources in the clinic are known to have an effect on the practitioners' color perception. Three light sources are commonly found in the clinic: natural, fluorescent and incandescent light. The fluorescent light source will emphasize the blue-green end of the spectrum and incandescent will accentuate morning and late evening sunlight which has a red-orange hue and the sky appears blue at noon. Metamerism is a phenomenon when a tooth exhibits different colors, as light is composed by different wavelengths and the tooth is viewed under different conditions. To reduce the effect of metamerism a standardized light source should be used when judging the colors of the teeth [1].



Hue, value and chroma are terms that can be used to describe colors. Hue distinguishes between different families of colors (red, blue and green). The lightness and darkness of a color is described as value, while chroma is the degree of color saturation, the strength of a color (for example from pink to crimson). Opacity/translucency have been suggested to be added to the color system [1].

## 5.0 Classification of discolorations.

The different discolorations may be divided into three main types, intrinsic, extrinsic and internalized.

*Intrinsic discolorations:* the structural composition or thickness of the dental hard tissue is changed [1]. Chromogenic material is present within the enamel or dentin, incorporated either during the odontogenesis or after eruption [6]. Intrinsic discolorations can be divided into two groups, systemic and local causes. Systemic causes are separated into genetic defects or drug induced. The developing dentition can be affected of a number of metabolic diseases and systemic factors.

Local causes are for example pulpal haemorrhagic products, root resorption and ageing [1].

*Extrinsic discoloration:* the discoloration is on the tooth surface or in the acquired pellicle and is easily removed by polishing [6].

*Internalized discoloration:* during the tooth development extrinsic stain is incorporated within the tooth substance [1]. Dental defects permitting the entry of chromogenic material can be classified under developmental and acquired defects [1].

Below follows a list of causes of severe tooth discolorations.

## 5.1 Intrinsic discoloration.

Systemic causes:

Genetic defects.

**5.1.1 Alkaptonuria.**

**5.1.2 Congenital erythropoietic porphyria.**

**5.1.3 Congenital hyperbilirubinaemia.**

**5.1.4 Amelogenesis imperfecta. (AI)**

Syndromes associated with AI; [7]

Tricho-dento-osseous syndrome.

Cone-rod dystrophy.

Kohlshütter-Tönz syndrome.

McGibbon syndrome.

Vitamin D-dependent rickets.

Vitamin D-resistant rickets.

**5.1.5 Dentinogenesis imperfecta.(DI)**

Syndromes associated with (DI); [7]

Osteogenesis imperfecta,

Ehlers-Danlos syndrome,

Goldblatt syndrome,

Schimke immunoosseous dysplasia.

Drug induced.

**5.1.6 Tetracycline staining.**

**5.1.7 Ciprofloxacin.**

**5.1.8 Fluorosis.**

Local causes:

Acquired.

**5.1.9 Pulpal haemorrhagic products.**

**5.1.10 Root resorption.**

**5.1.11 Ageing.**

## 5.2 Internalized discoloration.

Developmental defects.

**5.2.1 Enamel hypoplasia.**

Acquired defects.

**5.2.2. Tooth wear and gingival recession.**

The different tooth discolorations will be supplemented with a brief medical history. The main purpose of this is to help the clinician to detect and, when possible, diagnose a specific discoloration. Ageing is an intrinsic acquired discoloration, and will shortly be described together with tooth wear and gingival recession, which are internalized discolorations.

### 5.3 Brief medical history.

#### **Alkaptonuria.**

Alkaptonuria is an autosomal recessive disorder of tyrosine degradation pathway, with an incidence of one case to one million people worldwide [8].

Alkaptonuria is characterized by deficiency of a hepatic enzyme, homogentisate 1,2-dioxygenase (HGD), which helps break down homogentisic acid (HGA), a step on tyrosine degradation pathway [8]. Mutations in HGD gene impair this role of the enzyme [8], and resulting in accumulation of HGA and its oxidized product [8]. Excess of these substances are deposited in the body, causing a grey to bluish black pigmentation of the sclerae and ears [9]. Almost all patients with alkaptonuria suffer degeneration of joints, especially in the spine, and later also knee, hip and shoulder [8].

According to a case report [9] this metabolic error may cause a bluish discoloration of the teeth. (See figure 1).

#### **Congenital erythropoietic porphyria.**

Porphyria is a rare condition resulting from errors in enzymes involved in haem metabolism which results in the accumulation of porphyrins and as a side-effect, discolorations of the dentition [10].

A heme molecule consists of porphyrin and the formation of heme occurs in large quantities in the bone marrow for incorporation into haemoglobin. The steps in the biosynthesis of heme require specific enzymes, and deficiencies of these enzymes result in porphyria.

Congenital erythropoietic porphyrias is a rare, autosomal recessive condition, and fewer than 100 (200?) cases have probably ever been reported. As it leads to a discoloration of the teeth, due to a deposition of porphyrin pigments, it is included in this paper.

This deficiency leads to photo-sensitivity of sun-exposed areas. Vesicles and bullae develop as well as thickening of the skin, excessive hair growth and a characteristic hypo- and hyper-pigmentation of the face and extremities. These patients can also have paleness of the oral mucosa and bluish purple discolouration of the mucosa in the alveolar bone region [11].

The high levels of porphyrine precursors are incorporated into the bone and teeth during formation. The concentration of porphyrine is much higher in the dentine than in the enamel, which may be caused by the affinity of porphyrins for calcium phosphate [11]. The deposition of red-brown porphyrin pigments in the tooth substance causes a characteristic red discoloration of the teeth, which is most marked in the cervical area and is reduced towards the occlusal surface [11]. A deep red-brown or yellow-brown discoloration (erythrodontia) can be seen in the primary dentition but the discoloration of the permanent dentition is usually less intense [11]. (See figure 2).

### **Congenital hyperbilirubinaemia.**

Hyperbilirubinemia results in elevated serum levels of bilirubin and it is chemically defined as a serum concentration of bilirubin larger than 1,5 mg/100 mL.

When serum concentrations become greater than 7.0 mg/100 mL jaundice is clinically visible. During hyperbilirubinemia bilirubin is deposited throughout the body. After remission it disappears from the soft tissues. In the hard tissues bilirubin is permanently trapped, as these tissues lose their metabolic activity after maturation [12]. When hyperbilirubinemia occurs during the period of tooth development, serum bilirubin may be deposited in the dental hard tissues and cause a green stain [13].

The diagnosis of bilirubin pigmentation is usually based on a clinical history of jaundice combined with green tooth discolorations and small enamel hypoplasias. The patient's

medical history may include biliary atresia, hemolytic disease, bile duct occlusion, absence of bile ducts, hemolysis in utero, biliary hypoplasia or cholestasis associated with sepsis.

Many different colors can be found on the teeth such as: bright yellow/green, yellow/green, olive green, bluish green, green, bright green, little yellow, grayish green, yellowish brown/deep green, dark gray/green and light brown. (See figure 3).

The pigmentation is always brightest when the tooth first erupts and fades as the child grows older. A possible explanation for these changes of the color is the change of the translucency of deciduous enamel with age, and this interferes with the transmission of the green stain from the underlying dentine [12].

### **Amelogenesis imperfecta.**

AI is a group of hereditary disorders characterized by abnormal amelogenesis, affecting both primary and permanent dentitions [14]. The condition may be associated with morphologic or biochemical changes elsewhere in the body [14]. AI can be transmitted as an autosomal dominant, autosomal recessive, X-linked or sporadic cases [14].

AI is caused by mutations in the genes that control the enamel formation. There is now known that mutations in 5 different genes are associated with AI; ENAM, AMELX, KLK4, MMP20 and DLX3 [15].

The prevalence of these conditions has been studied in a few populations, spanning from one in 700 to one in 14.000 [15].

Many classifications of AI have been designed since the first classification was introduced in 1945 [14]. In the paper from 1988 the most widely used classification system was presented [15]. It was based on phenotypes and the inheritance patterns [15]. AI is divided into four main types and then into 15 subtypes [14]. We will first describe the major types of AI, and at the end of this section we will present a Witkop's classification from 1988 and clinical description by Ng and Messer from 2009 in table 2 [15]. For clinic photos (see figure 4, 5, 6).

### Type I: Hypoplastic AI.

Hypoplastic AI is a quantitative defect of enamel due to the disturbances during the secretory stage of amelogenesis [15]. This results in insufficient protein deposition and a crystallite elongation leading to thin or pitted enamel [15]. The enamel appearance varies in different subtypes: from smooth, rough, pitted, grooved, locally hypoplastic or the tooth crown has thin enamel [15].

All of the hypoplastic subtypes are associated with esthetic problems. The pitted and local hypoplastic phenotype are associated with mild gingivitis, while the rough hypoplastic phenotype and X-linked smooth hypoplastic phenotype are associated with severe gingivitis due to the rough surface [15]. The local hypoplastic phenotype is also associated with mild tooth sensitivity [15].

The size of the crowns varies from normal to small, with no contact points between small teeth. The color varies from normal to light yellow-brown [15].

Radiographic appearance: Enamel can show normal contrast with dentine [15].

### Type II: Hypomaturational AI.

Hypomaturational AI is a qualitative defect of enamel caused by the failure of the mechanism of protein removal during the maturation stage, affecting the growth of crystallite in both width and thickness. As a result, the poorly mineralized enamel, either locally or generally, becomes mottled, rough and readily detached from the dentine. The clinical appearance varies from white opacities to yellow / brown, and the surface is soft and roughened. Dental sensitivity and open bites are common [15].

Radiographic appearance: Enamel has similar radiographic contrast as dentine [15].

### Type III: Hypocalcified AI.

The enamel thickness of this type is normal. Due to the defective mineralization the enamel often chips and readily abrades away, causing exposure of the dentine. Patients with hypocalcified AI tend to suffer from extremely poor esthetics, moderate dental sensitivity

and accumulation of a large amount of calculus. The color is ranged from yellow to yellow-brown [15].

Radiographic appearance: Enamel has radiographic contrast less than dentine [15].

#### **Type IV: Hypomaturation-hypoplastic with taurodontism.**

Hypomaturation-hypoplastic with taurodontism, (defined as teeth with enlarged and elongated pulp chambers), is autosomal dominant AI (IVA) and the enamel thickness is reduced with hypomineralized zones and pits. Clinically, molars have a taurodontic shape and the teeth can appear as white or yellow-brown and mottled and the approximal contacts can be missing [15].

Hypoplastic-hypomaturation, autosomal dominant AI (IVB) with taurodontism: the enamel is thin and hypoplastic with hypomatured areas. The teeth have also taurodontic shapes [15].

Radiographic appearance: Large pulp chambers and enamel radiodensity varies from normal to slightly greater than dentine [15].

#### **Dentinogenesis imperfecta (DI).**

Dentinogenesis imperfecta is a hereditary defect of the dentin affecting both the primary and permanent dentitions. (See figure 7).

-Classification of DI.

Type I Dentinogenesis imperfecta. (is associated with osteogenesis imperfecta)

Type II Dentinogenesis imperfecta.

Type III Dentinogenesis imperfecta [16].

Type I is caused by mutations of one of two genes involved in synthesis of collagen type I [16].

Type II and III are associated with mutations of the dentin sialophosphoprotein (DSPP) gene located among a cluster of four other genes involved in bone and/or dentin formation on chromosome 4 [16]. Collagen, mostly type I, constitutes to about ninety percent of the dentin matrix. *Osteogenesis imperfecta* (OI) is a syndrome associated with DI with a collagen mutation [7]. According to the literature 28% to 73% of individuals with OI exhibit DI type I [17].

Dentinogenesis imperfecta involves primarily the dentin, although the enamel may be thinner than normal.

Type I: roots and pulp chambers are small and underdeveloped. The primary dentition may be more severely affected than the permanent dentition.

Type II: affects only the dentin, does not give any skeletal defects and is otherwise similar to type I. It is expressed in variable ways. In some individuals you can find enlarged pulp chambers in the primary teeth.

Type III has enlarged pulp chambers [16]. Radiographically, the dentin appears very thin [1]. Because of this, all the teeth look like thin “shells”. Outward, the teeth may be similar to both types I and II. Teeth with dentinogenesis imperfecta show a variety of colors from yellow to blue-gray. The colors change depending on whether they are observed by transmitted or reflected light. They also show a high degree of amber-like translucency. The dentin is often exposed since the enamel easily fractures. The crowns wear readily and the dentin becomes stained. On radiographs the crowns usually have a normal size. In the cervical portion of the tooth there is a constriction that gives the crown a characteristic bulbous appearance. Usually the roots are short and slender with partial or complete obliteration of the pulp chambers [16]. Once the dentine is exposed, the teeth rapidly show a brown discoloration, presumably by absorption of chromogens into the porous dentin [1].

Osteogenesis imperfecta is characterized by bone fragility, growth retardation, joint laxity, hearing loss and blue sclerae [17]. The teeth show a greyish or brownish discoloration. The enamel fractures easily which results in a secondary attrition [7]. (See figure 8, 9, 10).



## Tetracycline.

Tetracycline was first introduced in 1948 as a group of broad-spectrum antibiotics for treatment of various infections [2]. The first tetracycline to be introduced was chlortetracycline, and along with oxytetracycline, tetracycline and demeclocycline these four homologues constitute the first generation tetracyclines. The second generation agents that include minocycline, methacycline and doxycycline were introduced in 1960s and 1970s. The third generation agents are glycylicyclines, presented in 1990s [18] and are still in use (Tygacil).

All of tetracycline derivatives consist of a four-ringed nucleus, and the chemical constituents attached at different positions of the nucleus result in structural variations. Different compounds have various pharmacologic properties, in regards to metabolism, absorption, plasma protein binding, excretion and degree of action against susceptible micro-organisms [19]. (See figure 11).

The first cases of tetracycline-induced discolorations were reported in 1956 and since then it is well-known and well-documented that tetracyclines have the ability to cause staining of both primary and permanent dentitions during odontogenesis. The mechanism to explain the staining by tetracyclines is its ability to form a complex with calcium ions [2], so called chelation. Tetracyclines chelates with calcium ions to form a stable tetracycline calcium orthophosphate complex. These complexes are deposited into bone and teeth. Dentine is more susceptible to staining than enamel [20].

The tetracycline-induced discoloration is permanent since dentine and enamel cannot be remodelled. The staining varies, depending on the type of antibiotic used, from yellow or grey to brown with or without banding [2]. Chlortetracycline causes for example a grey-brown discoloration, whereas tetracycline, dimethylchlortetracycline and oxytetracycline give a yellow discoloration. Oxytetracycline is the least discoloring [21]. (See figure 12, 13).

The affected teeth tend to be yellow on eruption and after exposure to light, the fluorescent yellow staining changes to non-fluorescent brown color with time. Especially teeth that are exposed to light will darken, possibly, because of the breakdown of tetracyclines due to the light exposure [21].

The severity of the staining is related to the time of the administration, dose, frequency, duration of administration and the stage of odontogenesis. The primary teeth begin the calcification stage at about the end of the fourth month of gestation and ends at 11-14 months of age [2]. The calcification of the permanent dentition begins after birth and can therefore not be affected by prenatal administration of tetracycline. The permanent teeth continue their calcification until 8 years of age, except for the third molars.

Therefore, tetracycline should be avoided for pregnant women during the second and third trimester of pregnancy and for children up to the age of eight [2]. The staining takes place more frequently in the developing dentition when the total dosage is over 3g, or the administration exceeds 10 days [3].

Tetracycline discoloration is classified according to the extent, degree and location of the staining [22]:

1. First degree. Mild tetracycline staining. This staining is minimal expression of tetracycline. Varies from yellow to grey with no banding.
2. Second degree. Moderate tetracycline staining. Yellow-brown to dark grey banded staining.
3. Third degree. Severe tetracycline staining. Blue grey or black with significant banding across the tooth.
4. Fourth degree. Extended and more severe staining.

Minocycline, a tetracycline derivative used for the treatment of acne vulgaris, respiratory diseases and rheumatoid arthritis, has also the ability to cause pigmentation of skin, nails, bone and teeth [22]. The picture varies from a green-grey to blue-grey post-eruptive discoloration [3]. Minocycline is well absorbed from the gastro-intestinal tract and chelates with iron ions to form complexes that are insoluble and may cause the discoloration [2].

There are two other theories of the mechanism of staining; the extrinsic and intrinsic factors. "The extrinsic theory is based on that minocycline is excreted in a high concentration in the gingival fluid", and can stain the enamel "by diffusing through the pulp or by affecting odontogenesis". The intrinsic theory proposes that minocycline is absorbed and bound to plasma proteins and distributed to tissues with high affinity for minocycline [2]. This discoloration appears to happen in 3-6% of patients who are on long-term minocycline

therapy with more than 100 mg per day. The onset of staining can vary from one month to many years after the start of therapy [3].

## **Ciprofloxacin.**

Ciprofloxacin is a synthetic antibiotic of fluoroquinolone drug class introduced in 1981 [19]. It is used in treatment of infections with Klebsiella (can cause pneumonia) [3]. According to a case report from 1991 [23] ciproflaxacin has association with greenish discoloration of teeth.

## **Fluorosis.**

An excess ingestion of fluoride that induces multiple changes in the developing enamel [24].

Amelogenesis: The ameloblasts pass through several stages of differentiation and the pre-secretory ameloblasts differetiate into secretory ameloblasts.

The secretory ameloblasts deposit a protein matrix, which acts as a temporary protein platform on which the enamel crystals can form. An aprismatic thin layer of enamel is first deposited against the dentin. Fully differentiated secretory ameloblasts with Tomes' processes deposits the bulk (inner) layer of the enamel. Protein matrixes, predominantly amelogenins, are secreted into the enamel space by these cells. The ameloblasts lose their Tomes' process and deposit a layer of aprismatic enamel with small crystals. The cells transform into maturation ameloblasts and the enamel matrix proteins are gradually removed from the matrix during this stage.

In the maturation stage, matrix proteins are removed from the extracellular space, and mineralization increases progressively until the tooth erupts [24].

The ingestion of fluorides is particularly important in infants as dental fluorosis can only originate during the tooth development [4]. There are various sources of fluoride in the environment and fluorides can be delivered through water, supplements, milk and salt or through oral care products as toothpastes, gels, varnishes, paint-on applications and mouth

rinses. Fluorides occurs naturally, usually at very low doses in water supplies, mostly less than 0,5-0,7 mg/l. If a mother has a high intake of fluoride, it is poorly transported from plasma to milk, but a child may ingest high amounts of fluoride through milk formulas, if these are prepared with fluoride-containing water. The limit value for fluoride is 1.5 mg/l in water supply in Norway. Plants exposed to fluoride in the soil or water supplies containing high levels of fluoride may also contain significant amounts of fluoride. Fresh water fish and tea are other examples of fluoride sources. A cup of tea may contain a fluoride concentration of 0,5-4 mg/l partly depending on the water that is used. It is important to think of the total intake of fluoride that (adults and) especially children ingest through water, food and dental products [4].

Fluoride is highly reactive and reacts rapidly with mineralizing tissues. One can say that fluoride will gradually be incorporated into the crystal lattice structure in the form of fluorhydroxyapatite, and be stored in bones and teeth. «..the higher the dose of fluoride occurring during the tooth development, the higher the concentration of fluoride is to be found in enamel» [4]. The amount of fluoride exposure is reflected in the different layers of the enamel.

There have been various explanations for the mechanisms behind dental fluorosis. Based on present evidence, «a slight excess of fluoride ions affects the rates at which enamel matrix proteins break down and/or the rates at which the by-products from this degradation are withdrawn from the maturing enamel» [4]. Interference with removal of the enamel matrix could inhibit crystal growth during maturation and this in turn could lead to incomplete mineralization. The enamel organ cells and their proliferation and differentiation are, however, not affected.

According to a review, Aoba and Fejerskov (2002), fluoride may modulate the kinetics of enzymic degradation of the matrix proteins in the extracellular environment and may indirectly interfere with protease activities by decreasing the free calcium ion concentration in the mineralizing environment [4].

Disturbances in the formation of the enamel may be seen as opacities reflecting the porosities of the fluorosed enamel. These are seen as “thin, white, opaque lines

corresponding to the perikymata running across the tooth surface” [4]. The enamel porosity, which is a result of a hypomineralization of the enamel, is seen along the stria of Retzius. Posteruptively, this chalky white enamel may change to more severe forms of fluorosis depending on the degree of hypomineralization which is a result of posteruptive mechanical damage such as mastication, attrition and abrasion [4].

Thylstrup & Fejerskov (1988) have classified fluorosis according to the scored severity from 0 to 9. (For TF-index and photos see figure 14 and 15).

### **Pulpal haemorrhagic products, pulp necrosis, pulp tissue remnants after endodontic therapy and their possible effect on tooth color.**

Tooth discolorations can be caused by blood components, by-products from hemolysis of red blood cells, pulpal tissue remnants, filling materials or sealer remnants that penetrate deep into the dentinal tubules.

Trauma, crown preparation or vibrations from the bur that cause a rupture of the blood vessels and the accumulation of hemoglobin or other hematin molecules can result in discoloration of the tooth substance [6]. (See figure 16 and 17).

If pulp remnants remain inside the pulp chamber after endodontic treatment, this can cause a coronal discoloration due to a gradual disintegration and flow into the dentinal tubules [6].

When filling materials and sealer remnants or medicaments containing tetracycline that are not completely removed from the pulp chamber after endodontic treatment are in contact with dentin over time, they can penetrate into the dentin tubules and discolor the tooth.

An internal bleeding directly after a full crown preparation is characterized by a pink discoloration of a tooth with a vital pulp. This intrapulpal bleeding with blood cells penetrating the dentin can also be caused by vibrations created by, for example, an eccentrically rotating bur [5].

The discoloration of a necrotic tooth caused by a trauma will become more severe over time. If the trauma does not cause a pulpal necrosis, the discoloration can be reversed. If the tooth becomes revascularized the pinkish hue that was seen initially after a trauma might disappear in 2-3 months [6].

On the other hand: If a color change of a tooth crown is yellow, this can be a sign of excessive dentin formation and narrowing of the pulpal space. It can often be seen after a minor trauma, mainly luxation injuries) [5].

### **Root resorption.**

Root resorption is a removal process, pathologic or physiologic, of tooth structure by odontoclasts [16]. This process can be classified based on location, internal if the root resorption begins at the pulpal aspect, and it is known as external if the process is started from the outside of the root.

The etiology of root resorptions requires two phases: injury and stimulation. Injury is related to the non-mineralized tissues; cementum or dentine, and may be a consequence of a dental trauma, surgical procedures, excessive pressure from orthodontic treatment or from an impacted tooth or tumour [25].

Injured tissues are then colonized by multinucleated cells, osteoclasts that begin a localized inflammatory response and the resorption process. Whether the active resorption process will continue or not, it depends on a stimulation factor of osteoclasts, either in form of infection or pressure. The process will stop without further stimulation of the resorption cells. In about 2-3 weeks the repair with cementum-like tissue will take place, and no treatment is needed. If the damage on the root surface is severe the osteoclasts will be able to attach to the dentine of the root before the cementum-producing cells, resulting in ankylosis [25].

The most common stimulation factor is a pulpal infection. Due to injury to the cementum or dentine, dentinal tubules become infected, and this can stimulate the inflammatory process with osteoclastic activity in the periradicular tissues, leading to external or internal root

resorption. The treatment for the internal resorption is pulpectomy, removing the resorbing cells (of pulpal origin) and their blood supply [25].

If there is an external root resorption it is important to control the pulpal bacteria that act as stimulation factor. It is recommended to treat the tooth endodontically with calcium hydroxide for 6-24 months in order to arrest the resorption process [26]. The reason is that calcium hydroxide has an antibacterial effect and low solubility, giving a long-term effect in the root canal, and a removal the stimulation from the canal [25].

External root resorption may occur after an injury to the cementum, apical to the area of the bacterial stimulation originating from the periodontal sulcus [25]. Internal root resorption takes place within the pulp cavity or root canal and involves the dentinal wall. The result is that the pulp space becomes bigger. It happens that the enlarging pulp perforates the dentine and enamel becomes involved. It may appear clinically as a *pink spot* [16].

### **Ageing.**

As a person gets older, secondary dentine naturally gets deposited in the tooth, and the enamel can become thinner. When the enamel gets thinner, more color of the darkened dentine reflects. This can result in a gradual darkening of the color of the teeth with age [1]. (See figure 18).

### **Enamel hypoplasia.**

Enamel hypoplasia is a condition of deficient amelogenesis, resulting from an injury to the formative cells, the ameloblasts . A consequence of this is less quantity of enamel formation than normal. The prevalence varied from 3 to 15% of young adults having EH in the permanent teeth [27].

Hypoplasia of primary teeth is rarely as severe as in the permanent teeth [28]. Enamel hypoplasia may be localized or generalized [1]. Trauma and localized infections in the primary dentitions are the most common reasons to EH [27]. Turner´s hypoplasia is a

common term for EH where an apical localized infection in the deciduous dentition has caused disturbances of the normal amelogenesis. The infection destroys the enamel epithelium, and the inflammation interferes with normal calcification [28].

Generalized EH may be the result of any disturbance caused by foetal or maternal conditions such as maternal vitamin D deficiency, rubella infection, drug intake during pregnancy or paediatric hypocalcaemic conditions. These defects are related to the degree of the systemic upset, and is chronologically laid down in the teeth according to the time of interferences [1].

The quantitative defects of EH on the tooth surface appear as thin, or pitted - single or multiple, shallow or deep, or scattered or arranged in horizontal rows, or grooved – single or multiple, narrow or wide, or evident as partial or total absence of enamel over substantial areas [29]. The pits and grooves are exposed to extrinsic staining of the enamel and it often becomes internalised [1]. The thickness of the enamel is reduced, and may be translucent or opaque [29].

Another interesting developmental dental defect in this context is molar-incisor hypomineralization, MIH, which has a different clinical appearance. MIH presents as demarcated opacities, resulting from incomplete mineralization and is a qualitative defect, in the permanent first molars and incisors. Demarcated opacities have a clear and distinct boundary to the near areas of normal enamel. They vary from white, yellow to brown in color, and do not always appear symmetrically. The number of affected teeth also varies. In addition, the affected teeth at times undergo post-eruptive break-down due to soft and porous enamel [29].

EH and MIH can be difficult to differentiate diagnostically if the affected molars have a post-eruptive break-down caused by caries or trauma from masticatory forces. EH and MIH can occur together, especially at a histological level [30].



## Tooth wear and gingival recession.

Tooth wear is a progressive loss of the outer layers of the enamel and dentine caused by erosion, abrasion and (or) attrition [1], while gingival recession is a condition characterized by retraction of the gingival margins, which expose the root surface of the tooth. Gingival recession is usually associated with pathological alveolar bone loss at that site [31].

As the enamel gets thinner the teeth become darker. The color of the dentine becomes more apparent and if the enamel fractures, secondary attrition can occur faster, the dentine will be exposed and the color changes to a darker degree in this area. Other factors that might change the color of the teeth are fractures, loss of enamel or enamel cracks, as stains are included into the body of the tooth.

Some factors that contribute to tooth wear are causes that naturally occur as a result of ageing. Examples can be attrition and erosion that also are stimulus that can initiate the formation of tertiary dentin. Secondary dentin is naturally formed and deposited as a result of age. This increased thickness of dentin will gradual darkens the teeth. Therefore, is aging itself is a factor that will influence on tooth color. (See section 5.1.11).

Gingival recession: When a tooth has a gingival recession, the cervical area will be exposed. The enamel layer is thin in this area, so the dentin underneath the enamel is showing through the enamel and influences more on the tooth color. The teeth become darker as the enamel thins. The cementum covering the exposed root will be lost over time. Once the dentine is exposed, the inclusion of chromogens in the tooth substance increases [1]. (See figure 19).

## 6.0 Treatment

*If a patient wants to treat discolorations of his/her teeth, and bleaching can give a good aesthetic result, this will also be the most conservative treatment (plan) we can offer.*

Therefore we start this chapter by writing a brief history and facts of bleaching.

## 6.1 A brief history of tooth bleaching.

In 1916, the use of hypochloric acid was used to treat fluorosis by Adams. A technique used by Ames in 1937 to treat mottled enamel (fluorosis), was done over 5 to 25 visits. A mixture of hydrogen peroxide and ethyl ether on cotton, heated with a metal instrument for 30 minutes was applied on the tooth. The same technique was used in 1942 by Younger to treat dental fluorosis on 40 children. Since 1930 the use of concentrated hydrogen peroxide and heat has been an accepted treatment. The combination of hydrochloric acid and hydrogen peroxide for removing brown stain from mottled teeth was used in 1966. In 1970 a method for whitening tetracycline-discolored dentin was published and this was the first publication indicating that there is chemical penetration of hydrogen peroxide to the dentin to whiten teeth [32].

A custom-fitted night guard with proxigel (which also contain 10% carbamide peroxide) was made by Klusmeier in 1972, and "the walking bleach technique" for whitening nonvital teeth with the use of 35% hydrogen peroxide and sodium perborate was introduced in 1976.

10 % carbamide peroxide was introduced and commercially available in 1989. The first study with the "night guard vital bleaching" technique using 10% carbamide peroxide was published by Haywood and Heymann in 1989 [32].

Currently available peroxide-containing tooth-whitening materials include professionally dispensed and supervised products for use by patients at home, professional-use in-office products, and over-the-counter products for sale directly to consumers [32].

### 6.1.1 The bleaching materials and their mechanism.

Bleaching gels usually contain either carbamide peroxide ( $\text{CH}_6\text{N}_2\text{O}_3$ ), hydrogen peroxide ( $\text{H}_2\text{O}_2$ ) or non-hydrogen peroxide chemicals [33].

A 10 % gel of carbamide peroxide breaks down to 3.35% hydrogen peroxide (H<sub>2</sub>O<sub>2</sub>) and 6,65% urea (CH<sub>4</sub>N<sub>2</sub>O). Ten, 15% or 20% gels of carbamide peroxide or lower concentrations of hydrogen peroxide are available for home bleaching instructed by a the dental personell.

For treatments in office, the dentist can use a gel of very strong carbamide peroxide or hydrogenperoxide [33].

According to Kihn [32] hydrogen peroxide is an oxidizing agent that, as it diffuses into the tooth, breaks down to produce unstable free radicals. These unstable free radicals attack organic pigmented molecules in the spaces between the inorganic salts in tooth enamel resulting in smaller, less heavily pigmented constituents. These smaller molecules reflect less light, thus creating “whitening effect”.

The mechanisms of Non-hydrogen peroxide containing materials are that the moist tooth structure and the gel interact and activate the gel. “The oxygen complex interacts with the tooth structure and saturates and changes the amino acids and double bonds of oxygen which are responsible for tooth discoloration” [33].

Constituents of the bleaching gels: carbamide peroxide, hydrogen peroxide, non-hydrogen peroxide containing materials, thickening agents, urea, vehicle, surfactant, preservatives, flavourings.

### 6.1.2 Systems.

Three main methods for bleaching are used; dentist-supervised night guard bleaching, in office or power bleaching and bleaching with over-the-counter bleaching products [32].The treatments recommended and performed by a dentist are described.

Combination treatment: Application of high concentration bleaching material in the office and a take home system is an example on a combination treatment that can be used [32].

Intracoronall bleaching: “Intracoronall bleaching of non-vital teeth involves the use of chemical agents within the coronal portion of an endodontically treated tooth to remove

tooth discoloration” [33]. Examples of these techniques are the walking bleach technique, thermocatalytic technique and inside/outside technique.

The in-office procedures can also be applied when the walking bleach technique does not give satisfactory results after 3-4 applications. In the review from Plotino et al (2008) they found reports that recommended treating the access cavity with 37% orthophosphoric acid to remove smear layer and to open dentinal tubules so the bleaching material could enter deep into the dentinal tubules [6].

Other recommendations were cleaning the pulp chamber with alcohol, the surface tension was then reduced and the dentine dehydrated, so the bleaching entered with ease into dentin. However, removal of smear layer haven't show any increase in efficiency in studies. And bleaching materials may diffuse into the periodontium with pre-treatment of acid. A cervical sealing material is important to prevent diffusion of bleaching material from the pulp chamber into the apical foramen. Cavit and Coltosol are recommended as an effective barrier [6].

### **6.1.3 Side effects and recommended treatment.**

The most commonly reported side effects during a bleaching treatment are gingival or mucosal irritation and tooth sensitivity. Other reported side effects include sore throat, temporomandibular dysfunction secondary to long-term tray use, and minor orthodontic tooth movement [32].

Hypersensitivity is a reversible pulpitis caused by some of the byproducts that diffuse through the dentinal tubules. If glycerin is an ingredient in the whitening product, this will absorb water and cause a dehydration of the tooth. These factors contribute to induce sensitivity of the tooth which happens in 55% to 75% of the patients. Recommendations for treatment of sensitivity are fluoride gel or a potassium nitrate toothpaste in the tray for 10 to 30 minutes before use of the whitening agent [32], desensitizing agent after treatment, adjustment of application time and also use a potassium nitrate plus fluoride toothpaste 2 weeks before and during the treatment period.

The strength of enamel reduces when bleaching with peroxide. If bonding is delayed for 1-2 weeks post-bleaching with 35% solution of hydrogen peroxide, the bond strength will improve. With 10% carbamide peroxide, the practice is to wait 2 weeks, because the reduced enamel strength is also temporary in this case [33]. The effect on restorative materials has produced conflicting result in different studies. Reduced hardness of composite resin, surface cracking and influence on color are examples of results that have been presented in studies. The greatest color change found was in glassionomers [32].

To improve the aesthetic result, replacement of existing restorations or placements of veneers are done in combination with the bleaching. It should be wise to wait for two weeks before performing these techniques, because the color will stabilize and the strength of enamel will be improved [32, 33].

Studies have reported that intracoronary bleaching may induce external root resorption [33]. "Previous traumatic injury and age may act as predisposing factors" [33].

External cervical resorption is a complication to non-vital-bleaching. According to Plotino [6] several studies reporting on long-term follow-up evaluations show an association between external resorption and bleaching of nonvital teeth, even many years after bleaching. History of trauma and bleaching are the most predisposing factor for cervical resorption. Other predisposing factors for an enhanced diffusion of bleaching agents into periodontal tissue are anatomic defect at the CEJ, because this exposes dentinal tubules, lack of cervical seal, young patient and application of heat. Heat will widen the dentinal tubules and produce hydroxyl radicals from hydrogen peroxide. Connective tissue can be degraded by hydroxyl radicals [6].

Signs of cervical resorption can be swelling of the papilla or percussion sensitivity, but often is it asymptomatic [6].

One should take radiographs pre-operative to ensure that there is no periapical pathology, that the root filling is acceptable. We should be aware of the predisposing factors. We also have to check the tooth years after bleaching [33].

#### 6.1.4 Efficacy.

Generally, when comparing hydrogen peroxide containing products with carbamide peroxide containing products with equal hydrogen peroxide concentration and formulation the efficacy is very similar. Concentration and duration of application are two important factors that influence the efficacy of tooth whitening with these products [34].

Gels containing higher concentration works faster, however the bleaching efficacy of lower concentration gets near the higher concentration when the treatment time is extended. The efficacy of light-activated bleaching is limited. Another key factors that influences the efficacy is the type and severity of the tooth discoloration and the initial tooth color. Mild and moderate tetracycline discoloration may respond to longer bleaching treatments, 2-6 months. Brown and yellow staining, located in the incisal area are more responsive than the grey and blue discolorations located in the gingival region of the tooth [35].

The teeth get lighter through a whitening process and reach a maximum lightness regardless of the concentration of the agent or contact time used (lightness potential). Once the treatment is completed, the teeth will rebound by approximately a half shade, probably due to the complete rehydration of the teeth [32].

Internal discolorations caused by root canal medicaments, root-filling materials, or metallic restorations such as amalgams have however a poor prognosis. They are difficult to bleach and tend to reappear over time [6].

Haywood concludes that bleaching with 10% carbamide peroxide in a custom-fitted tray is generally the most cost-effective and safest treatment option [35].

#### 6.2 Microabrasion.

Microabrasion is a combination of chemical and mechanical technique where a microscopic layer of the enamel is eroded and abraded away. It involves the softening and removal of

both enamel and the surface defect and is accomplished with rubber dam isolation, hydrochloric acid (HCL) 18% mixed with pumice, and a special geared-down handpiece [33].

## 6.3 Treatment options.

### 6.3.1 Alkaptonuria –management.

There is no reports describing how to treat the stained teeth caused by alkaptonuria.. Bleaching should be tried first, but the blue or grey stains are difficult to change. When the stains do not respond to bleaching, they have to be either removed by abrasion or masked by restorative treatment.

### 6.3.2 Congenital erythropoietic porphyria –management.

To improve the aesthetics in teeth with red-brown porphyrin pigments deposited. The dental treatment options are crowns, facings and/or laminated veneers [11].

### 6.3.3 Congenital hyperbilirubinaemia –management.

The treatment for the condition is bleaching or placement of esthetic crowns [13].

### 6.3.4 Amelogenesis imperfect –management.

The common clinical problems are poor esthetics, tooth sensitivity, and extensive tooth wear. Management in affected children and adolescents have to be focused on improving esthetics, reducing sensitivity, correcting or maintaining vertical dimension and restoring the masticatory function [15].

AI may have psychosocial impact on young patients. Early diagnosis is therefore very important in order to offer proper preventive and restorative treatments over several phases. The “temporay phase” starts soon after diagnosis in the primary or mixed dentition and is continued with a “transitional phase”, providing the patient with a functional and esthetic permanent teeth before the “permanent treatment phase” in adulthood [15].

The treatment of different AI types depends on the AI type and the phenotype of the affected enamel. The treatment can range from preventive care using sealants, tooth

whitening, microabrasion, and bonded technique for esthetic improvement to prosthetic reconstruction [15].

### **6.3.5 Dentinogenesis imperfecta – management.**

Bleaching and prosthetic crowns.

Croll et al (1995) reported a case with successful bleaching of teeth with dentinogenesis imperfecta discoloration. They used application of 10% carbamide peroxide in a custom-tray for home bleaching. The patient wore this several hours a day in 2 weeks. Some lightening had occurred. After 5 ½ weeks the teeth were lighter and the bleaching was ended. After 6 weeks the teeth were still lighter than before the bleaching. Despite the fact that they had darkened slightly [36]. “The exact number of days and hours per day of exposure to bleach required to effectively improve appearance of teeth discolored by DI is not known” [36]. And there are still many questions about the bleaching on DI discolored teeth.

### **6.3.6 Tetracycline – management.**

Haywood has shown that tetracycline-stained teeth may respond to long bleaching treatments, some tetracycline discolorations can require from 1 to 12 months of treatment every night. Extended treatment time can give sensitivity episodes [35].

Leonard et al. (2003) stated in their study that nightguard vital bleaching indicates that tetracycline-stained teeth can be whitened successfully using a 6 month active treatment with 10% carbamide peroxide, and that shade stability may last at least 90 months post treatment [37].

The prognosis of vital bleaching is good for degree I. Degree II is more variable in the amount and location of the discoloration. The prognosis is therefore variable depending on the specific degree and intensity of staining.

Degree III is usually marked with banding. The most difficult tetracycline discolorations to treat involve banding caused by sporadic repetitive ingestion of the drug. These bands may become more evident as the lighter stains respond more effectively to bleaching [38].

Degree III and IV are severe stains and the prognosis for effective and esthetic vital bleaching is not good [38].



In cases where the teeth are severely stained in the gingival area and a bleaching treatment has no effect, porcelain veneers or placement of a crown will be options to restore esthetics and function. According to Haywood it is best to try bleaching first, and then abrasion, or bonded technique, because one of the mentioned treatment options may have a satisfactory effect and eliminate the need for more conventional treatments [35].

#### **6.3.7 Fluorosis – management.**

The choice between different treatments depends on the severity of the fluorosis and may be determined by the Thylstrup and Fejerskov index.

The aesthetic of mild fluorosis can be improved successfully with bleaching.

Moderate fluorosis can be corrected with bleaching or in combination with microabrasion.

Severe fluorosis may require porcelain laminate veneers, restorations or crowns.

#### **6.3.8 Pulpal haemorrhagic product – management.**

It has been shown that the pinkish hue seen initially after trauma might disappear in 2-3 months if the tooth becomes revascularized [6]. It is therefore wise to wait for 3 months before a bleaching treatment.

#### **Pulp necrosis.**

Intracoronally bleaching is the treatment of choice.

According to Plotino [6] trauma- or necrosis-induced discoloration can be successfully bleached in about 95% of the cases, compared with lower percentages for teeth discolored as a result of medicaments or restorations. The treatment procedure: first remove all the filling materials to a level just below the bone. Then clean the chamber with burs. And finally treat the tooth with intracoronally bleaching. The duration of discoloration and type of sealer will affect the prognosis. The chamber has to be cleaned with burs to remove all remnants before starting bleaching procedures. Stains caused by metallic ions are difficult to remove with bleaching [6].

### 6.3.9 Enamel hypoplasia –management.

Treatment options depend on the severity of EH and the symptoms associated with it.

### 6.3.10 Tooth wear and gingival recession – management.

To improve appearance of discolored roots of teeth, the exposure to bleaching materials requires usually treatments of long periods, longer than what is common for the bleaching of the enamel. (See figure 19).

## 7.0 Discussion.

It is important that patients are aware of the different treatment options available for tooth discolorations and of course the consequences of these. An effective communication between the dental practitioner and the patient will prevent many misunderstandings and disappointments with the final result.

In the management of patients with stained teeth it is very important to know and understand the mechanisms behind the tooth discoloration, and the clinical features of different types of tooth staining in order to make a correct diagnosis. As described in the classification section there are various reasons of tooth discolorations.

The reasons can be of medical, genetic, or odontological origin. A number of metabolic diseases such as alkaptonuria, congenital erythropoietic porphyria and congenital hyperbilirubinaemia can all contribute to severe tooth discolorations. Amelogenesis imperfecta and dentinogenesis imperfecta are caused by genetic disorders, while tetracycline staining and fluorosis can occur during tooth formation. Environmental and genetic factors that interfere with odontogenesis may be responsible for enamel hypoplasia.

Despite that people have severe tooth discolorations, we must also be aware that this can be experienced as normal and accepted for some people in a community. As an example we can look at communities that are naturally served by water systems with naturally high fluoride content. Specifically in areas served with borehole water, the concentration of fluoride can be high. The prevalence of dental fluorosis as a side-effect of the fluorinated

water will be high among the people living in these areas. And, they will not necessarily feel that fluorosis is an aesthetic problem, because they do not differ compared to other members of the community. The patient's perception of own teeth is a valuable information and the dentist should not cause treatment needs that are not present in patients.

The teeth are an integrated part of facial aesthetics and are involved in a complex social, cultural and psychological interaction. For people with severe discolorations, bleaching can be an important and valuable treatment. As an example dentinogenesis imperfecta leads to a deep, dark, dentinal stain. T.P.Croll reported in 1995 the successful use of carbamide peroxide at-home bleaching in a teenager, who had spent his childhood with brown teeth, and thus could have more normal teeth for his high school years, without undergoing extensive restorative dentistry [36].

Brown and yellow stainings are easier to change, while gray and blue stains are mostly resistant to bleaching and the discolorations located in the gingival area have a poor prognosis. However, recent research has shown that tetracycline-stained teeth that often have a gray-blue staining may demand longer bleaching treatments, from one to 12 months, but it is almost impossible to predict the result of the treatment. Haywood states that it is best to try bleaching first, because the patient may be pleased with the effect of the treatment and eliminate the need for veneers or replacement with full crown [35].

With minocycline, a staining might occur post eruption in previously normally coloured fully mineralized teeth on an adult patient. Some of these patients will then experience increasing gray discoloration of their permanent teeth following the minocycline therapy. Those who have suffered moderate to severe acne will probably be conscious of their appearance. And, the discolorations can be experienced as an extra burden on these patients. Bleaching is the preferred treatment option, but we also know that it works best for more uniform grey/brown stains. In some cases removal of sound tooth substance cannot be avoided to mask the discoloration.

Although the effect of a treatment is not the most desirable one and other conventional treatments are required, the patient is at least sure that the most conservative treatment has been tried first [35].

There are no guidelines telling the dental practitioner when it is correct to carry out operative treatment. Therefore, in cases with esthetic problems, it is important to understand the self-perceived opinion of the patient in treatment planning [29].

## Annex – photos, figures and tables.

**Tabell 1. Tooth development.**

### Deciduous dentition.

Tooth	First signs of mineralization.		Eruption	
	Maxilla	Mandibula	Maxilla	Mandibula
1.	5 months in utero.		7 months	
2.	5 “ “		9 “	
3.	6 “ ”		18 “	
4.	5” ”		14 “	
5.	6 “ “		26 “	

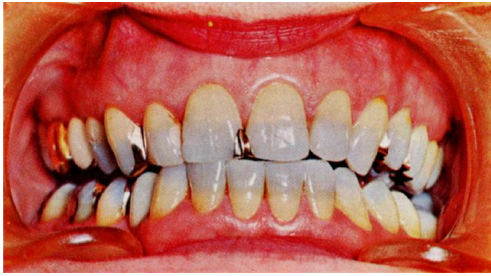The deciduous tooth's crown is under development in the period of 5 months in utero – 1 year.

### Permanent dentition.

Tooth	First signs of mineralization.		Eruption	
	Maxilla	Mandibula	Maxilla	Mandibula
1.	3 ½ months		7 ½ years	6 ½ years
2.	1 year	3 ½ months	8 ½ “	7 ½ “
3.	4 ½ months		11 ½ “	10 ½ “
4.	1 ¾ years		10 ½ years	
5.	2 ¼ years		11 years	
6.	At birth		6 ½ “	
7.	2 ¾ years		12 “	
8.	8 ½ “		18 “	

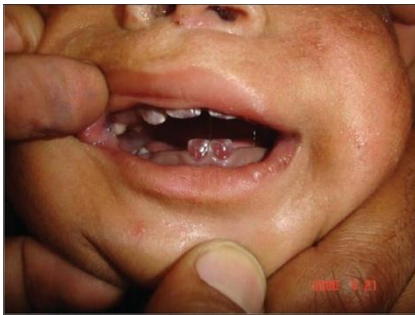The permanent tooth's crown is under development in the period from birth – 7 ½ years.[39]

### **Alkaptonuria.**



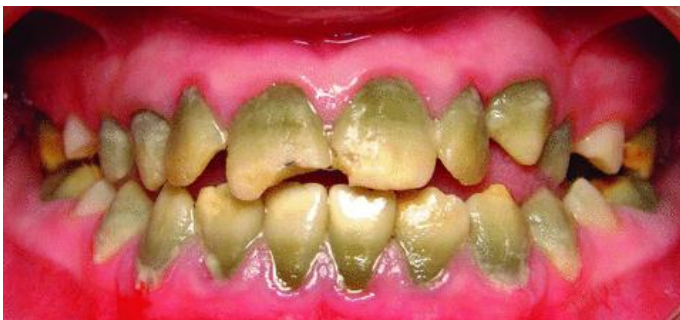**Figure 1.** Bluish discoloration of crown half of teeth. The increased density of the dentine is seen as yellow-to-brown change on the gingival half of the teeth [9].

### **Congenital erythropoietic porphyria.**



**Figure 2.** A congenital erythropoietic porphyria patient with red-brown pigments in the teeth. (<http://www.ncbi.nlm.nih.gov/pubmed/21572804>)

### **Congenital hyperbilirubinaemia.**



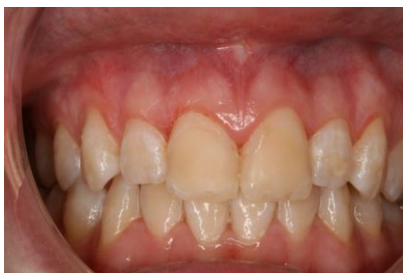**Figure 3.** Congenital hyperbilirubinaemia patient with green staining teeth.

## Amelogenesis imperfecta.

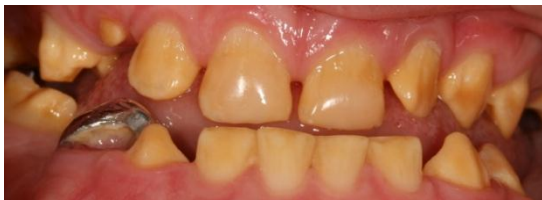Witkop's classification (1988)	Clinical description by Ng and Messer (2009)
Type I Hypoplastic: IA – hypoplastic, pitted autosomal dominant	Enamel has pits from pinpoint to pinhead size primarily on labial or buccal surfaces.
IB – hypoplastic, local autosomal dominant.	Pits and grooves horizontally across middle third of teeth.
IC – hypoplastic, local autosomal recessive.	Hypocalcified enamel may be present in hypoplastic zones
ID – hypoplastic, smooth autosomal dominant	Hard glossy enamel, but thin; contact points missing, 50% of patients have anterior open bites
IE – hypoplastic, smooth X-linked dominant	Males have thin, brown to yellow-brown enamel, females have alternating vertical bands of normal thick, and thin enamel. Anterior open bite affected most males and about 30% females.
IF – hypoplastic, rough autosomal dominant	Thin but very hard enamel, missing contact points. About 50% affected by anterior open bite.
IG – enamel agenesis, autosomal recessive	Tooth surface is rough granular, with light yellow-brown stain, missing contact points; anterior open bite is present.
Type II Hypomaturation: IIA – hypomaturation, pigmented autosomal recessive	Enamel is soft but has normal thickness, and fractures easily, mottled and agar-brown.
IIB – hypomaturation, X-linked recessive	Primary teeth have glass white enamel, and permanent teeth have mottled yellow enamel.
IIC – snow-capped teeth, X-linked	Opaque white enamel on the incisal or occlusal surfaces 1/3 to ¼ of crowns.
IID – snow-capped autosomal dominant?	Same as IIC

Type III hypocalcified: IIIA – autosomal dominant	Enamel thickness is normal with yellow-brown or orange-brown stain, friable and rapidly lost by attrition, associated with anterior open bite. Accumulation of calculus
IIIB – autosomal recessive	Same as IIIA, but more severe.
Type IV Hypomaturation-hypoplastic with taurodontism IVA - Hypomaturation-hypoplastic with taurodontism, autosomal dominant	Enamel is mottled, white-yellow-brown, pits on labial surfaces, may be thin with hypomaturated areas. Molars have taurodontic form. Other teeth may have enlarged pulp chambers.
IVB - Hypoplastic-hypomaturation with taurodontism, autosomal dominant	Enamel is thin, hypoplastic areas with hypomaturation. Teeth are taurodontic, like in type IVA

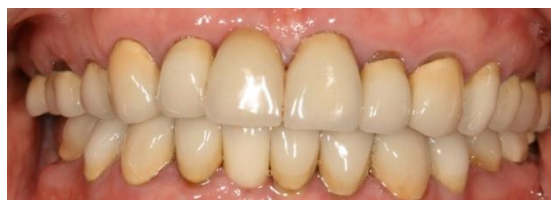**Table 2.** Classification of Amelogenesis imperfecta [15].



**Figure 4.** Amelogenesis imperfecta. Clinical Photos from Catarina Wallman.



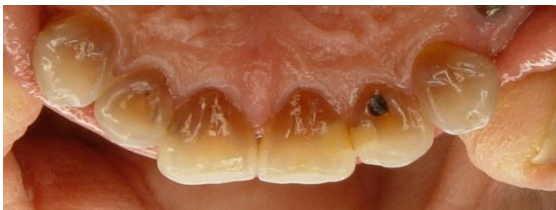**Figure 5.** A family with amelogenesis imperfecta; a son 12 years. Clinical Photos from Catarina Wallman.



**Figure 6.** A family with amelogenesis imperfecta; mother. Clinical Photos from Catarina Wallman.

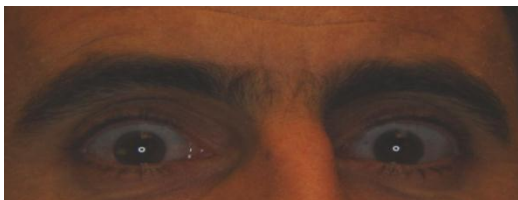

### Dentinogenesis imperfecta.

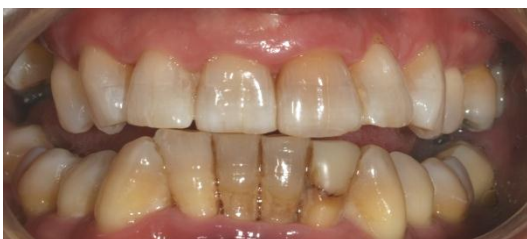

**Figure 7.** Dentinogenesis imperfecta.  
Clinical Photos from Catarina Wallman.

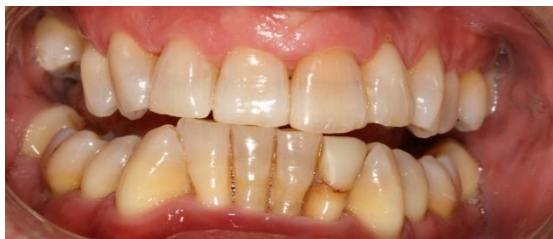### Osteogenesis imperfecta.



**Figure 8.** Osteogenesis imperfecta. Blue sclera.  
Clinical Photos from Catarina Wallman.



**Figure 9.** Osteogenesis imperfecta.  
Clinical Photos from Catarina Wallman.



**Figure 10.** Osteogenesis imperfecta.  
Clinical Photos from Catarina Wallman.

## Tetracycline staining.

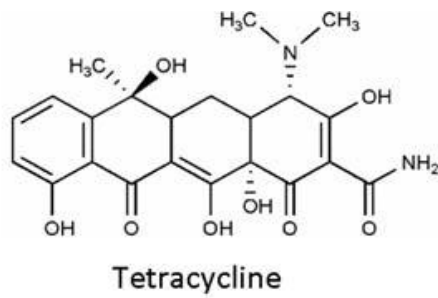


Figure 11. Tetracycline molecule [18].

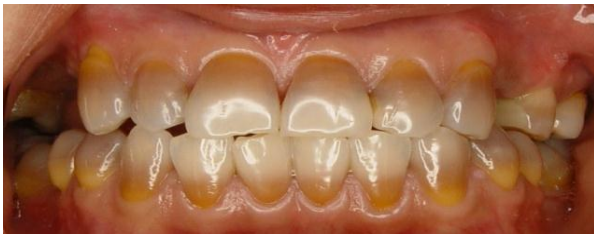

Figure 12. Tetracycline staining. Clinical Photos from Catarina Wallman.

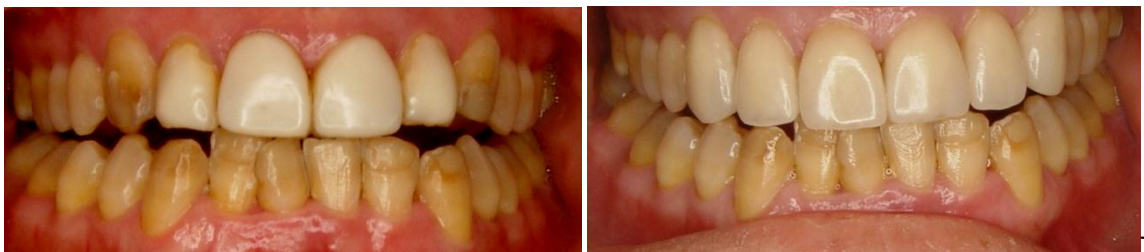

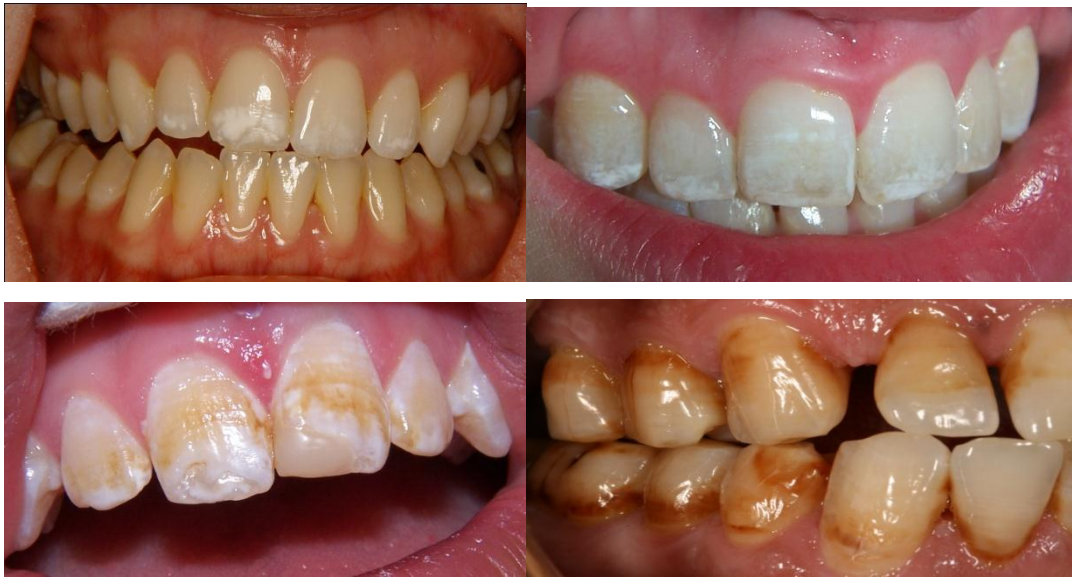Figure 13. Tetracycline-stained teeth with laminates in the upper jaw and buccal composites on front teeth in the lower jaw (right picture).  
Clinical Photos from Catarina Wallman.

## Fluorosis.

**Figure 14.** “The Thylstrup Fejerskov Index [4].

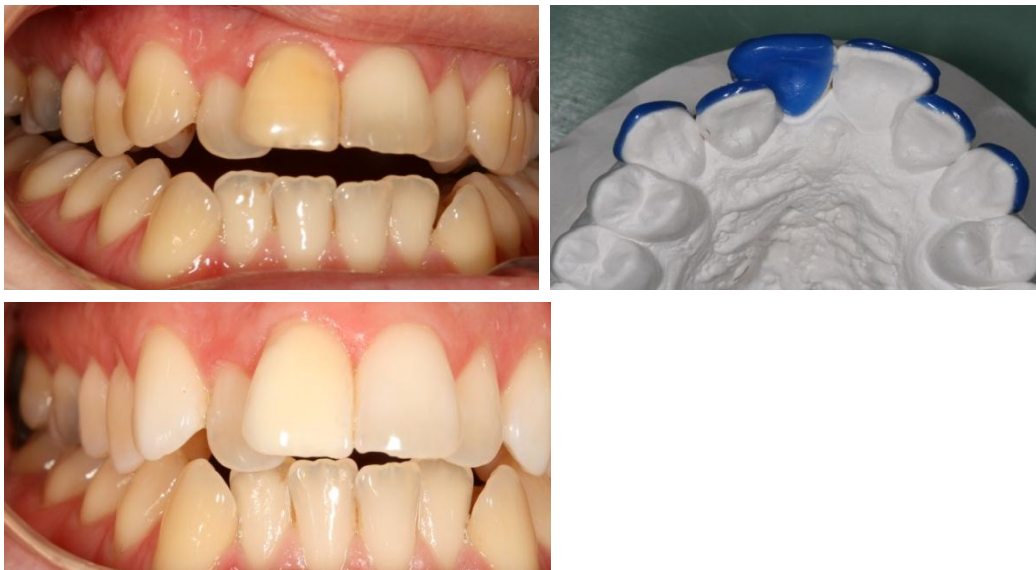### TF score

0. The normal translucency of the glossy creamy-white enamel remains after wiping and drying of the surface.
1. Thin white lines are seen running across the tooth surface. Such lines are found on all parts of the surface. The lines correspond to the position of the perikymata. In some cases, a slight 'snowcapping' of the cusps/incisal edges may also be seen.
2. The opaque white lines are more pronounced and frequently merge to form small cloudy areas scattered over the whole surface. 'Snowcapping' of the incisal edges and cusp tips is common.
3. Merging of the white lines occurs, and cloudy areas of opacity occur spread over many parts of the surface. In between the cloudy areas, white lines can also be seen.
4. Entire surface exhibits a marked opacity, or appears chalky white. Parts of the surface exposed to attrition or wear appear to be less affected.
5. The entire surface is opaque, and there are round pits (focal loss of the outermost enamel) that are less than 2 mm in diameter.
6. The small pits may frequently be seen merging in the opaque enamel to form bands that are less than 2 mm in vertical height. In this cases are also included surfaces where cuspal and facial enamel has chipped off, and the vertical dimension of the resulting damage is less than 2 mm.
7. There is a loss of the outermost enamel in irregular areas, and less than half the surface is so involved. The remaining intact enamel is opaque.
8. The loss of the outermost enamel involves more than half the enamel. The remaining intact enamel is opaque.
9. The loss of the major part of the outer enamel result in a change of the anatomical shape of the surface/tooth. A cervical rim of opaque enamel is often noted” [4].



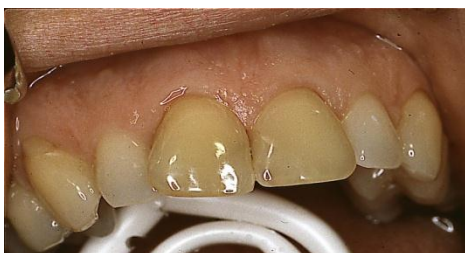**Figure 15.** Fluorosis. Clinical Photos from Catarina Wallman.

**Pulpal haemorrhagic products.**



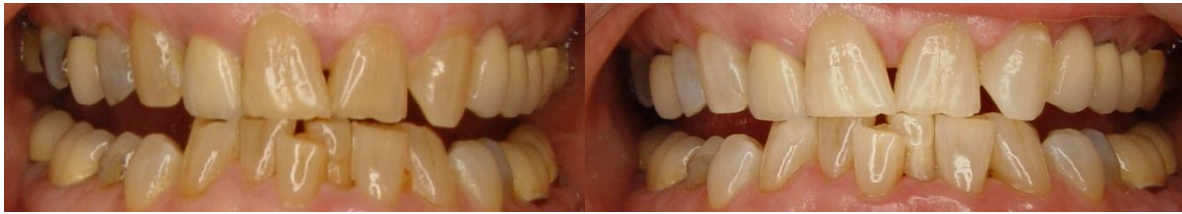**Figure 16.** Obliterated tooth 11 after trauma. Clinical Photos from Catarina Wallman.

**Trauma.**



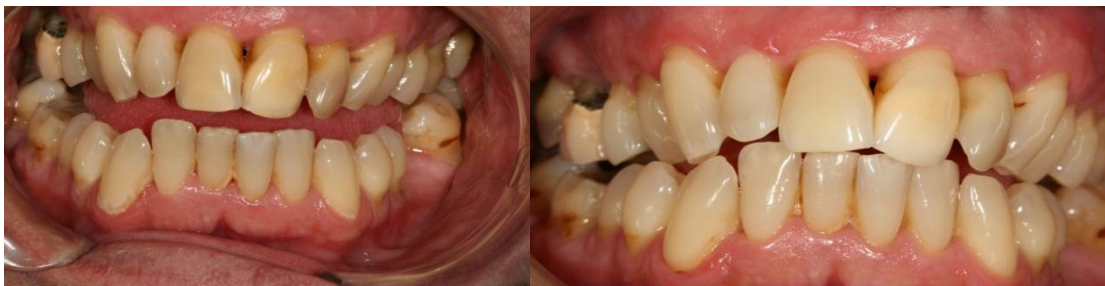**Figure 17** Trauma. Clinical Photos from Catarina Wallman.

**Ageing.**



**Figure 18.** Nightguard vital bleaching with 10% and 15% carbamide peroxid. An individual program over 2 weeks. Clinical Photos from Catarina Wallman.

**Tooth wear and gingival recession.**



**Figure 19.** Gingival recession. Bleaching of the root surfaces. Clinical Photos from Catarina Wallman.

**Table 3.** Classification of tooth discolorations, difference staining and treatment options.

Three main types of discolorations.			Enamel	Dentin	Deciduous dentition	Permanent dentition	Shade of staining of teeth	Treatment	Bleaching Y /N
1. Intrinsic discolorations.	A.Genetic defects	Alkaptonuria	x	x		x	bluish	Bleaching (?)	Y/N

		Congenital erythropoietic	x	x	x	x	Primary dentition: deep red-brown or yellow-brown. Permanent dentition: less intense discoloration. [11]	Crowns, facings and/or laminated veneers. [11]	N
		Congenital hyperbilirubinaemia	X(5)				bright yellow/green, yellow/green, olive green, bluish green, green, bright green, little yellow, grayish green, yellowish brown/deep green, dark gray/green, light brown [12]	Bleaching or crowns. [13]	Y
		Amelogenesis imperfecta	x		x	x	Yellow, yellow-brown	Bleaching, Restorative treatment.	Y
		Dentinogenesis imperfecta, Type I					Variety of colors from yellow to blue-gray.	Bleaching, Restorative treatment.	Y
		Type II	The enamel may be thinner than normal	x	x	x	In abraded teeth: dark brown or even black [16]		
		Type III		x	x	x			
				x	x	x			

		[16]						
B. Drug induced	Tetracycline staining	x	x	x	x	Yellow, grey, brown, with/or without banding.	Bleaching, Restorative treatment.	Y-mild to moderate [33]
	fluorosis	x		x	x	White opaque striations.	Bleaching Microabrasion Restorative treatment.	Y-mild. Y-moderat (in combination with microabrasion).
	ciprofloxacin	?	?	x	x	Greenish	?	?
C. Acquired	Pulpal haemorrhagic products.						Bleaching	Y
	Root resorption					Pink	Bleaching	Y
	Ageing	x	x		x		Bleaching	Y
3. Internalized discolorations.	A. Developmental defects	Enamel hypoplasia	x			Yellow, brown.		
	B. Acquired defects	Tooth wear and gingival recession	x	x		x		Y

Color and colour are used interchangeably in the text, this we are aware of. Color is used mainly in the text, but in cases where there is a direct quote taken from another text; we sometimes use the word colour.



## References.

1. Watts, A. and M. Addy, *Tooth discolouration and staining: a review of the literature*. Br Dent J, 2001. **190**(6): p. 309-16.
2. Sanchez, A.R., R.S. Rogers, 3rd, and P.J. Sheridan, *Tetracycline and other tetracycline-derivative staining of the teeth and oral cavity*. Int J Dermatol, 2004. **43**(10): p. 709-15.
3. Tredwin, C.J., C. Scully, and J.V. Bagan-Sebastian, *Drug-induced disorders of teeth*. J Dent Res, 2005. **84**(7): p. 596-602.
4. Fejerskov, O. and E.A.M. Kidd, *Dental caries : the disease and its clinical management*. 2nd ed. 2008, Oxford ; Ames, Iowa: Blackwell Munksgaard. xxiii, 616 p.
5. Bergenholtz, G., P. Hørsted-Bindslev, and C. Reit, *Textbook of endodontology*. 2010, Oxford: Wiley-Blackwell. xiii, 382 p.
6. Plotino, G., et al., *Nonvital tooth bleaching: a review of the literature and clinical procedures*. J Endod, 2008. **34**(4): p. 394-407.
7. Bailleul-Forestier, I., et al., *The genetic basis of inherited anomalies of the teeth. Part 2: syndromes with significant dental involvement*. Eur J Med Genet, 2008. **51**(5): p. 383-408.
8. Suwannarat, P., et al., *Minocycline-induced hyperpigmentation masquerading as alkaptonuria in individuals with joint pain*. Arthritis Rheum, 2004. **50**(11): p. 3698-701.
9. Siekert, R.G. and J.A. Gibilisco, *Discoloration of the teeth in alkaptonuria (ochronosis) and parkinsonism*. Oral Surg Oral Med Oral Pathol, 1970. **29**(2): p. 197-9.
10. Scully, C., *Medical problems in dentistry*. 6th ed. ed. 2010, Edinburgh: Churchill Livingstone. ix, 746 p.
11. Kooijman, M.M. and H.S. Brand, *Oral aspects of porphyria*. Int Dent J, 2005. **55**(2): p. 61-6.
12. Guimaraes, L.P. and T.A. Silva, *Green teeth associated with cholestasis caused by sepsis: a case report and review of the literature*. Oral Surg Oral Med Oral Pathol Oral Radiol Endod, 2003. **95**(4): p. 446-51.
13. Amaral, T.H., et al., *Tooth pigmentation caused by bilirubin: a case report and histological evaluation*. Spec Care Dentist, 2008. **28**(6): p. 254-7.
14. Crawford, P.J., M. Aldred, and A. Bloch-Zupan, *Amelogenesis imperfecta*. Orphanet J Rare Dis, 2007. **2**: p. 17.
15. Ng, F.K. and L.B. Messer, *Dental management of amelogenesis imperfecta patients: a primer on genotype-phenotype correlations*. Pediatr Dent, 2009. **31**(1): p. 20-30.
16. White, S.C. and M.J. Pharoah, *Oral radiology Principles and interpretation*. 2009.
17. Saeves, R., et al., *Oral findings in adults with osteogenesis imperfecta*. Spec Care Dentist, 2009. **29**(2): p. 102-8.
18. Thaker, M., P. Spanogiannopoulos, and G.D. Wright, *The tetracycline resistome*. Cell Mol Life Sci, 2010. **67**(3): p. 419-31.
19. Yagiela, J.A., *Pharmacology and therapeutics for dentistry*. 6th ed. 2011, St. Louis: Mosby Elsevier. XII, 942 s.
20. Wallman, I.S. and H.B. Hilton, *Teeth pigmented by tetracycline*. Lancet, 1962. **1**(7234): p. 827-9.
21. Eisenberg, E., *Anomalies of the teeth with stains and discolorations*. J Prev Dent, 1975. **2**(1): p. 7-14, 16-20.
22. Philip RH Newsome, L.H.G., *Management of tetracycline discoloured teeth*. Aesthetic Dentistry Today, 2008. **2**: p. 15-18.
23. Lumbiganon, P., K. Pengsaa, and T. Sookpranee, *Ciprofloxacin in neonates and its possible adverse effect on the teeth*. Pediatr Infect Dis J, 1991. **10**(8): p. 619-20.
24. Bronckers, A.L., D.M. Lyaruu, and P.K. DenBesten, *The impact of fluoride on ameloblasts and the mechanisms of enamel fluorosis*. J Dent Res, 2009. **88**(10): p. 877-93.



25. Fuss, Z., I. Tsesis, and S. Lin, *Root resorption--diagnosis, classification and treatment choices based on stimulation factors*. Dent Traumatol, 2003. **19**(4): p. 175-82.
26. *Treatment of the avulsed permanent tooth. Recommended Guidelines of the American Association of Endodontists*. Dent Clin North Am, 1995. **39**(1): p. 221-5.
27. Nikiforuk, G. and D. Fraser, *The etiology of enamel hypoplasia: a unifying concept*. J Pediatr, 1981. **98**(6): p. 888-93.
28. Faunce, F., *Management of discolored teeth*. Dent Clin North Am, 1983. **27**(4): p. 657-70.
29. Koch, G. and S. Poulsen, *Pediatric dentistry : a clinical approach*. 2nd ed. 2009, Chichester: Wiley-Blackwell. XVI, 360 s.
30. William, V., L.B. Messer, and M.F. Burrow, *Molar incisor hypomineralization: review and recommendations for clinical management*. Pediatr Dent, 2006. **28**(3): p. 224-32.
31. Clerehugh, V., A. Tugnait, and R.J. Genco, *Periodontology at a glance. At a Glance*. 2009, Oxford: Wiley-Blackwell. IX, 93 s.
32. Kihn, P.W., *Vital tooth whitening*. Dent Clin North Am, 2007. **51**(2): p. 319-31, viii.
33. Greenwall, L. and G.A. Freedman, *Bleaching techniques in restorative dentistry : an illustrated guide*. 2001, London: Martin Dunitz. 269 s.
34. Joiner, A., *The bleaching of teeth: a review of the literature*. J Dent, 2006. **34**(7): p. 412-9.
35. Haywood, V.B., *Tooth whitening : indications and outcomes of nightguard vital bleaching*. 2007, Chicago: Quintessence. VIII, 144 s.
36. Croll, T.P. and I.S. Sasa, *Carbamide peroxide bleaching of teeth with dentinogenesis imperfecta discoloration: report of a case*. Quintessence Int, 1995. **26**(10): p. 683-6.
37. Leonard, R.H., Jr., et al., *Nightguard vital bleaching of tetracycline-stained teeth: 90 months post treatment*. J Esthet Restor Dent, 2003. **15**(3): p. 142-52; discussion 153.
38. Goldstein, C.E., et al., *Bleaching vital teeth: state of the art*. Quintessence Int, 1989. **20**(10): p. 729-37.
39. Steinar Risnes, A.J., *Tannmorfologi*. 1992: Odontologisk institutt for anatomi, Universitetet i Oslo.