



# Pig model vs sheep model in undergraduate periodontal surgical training.

---

Master thesis in odontology

by

Patryk Daniel Larsen, Eyvind Tronsen, Kim Reisæter Bøen

Supervisor:

Hans-Peter Müller, DDS, Dr. med. dent. habil.

**UNIVERSITY OF TROMSØ**  
**Faculty of Health Sciences**  
Institute of Clinical Dentistry

June 2013

## Content

Abstract.....	3
Acknowledgements.....	4
1 Introduction.....	5
2 Anatomical Characteristics.....	7
2.1 The pig ( <i>Sus domesticus</i> ).....	7
2.1.2 Macroanatomy of the oral cavity.....	7
2.1.3 Facial bones.....	9
2.1.4 Pig Dentition.....	11
2.1.5 Tooth form.....	12
2.1.6 Pathology.....	13
2.2 The Sheep ( <i>Ovis aries</i> ).....	14
2.2.1 Macroanatomy of the oral cavity.....	14
2.2.2 Sheep Dentition.....	17
2.2.3 Dental pad.....	19
2.2.4 Pathology.....	20
3 Material and Methods.....	21
3.1 Specimens.....	21
3.2 Periodontal measurements.....	21
3.3 Surgical procedures.....	22
4 Results.....	26
4.1 Periodontal measurements.....	26
4.2 Surgery.....	30
4.2.1 Gingivectomy.....	30
4.2.2 Modified access flap.....	30
4.2.3 Coronally advanced flap.....	30
4.2.4 Apically repositioned flap.....	31
4.2.5 Papilla preservation flap.....	31
4.2.6 GTR with membranes.....	32
4.2.7 Distal wedge procedure.....	32
5 Discussion.....	34
5.1 Surgical procedures.....	36
5.2 Future aspects.....	37
6 Conclusion.....	38
7 Pictures.....	39
8 References.....	54

---

## Abstract

**Objective:** The objective of this study was to further develop the sheep model for periodontal surgical training to undergraduate students, and compare it to the more commonly used pig model.

**Method:** Periodontal measurements as pocket depth and gingival width were measured on a total number of 10 sheep and 9 pigs, and a pre-established list of surgical procedures were performed on both types of specimen in different areas of the dentition; gingivectomy, modified access flap with simple sutures, coronally advanced flap with sling suture, apically repositioned flap with periosteal suture, papilla preservation flap, GTR with membranes and distal wedge procedure. Quality, suitability for the respective surgeries, and similarity to human conditions were addressed.

**Result:** Mean probing depths in sheep mandible were 2.59 mm and 2.26 in the pig mandible, but statistical analysis showed no significant difference except when only the molar measurements were compared. Most surgical procedures could be performed in both specimens, apart from the papilla preservation flap which was difficult to perform in both specimen, and classified as not suitable in the pig. The anterior area in the pig was generally not suitable for any exercise of periodontal surgery, due to morphology inconsistent with human conditions. Instructive standardized picture sequences were created to facilitate training among undergraduates, and a practical session was held for 8th semester students to practically implement the sheep model at a teaching institution.

**Conclusion:** The sheep model is a valid option as a teaching model for undergraduate students, compared to the widely used pig model.

## **Acknowledgements**

We are truly grateful for all the help and instructions from our supervisor Prof. Dr. Hans-Peter Müller, whose help was of major importance to this project. We would like to thank Head of the Anatomical Department, engineer Knut Ove Tanem, whose help has been vital for us during the practical accomplishments. Special gratitude goes to Robert and Bjørnar at slaughterhouse Mydland, Tromsø. At last we would like to thank our external clinical supervisors Martin Kampe, Bjørg Heggen and Marit Teigen, who granted us leave to carry out the practical course at the university.

## 1. Introduction

Periodontology is a vital part of the undergraduate dental students' curriculum. The periodontal status influences the total oral health situation, and thus it is of importance to many people's life quality (McGrath & Bedi 2002). Treatment of advanced cases of periodontal disease often includes surgical therapy (Becker et al. 2001), although the line and efficiency between surgical and non-surgical treatment is debated (Badersten et al. 1984, Lindhe et al. 1984). The general practitioner should know some of the basic periodontal surgeries for thorough subgingival cleaning (Caffesse et al. 1986, Matia et al. 1986). For the implementation of periodontal surgery to the general practitioner's treatment list, it is important that the operator feels confident in various surgical procedures. To achieve this confidence it is important that the undergraduate students have thorough training at the teaching institutions. Several modules for teaching undergraduate students oral surgical methods have been described, including the use of animal specimens. The use of pig mandibles has been used for many decades for teaching general oral surgical procedures (Stacey 1967), and is still widely used today also for specific periodontal surgeries. But the access of pig mandibles may be difficult due to seasonal, geographical and for instance, for the Islamic world, religious variations. In particular for the latter case, there has been made a teaching model using sheep mandibles (Al-Qareer et al. 2004). In addition, new plastic models with silicon mucosa have been suggested, which simulate human tissue and involves hard tissue lesions (Rühling et al. 2002, König et al. 2002), but they have limitations, especially their lack of imitation of human masticatory and lining mucosa.

For a proper teaching model, there are several factors which must be considered besides the immediate availability, which includes the similarity to human tissue conditions, the presence of infrabony lesions, furcation involvement, fibrous tissue, excess gingiva etc. which could be used to simulate real conditions needing surgical treatment. All models have their specific limitations and advantages as regards the specific surgical procedures undertaken. Here we are describing and comparing different surgical procedures in Scandinavian lamb mandibles and Scandinavian pig mandibles, including gingivectomy (Goldman 1946), modified access flaps (Kirkland 1931), distal wedge procedures (Robinson 1966), coronally advanced flaps (Bernimoulin et al. 1975), apically repositioned

flaps (Nabers 1954, Friedman 1962), papilla preservation flaps (Takei et al. 1985, Cortellini et al. 1995), guided tissue regeneration (GTR) with membranes (Gottlow et al. 1986), and different suturing techniques including simple interrupted sutures, continuous sutures and periosteal sutures. We are addressing the prevalence of periodontal lesions, and the suitability of those previously stated procedures in different areas of the dentition. We are then describing a teaching model based on those findings, which allows for the most human-like and therefore most suitable specimens for teaching purposes. The aim of this study is to (1) further develop the sheep model as regards a variety of periodontal surgical methods and (2) to compare the model with the more common pig model.

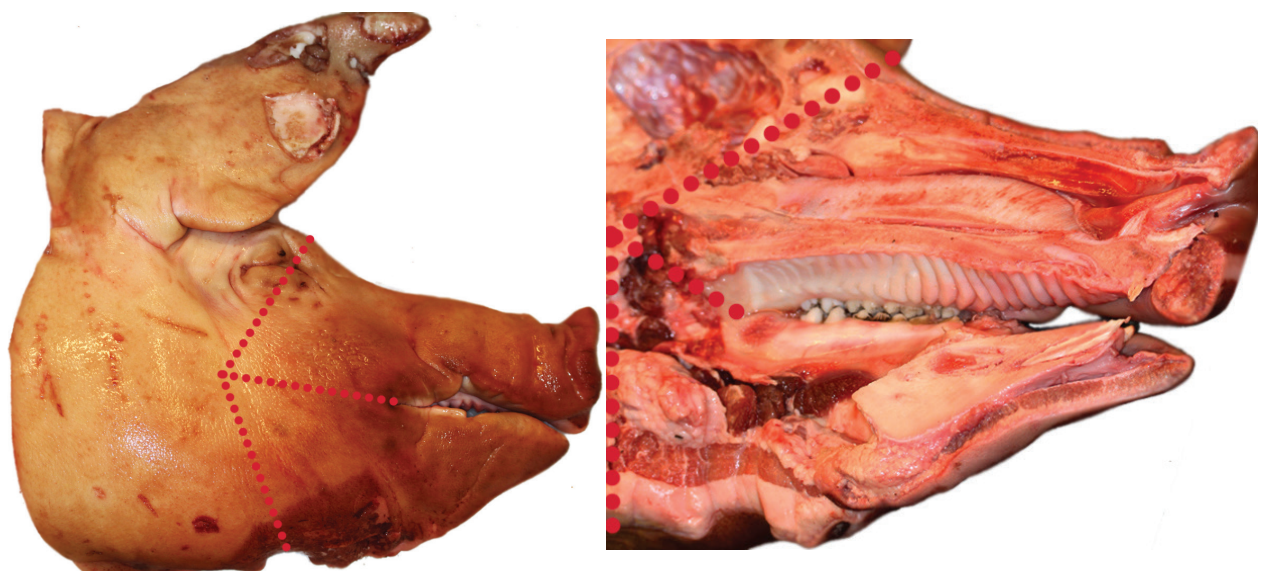
## 2. Anatomical characteristics

### 2.1 The pig (*Sus domesticus*)

*Sus domesticus* (order Artiodactyla, suborder Suiformes, family Suidae), or as we know it; the domesticated pig, is considered a subspecies to the wild boar, *sus scrofa* (Gentry et al. 2004). At around 1 billion individuals alive at any time, these omnivorous animals are one of the most numerous large mammals on the planet (Department of Agriculture 2012). Belonging to the suborder Suiformes, pigs do not have a ruminant digestive system but are so-called monogastrics, just like humans and dogs (Oliver 1993). This is essential when compared to the ruminant sheep, because it affects the morphology of the mouth and the anatomy of the teeth (Hillson 2005).

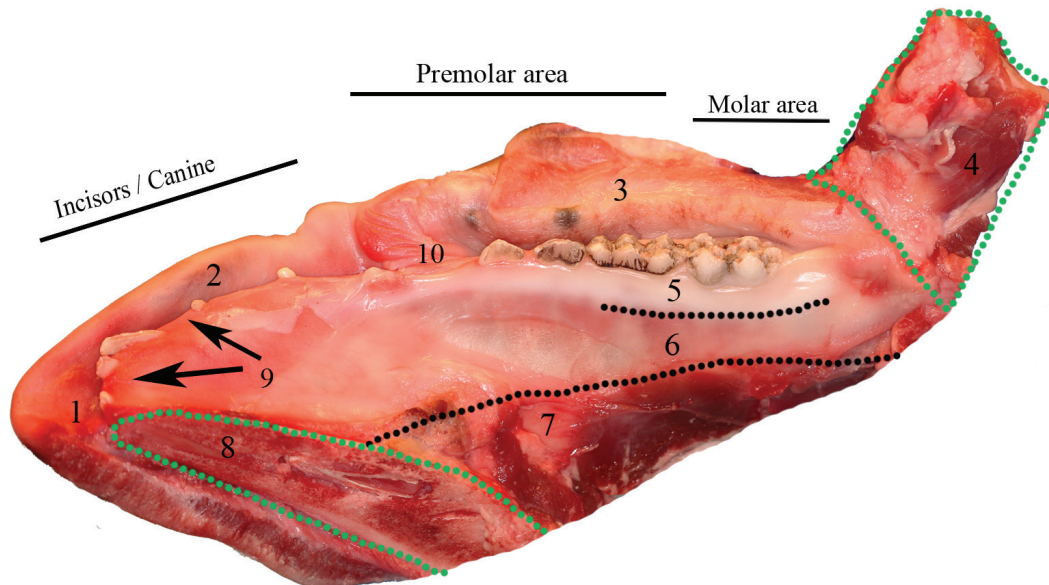
#### 2.1.2 Macro anatomy of the oral cavity

The long, pointy head of the domesticated pig often comes from the slaughterhouse split in the median sagittal plane, but without any distinct precision and therefore often causing missing central and/or lateral incisors. The tongue is also often missing, as it is used as food.



**Figure 2.1:** Lateral and medial view of the pigs head as it comes delivered from the slaughterhouse. While the heads were frozen, cuts were made at red dotted lines with a bandsaw located at the anatomical ward, to separate the mandible from the maxilla.

The pig has numerous strong cheek muscles which make it almost impossible to move the mandible in the vertical plane, also after the defrosting period. To achieve decent access to buccal gingiva, the mandible should be separated from the rest of the skull, and all residue tissue should be removed to get a good overview of the operative field. The most distinct characteristics of the adolescent pig's mandible are covered in figure 2.2.

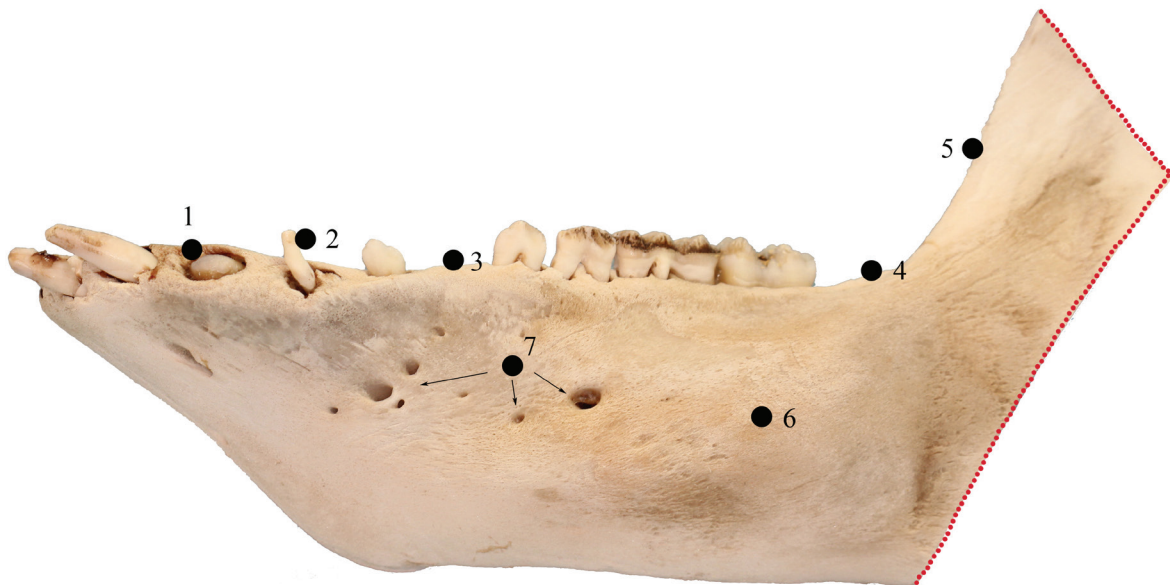

**Figure 2.2:** A typical sample of a young pig mandible. The identification of structures: 1 . Mandibular vestibule, the area between the lips and the teeth. 2. Lip. 3. Right cheek. 4. Ramus of mandibular bone, cut in the posterior aspect, condyle missing. 5. Attached gingiva. 6. Mucosa, separated by the mucogingival border to gingiva. 7. Anterior aspect of mandibular bone, including the embodied crown of the permanent 1st molar. 8. Cut surface of missing lingua. 9. Broad anterior interproximal spaces separating the deciduous incisors. 10. Buccal frenulum.

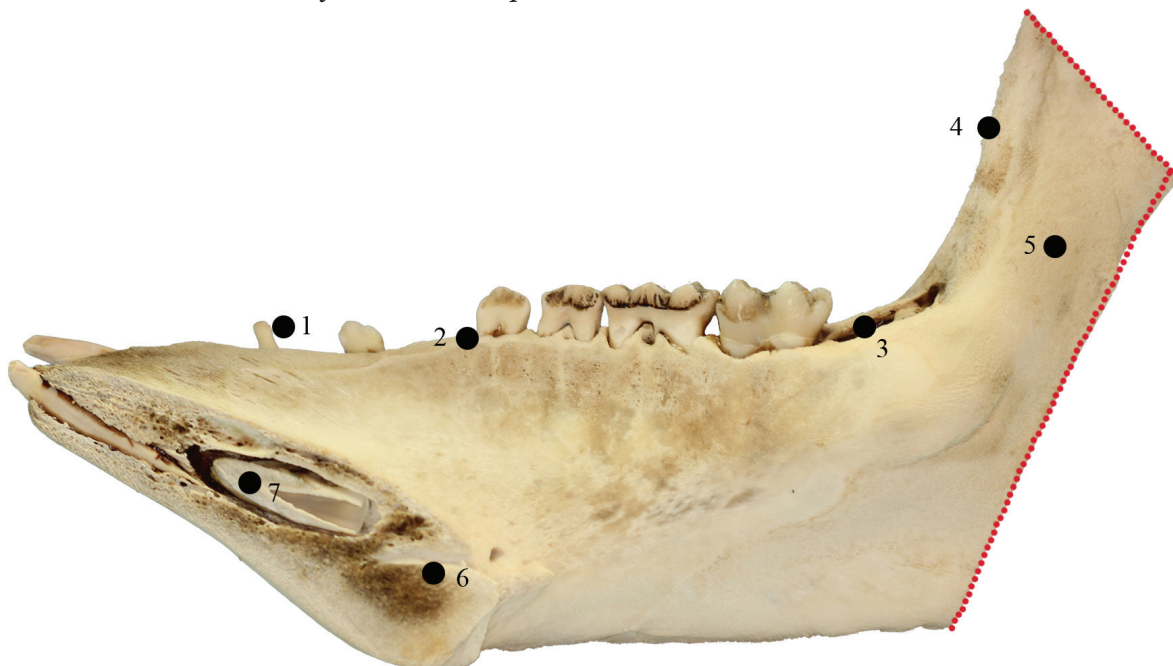

### 2.1.3 Facial bones

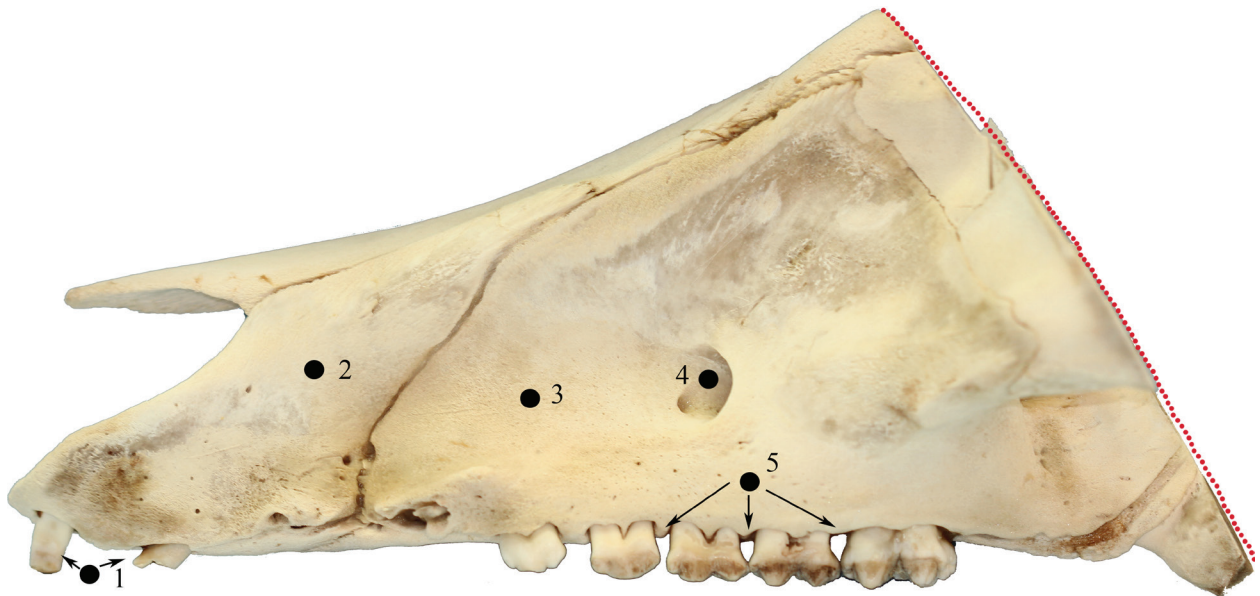
While man has 14 facial bones, the pig has 19. The facial bones of the pig is elongated, particularly the maxilla and the nasal bones. The premaxilla bones, between the maxilla and the nasal bones, are not found in man (Rafferty et. al 2003). The most distinct characteristics of the pigs facial bones are covered in figure 2.3, 2.4 and 2.5 (Schaller 1992).



**Figure 2.3:** Buccal view of a macerated pig's mandible. The identification of structures: 1. Erupting permanent incisor. 2. Deciduous canine. 3. Margo alveolaris. 4. Eruption-site for 2nd permanent molar. 5. Anterior border of ramus. 6. Corpus mandibulae 7. Foramina mentalia lateralia.



**Figure 2.4:** A young pig's macerated mandible cut in the medial sagittal plane, lingual view. The red dotted line indicates the cut-surface from the slaughterhouse. The identification of structures: 1. Deciduous canine. 2. Anterior corner of 2nd deciduous premolar. 3. Eruption site of 2nd permanent molar. 4. Anterior border of ramus. 5. Ramus. 6. Foramen mentale mediale. 7. Permanent 1st incisor.



**Figure 2.5:** Buccal view of a part of a macerated pigs maxilla. Red dotted line indicates cut-line from slaughterhouse. The identification of structures: 1. Fractured deciduous incisors. 2. Premaxilla bones. 3. Maxilla, principal bone of the upper jaw. 4. Foramen maxillare. 5. Interproximal spaces between posterior teeth.

### 2.1.4 Pig dentition

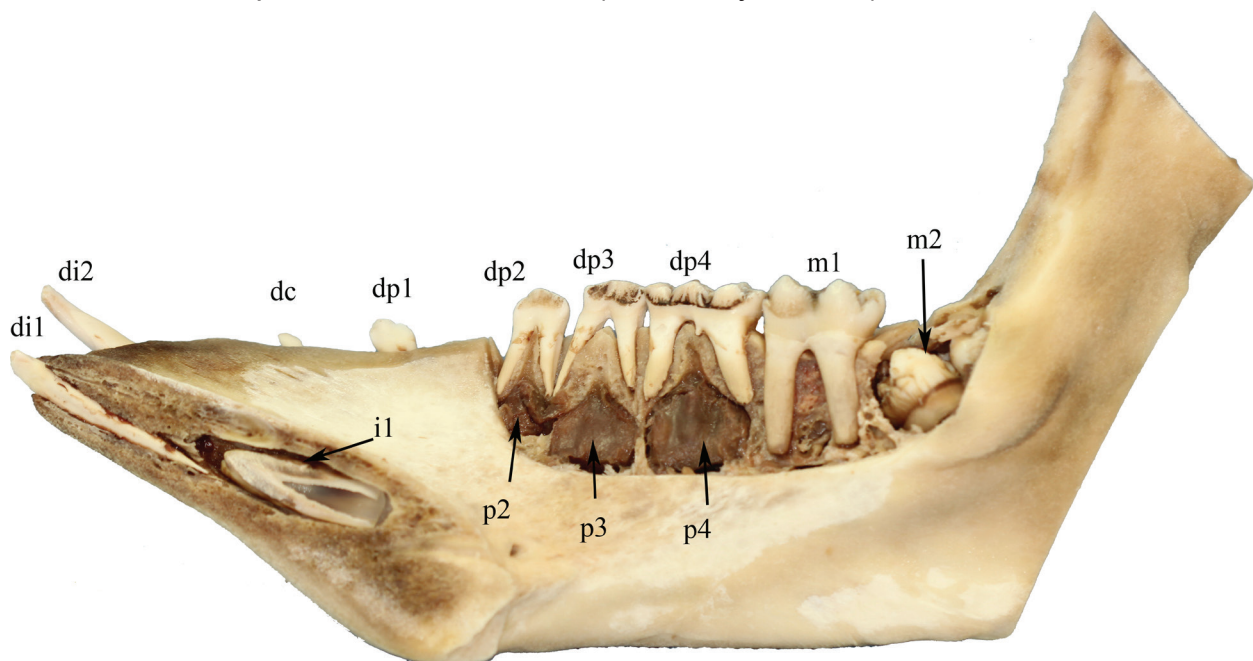
The deciduous dental formula of the pig is  $di \frac{3}{3}, dc \frac{1}{1}, dp \frac{3}{3}$  while the permanent dental formula is  $i \frac{2-3}{3}, c \frac{1}{1}, p \frac{3-4}{2-4}, m \frac{3}{3}$  (Hillson 2005). The tooth in the position of the first premolar is often missing in domestic pigs (Miles & Grigson 1990).

Pig slaughter happens at different ages, but most pigs are slaughtered at 4 months to 1 year old, including the examples we have examined and performed surgery on. This means that most examples show deciduous dentition in addition to the first permanent molar. This is according to table of eruption time of permanent teeth of pigs (Table 2.1).

The deciduous teeth erupt and come into wear during the first weeks and months after birth (Matschke 1967), while the permanent first molar erupts immediately behind the deciduous fourth premolar at 4-8 months (Bull & Payne 1982).

	Overall range of domestic pig (in months after birth).
1st incisor	11-17
2nd incisor	14-20
3rd incisor	6-12
Canine	6-12
1st premolar	3.5-8
2nd premolar	12-16
3rd premolar	12-16
4th premolar	12-16
1st molar	4-8
2nd molar	7-13
3rd molar	16-22

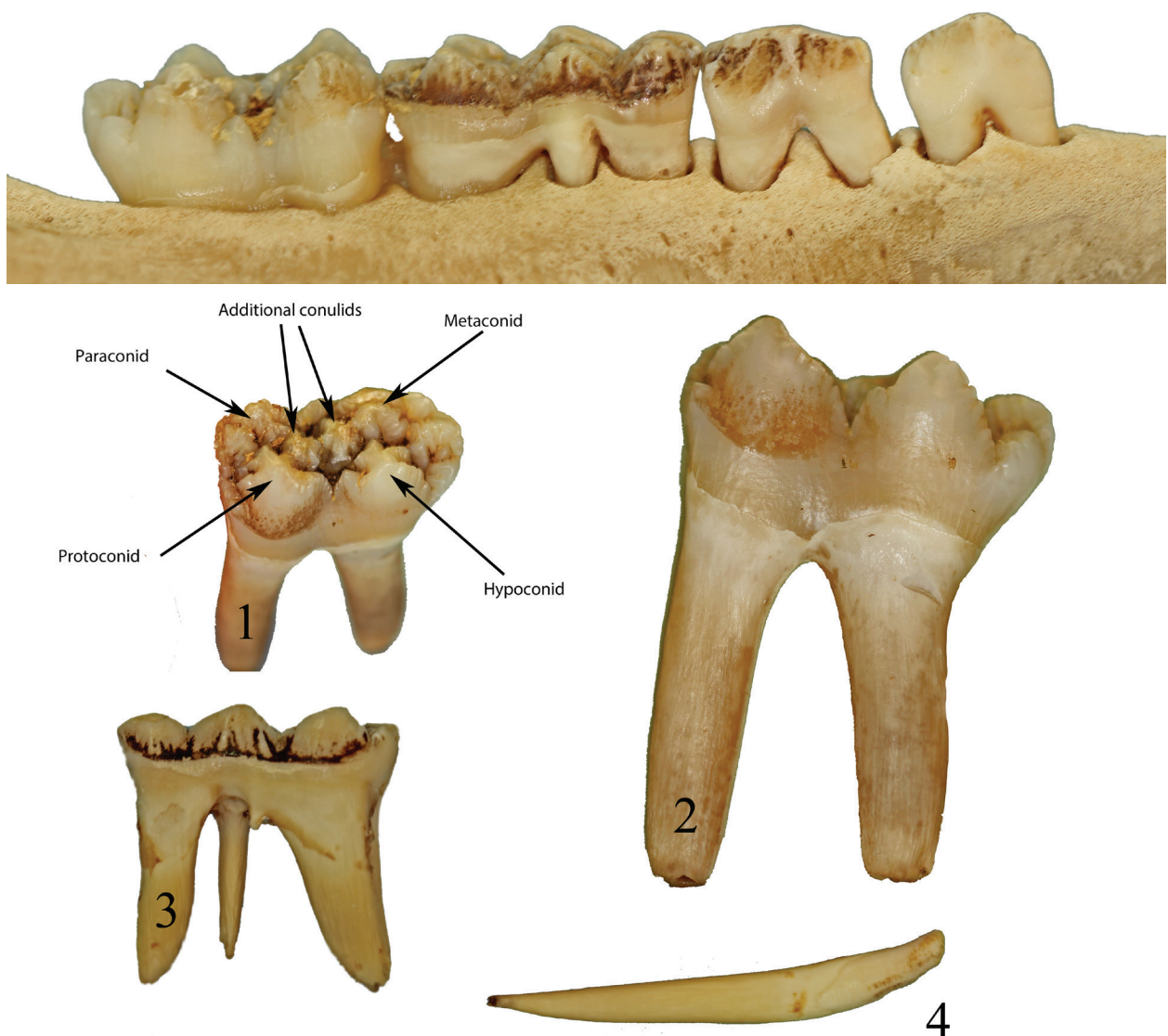
**Table 2.1:** Gingival emergence timing of permanent teeth in domestic pigs (Bull & Payne 1982).



**Figure 2.6:** Identification of the mandibular teeth in pig: di 1-2 = deciduous incisors. di3 fell out during maceration. dc = deciduous canine, dp1-4 = deciduous premolar, m1-2 = permanent molar, p2-4 = permanent premolars, i1 = permanent incisor.

### 2.1.5 Tooth form

The pig's cheek teeth are both brachydont and bunodont, meaning that they are low-crowned and have conical cusps (Miles & Grigson 1990). Large cusps are in the lower jaw termed conids, while smaller cusps are termed conulids (Reig 1977). The pig is like the human omnivorous, meaning that the diet consists of both animal and plant matter. It therefore combines sharp pointy incisors with incisor-to-incisor relation, and grinding premolars and molars, perfect for a diet consisting of food of many different consistencies (Myers et al. 2013). This is opposed to the ruminant sheep with teeth formed ideally for grinding their partly digested food over and over again, and no incisors in the upper jaw.



**Figure 2.7:** 1. Detail picture of the crown of the 1st permanent molar, showing the different terms of the cusps. 2. Lateral view of the 1st permanent molar, clearly illustrating the cementoenamel junction. 3. Lateral view of the 4th deciduous premolar. Note the shorter and sharper roots. 4. A deciduous incisor, with rather a rather short crown compared to the root.

### **2.1.6 Pathology**

Inflammatory and degenerative diseases of the periodontal tissues are common in domestic mammals (Harvey 1985). Periodontal lesions were found in 23% of domestic pigs in a study from Queensland, Australia (Samuel & Woodall 1988). Only teeth in the buccal segment were affected, and molars more than premolars. As expected periodontal disease affecting bone increased with age (Samuel & Woodall 1988). In another study from California, Barrett (1978) found that all 137 feral pigs derived from a domesticated stock over 4 years had periodontal disease severe enough to produce abscesses.

Dental caries occurs occasionally in domestic pigs, mostly approximately and associated with food impaction (Anthony & Lewis 1961).

A study from Illinois assessed 39 wild and 30 domestic pig skulls for dental anomalies including polydonty, oligodonty, misalignment and rotation (Feldhamer & McCann 2004). 16 wild and 15 domestic pigs had dental anomalies, missing first premolar being the most common with an incidence of 50 % in the domestic pigs (Feldhamer & McCann 2004). This was a trend we also noticed with our samples. Supernumerary teeth are rare (Feldhamer & McCann 2004, Otto & Schumacher 1978).

Injuries to erupted teeth are relatively common in animals (Miles & Grigson, 1990), something we experienced with our specimens. The anterior segment of teeth is generally damaged. This is probably, among other things, due to poor handling of the head after slaughtering.

Neoplasms of the oral cavity are rarely found in domestic animals (Moulton 1978). Tumors originating in the nasal cavities have been reported (Schlegel 1915).

## **2.2 The Sheep (*Ovis aries*)**

The sheep (*Ovis aries*) is part of the antelope-goat subfamily (Antilopinae and Caprinae). These two subfamilies belong to the Bovidae family, which all have similar teeth that are difficult to distinguish from one another (Hillson 2005). The physical details and coloration of sheep vary among the over 200 distinct breeds of sheep. Female sheep also tend to be approximately three-quarters to two-thirds the size of males (Reavill 2000).

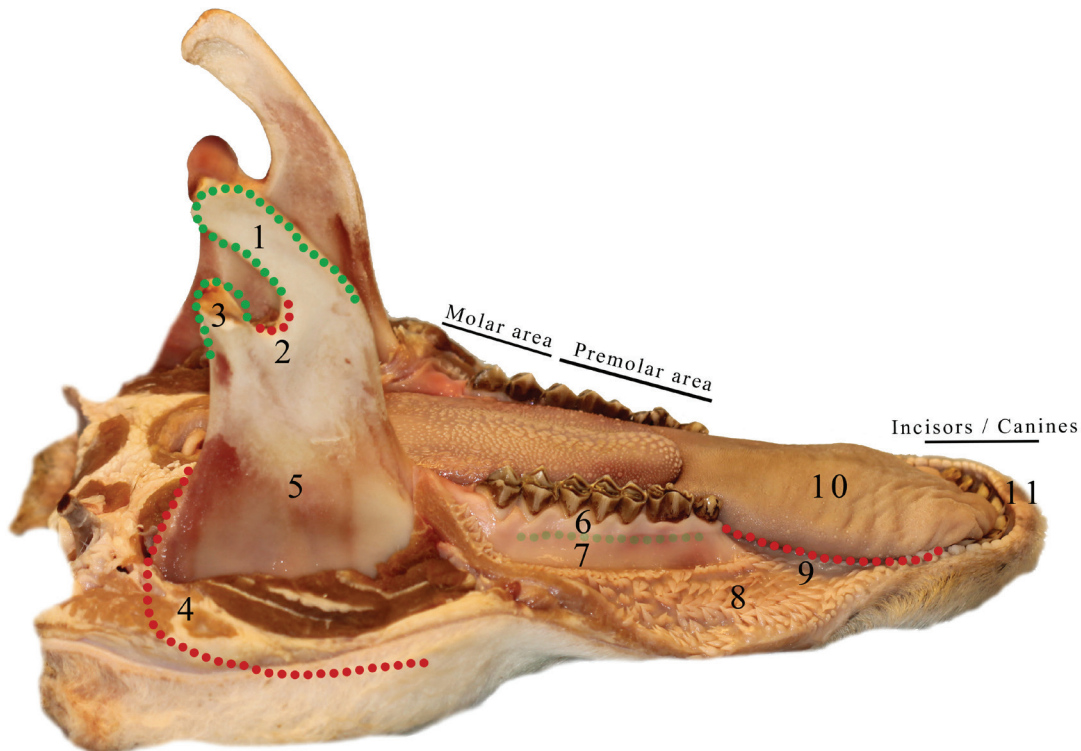
Meat production as well as the population of sheep generally increased rapidly from the 1960s to 1990 (Terrili 1986, FAOSTAT 2013). Since then the population has decreased slightly, leaving approximately 1.1 billion living individuals worldwide (FAOSTAT 2013). Sheep are easily accessible in most parts of the world, which is desirable for study purposes.

### **2.2.1 Macroanatomy of the oral cavity in sheep**

The sheep head is mostly covered by hair, with the exception of the nostrils and margins of the lips (Reavill 2000). The lips are thin and mobile, and play an active role in the grasping of food. The upper lip is divided in two by a median groove, making it possible to move each half of the lip independently to the other (Cheveau et al. 1873). Sheep have a long narrow snout, and the anterior teeth are separated from the premolars and molars by a gap with no dentition. On the inner surface of the cheeks, large numbers of long and conical papillae are found (Figure 2.8, number 8).

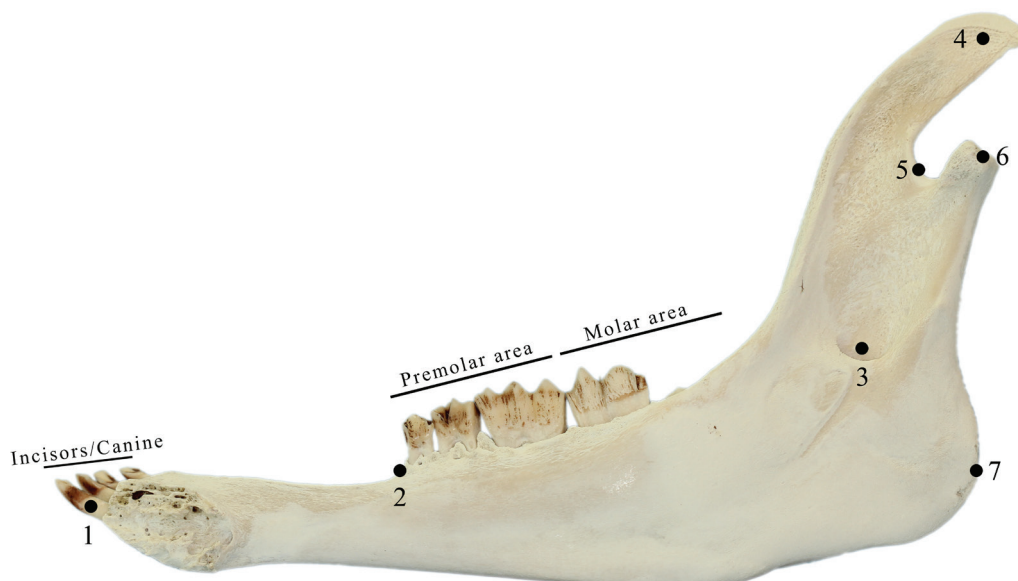
A so-called dental pad is also seen in both the upper and lower jaw, and will be discussed later (see 2.2.3. Dental pad).

Our study models consisted of only the sheep mandible, and not the maxilla. The mandible was separated from the upper jaw by the slaughterhouse. Unlike the pig models, the sheep were not split in the median sagittal plane, giving us the opportunity to study the mandible as a whole with all teeth intact. The most distinct characteristics of the sheep mandible are covered in figure 2.8.

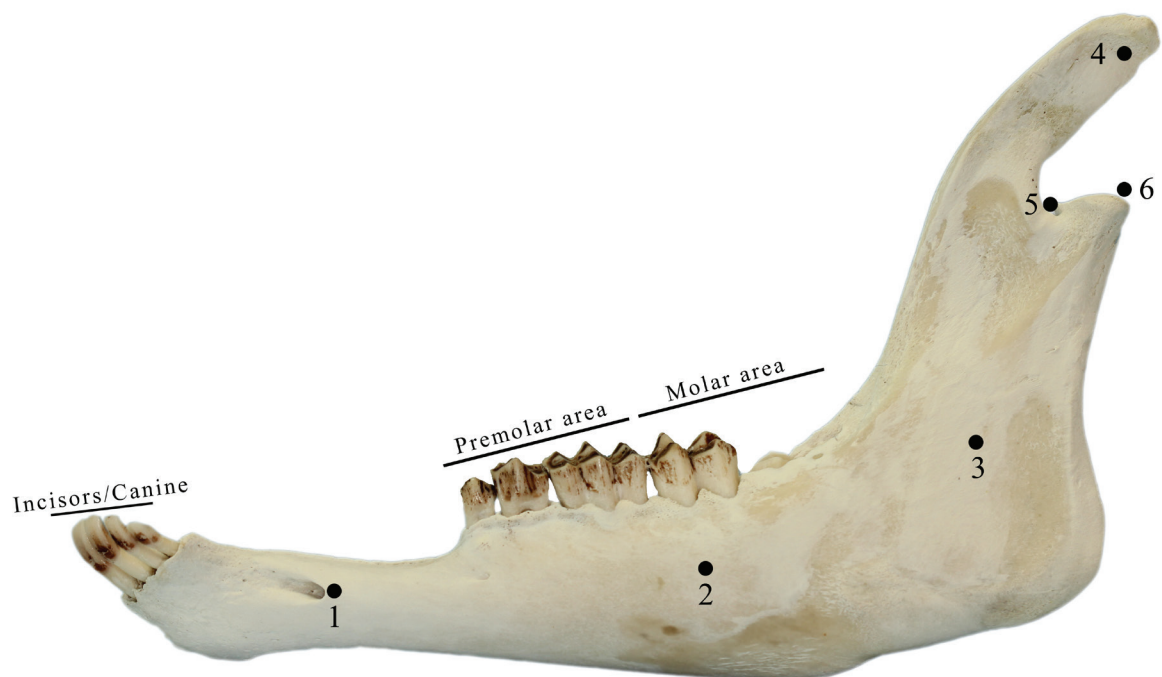


**Figure 2.8:** A typical sample of a young sheep mandible. The identification of structures: 1. Coronoid process. 2. The point of the mandibular notch. 3. Mandibular condyle. 4. The mandibular angle (red dotted curve). 5. Ramus of the mandible. 6. Attached gingiva. 7. Mucosa, separated by the mucogingival border to gingival. 8. Inner surface of cheek, with long and conical papillae. 9. Gap between the anterior and posterior teeth with no dentition. 10. Tongue. 11. Lower lip.

The most basic anatomical bone structures of the sheep mandible are covered in figure 2.9 and 2.10 below.



**Figure 2.9:** A young sheep mandible split in the median sagittal plane, lingual view. The identification of structures: 1. 1st incisor. 2. The anterior corner of dp2 (deciduous premolar). 3. Mandibular foramen. 4. Coronoid process. 5. The point of the mandibular notch. 6. Mandibular condyle. 7. The posterior mid-point of the mandibular angle.



**Figure 2.10:** A young sheep mandible split in the median sagittal plane, lateral view. 1. Mental foramen. 2. Body of the mandible. 3. Ramus of the mandible. 4. Coronoid process. 5. The point of the mandibular notch. 6. Mandibular condyle.



### 2.2.2 Sheep dentition

Sheep are diphyodont animals, developing two sets of teeth; deciduous and permanent teeth (Weinreb & Sharav 1964). Their deciduous dentition consists of 20 teeth, with the formula  $di\frac{0}{3}, dc\frac{0}{1}, dp\frac{3}{3}$ , whereas the permanent dentition consists of 32 teeth and has the formula  $i\frac{0}{3}, c\frac{0}{1}, p\frac{3}{3}, m\frac{3}{3}$  (Hillson 2005).

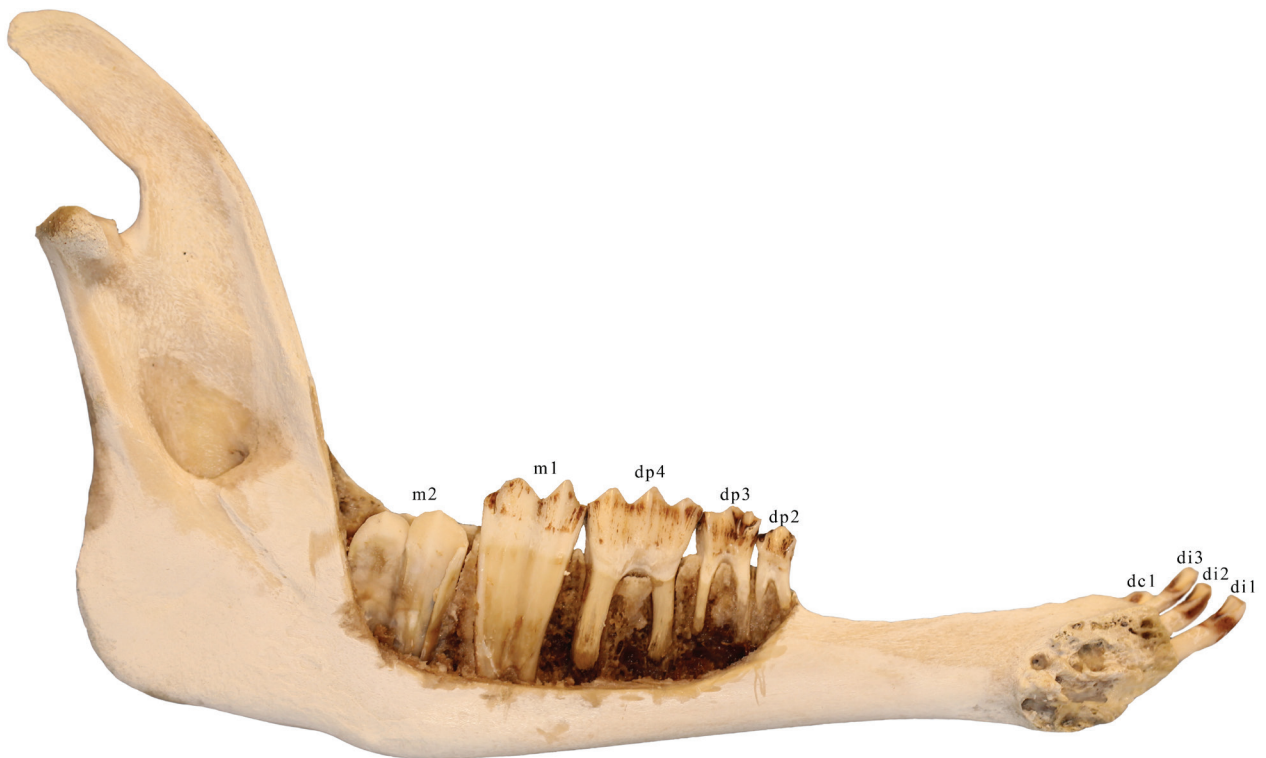
At birth, lambs' deciduous teeth are apparent in the oral cavity, only covered by a thin layer of gingival tissue, and within a few days they are fully erupted. Whereas in humans the complete set of deciduous teeth takes over 2.5 years to erupt, in the sheep it only takes 2 to 4 weeks for all deciduous teeth to be functional (Hatt 1967). The first premolar begins erupting at around 6 months and the second premolar along with the permanent central incisors at around 1 year. The permanent premolars and the third molars erupt around 2 years of age (Weinreb & Sharav 1964, NSW Agriculture 2003).

Detailed eruption timetables for the permanent dentition will be left out because of the considerable variation (Hillson 2005). NSW Agriculture (2003) also states that only a rough estimate of a sheep's age can be made by looking at its teeth, and when estimating it is important to know whether the breed is early or late maturing.

Sheep spend most of their day grazing and ruminating grass or hay and have the ability to ingest a lot of food in a short time. Due to their large and complex stomach they are able to digest highly fibrous foods, which can only be digested by a few other animals (Reavill 2000). Sheep feeding on long soft grass will normally show teeth in good condition with little amount of wear, whereas short grass in a sandy or gravelly soil will wear the teeth down more easily (NSW Agriculture 2003). Excessive wear in sheep seems to be influenced by other factors as well, i.e. quantity and type of pasture, stocking rate and probably management (Healy & Ludwig 1965). Their constant chewing will eventually wear down most of the crown length, but this is compensated for by the continuous root growth throughout life (Barnicoat 1957, Weinreb & Sharav 1964). It is also worth mentioning that, due to shallow bone sockets, all anterior teeth are mobile, and that a movement of incisors up to 2 mm is considered normal (Duckworth et al. 1962, Cutress 1972).

The sheep incisors look very similar to human teeth. The premolars and molars however present a special form and shape. The enamel of the posterior teeth has folds or embrasures of varying depths. Deep invaginations or pits on the occlusal surfaces are also typical (Weinreb & Sharav 1964).

An overview of a sheep mandibula and its dentition can be seen in figure 2.11.



**Figure 2.11:** Identification of the mandibular teeth in sheep: *di1-3 = deciduous incisors, dc1 = deciduous canine, dp2-4 = deciduous premolars, m1-2 = permanent molars.* This is the sample of a young sheep, approximately 1 year of age based on the eruption of teeth.

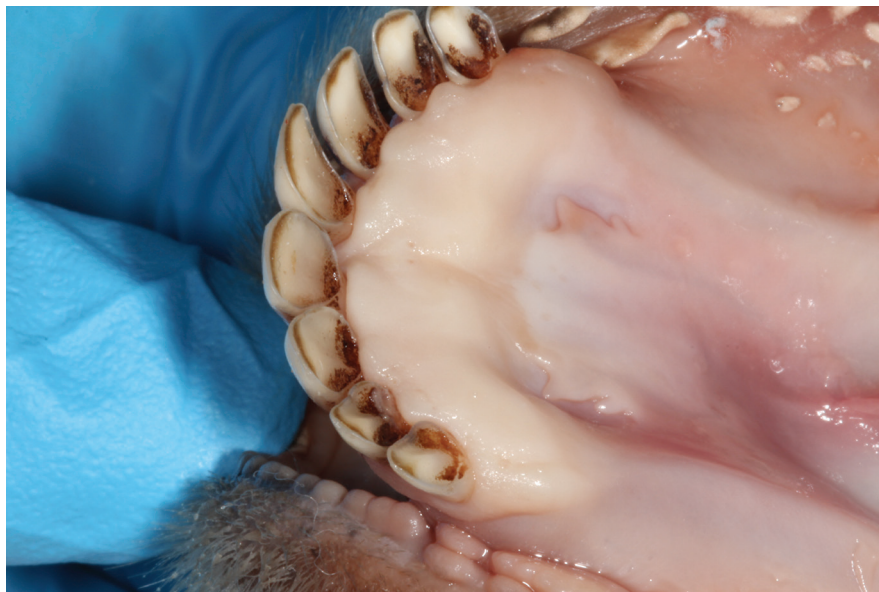The numbering of deciduous premolars in figure 2.11 begins with the deciduous premolar 2 (dp2). The reason for this is not a missing first premolar, but that the generalised eutherian deciduous dentition has the following dental formula:

$$di \frac{3}{3}, dc \frac{1}{1}, dp \frac{4}{4} .$$

Evolution has reduced the number of teeth in different classes. In the premolar class, reduction is normally from the mesial end of the tooth row, and as for the sheep that have three premolars, these may be referred to as the second, third and fourth premolars (Hillson 2005).

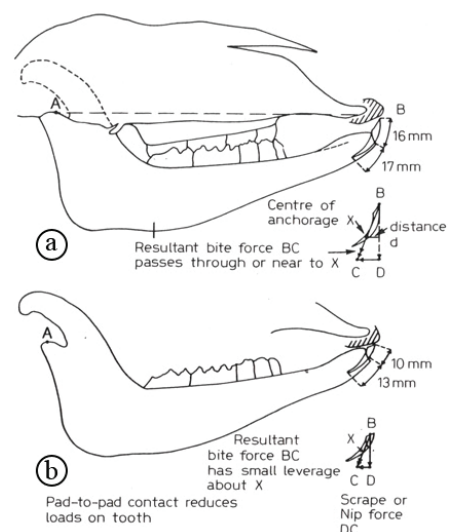
### 2.2.3 Dental pad

In the anterior part of both jaws a dense, slightly resilient, fibrous pad is found (Agfact 1984), which is known as the dental pad (figure 2.12). Sheep lack incisors and canines in the upper jaw. Instead, the dental pad is located in the place where these teeth are normally seen. In the lower jaw however, both incisors and canines are present, and the dental pad is located lingual to the lower incisors. The dental pads consist of dense, collagenous connective tissue covered by keratinizing, stratified squamous epithelium with a thick prominent stratum corneum (Weinreb & Sharav 1964, Cutress 1972).



**Figure 2.12:** The lower dental pad of sheep is located lingually to the lower incisors/canines).

When eating, sheep hold the grass between the upper dental pad and the lower incisors. This contact leads to wear of the incisor tips, and eventually pad-to-pad contact is achieved (Figure 2.13, Northey et al. 1975).



**Figure: 2.13.** Sagittal cross-section of the mouth of a young sheep with the incisor – dental pad relationship (a), and the pad-to-pad relationship as a result of wear of the incisor tips (b). From Northey et al 1975.

### **2.2.4 Pathology**

In sheep, diseases of the teeth and their supporting soft tissues are common. Conditions of importance to the oral cavity include developmental and composition abnormalities, diseases leading to premature tooth loss, excessive and/or irregular tooth wear, deformities of the mandible and problems of occlusion or bite (Ridler & West 2007).

Periodontitis leading to tooth loss can affect both the incisors and the molars. The condition in which the anterior teeth undergo premature loss or shedding is termed “broken-mouth” (Hitchin & Walker-Love 1959), and this develops early while the incisors are still erupting and their roots are still growing. Several possible etiological factors have been proposed for “broken mouth” periodontitis. Etiological factors most likely to contribute to broken mouth disease are farm environments, genetic effects and infection from a particular group of plaque-forming bacteria (Page & Schroeder 1982). According to studies by Benzie and Cresswell (1962), and Duckworth et al. (1962), it seems that some flocks of sheep lose their permanent incisors faster than others (Page & Schroeder 1982). This builds upon the idea that environments and genetics may play a role in the development of broken mouth. Mechanical stress due to the incisor-pad relationship (Northey et al. 1975) has also been considered as a possible cause, but later studies consider this a rather unlikely factor (Steele & Henderson 1977).

### **3. Material and Methods**

#### ***3.1 Specimens***

The specimens of sheep mandibles and half pig heads were obtained from a local butcher shop in Tromsø, Mydland. The sheep mandibles were dissected from the rest of the sheep's head by the butcher. The pig specimen was delivered as half a head, the cut made in the midline sagittally, and thus the authors removed unnecessary tissues by dissecting the mandible from the rest of the skull. When the specimens were obtained they were deep-frozen in the Faculty of Health Sciences' anatomical department's freezer. Before surgery was done, the specimens were put in a cold room with a temperature of 4°C for approximately 24 hours for de-freezing.

For helping determining the tooth and alveolar anatomy, the authors selected one specimen from sheep and one of the pigs to be cleaned of all soft tissues. The specimens were first cleaned roughly with scalpel blades. Thereafter they were boiled in a solution of water and detergent with 5-15% anionic tensids, <5% non-ionic tensids, phosphonates, polycarboxylates and zeolitts for approximately 6 hours. Thereafter they were dried and the buccal bone was removed with water-cooled burs, and the root anatomy was visualized together with eventual underlying tooth-buds.

The different procedures were documented with pictures taken with different cameras from the Canon EOS series, equipped with macroscopic lenses and attached ring-flash.

#### ***3.2 Periodontal measurements***

The instruments used during the periodontal probing were:

- Intraoral mirror: Hu-Friedy MIR w/handle MH1
- Periodontal probe: LM 23-52B XSi (with 2mm markings)

The probing sites were determined with different numbers of sites for individual teeth because of their different anatomy. The probing depths were rounded to the nearest millimeter. Where the teeth were missing or probing depths not available (e.g. teared gingiva), sites were excluded from the measuring. The width of the gingiva was also measured to the nearest millimeter. A total of 10 sheep specimens and 9 pig specimens were measured.

In sheep, the three incisors, canine, second and third deciduous premolars were probed at six sites per tooth. The sites were mesiobuccal, midbuccal, distobuccal, mesiolingual, midlingual and distolingual. The fourth deciduous premolar was probed at eighteen sites per tooth, measuring the pocket depths at the mesiobuccal, midbuccal, distobuccal, mesiolingual, midlingual and distolingual part of all three cusps of the tooth, thus ending up with eighteen sites for the total tooth. The first permanent molar was measured at twelve sites per tooth, the sites being mesiobuccal, midbuccal, distobuccal, mesiolingual, midlingual and distolingual of both cuspids, thus ending up with twelve sites for the total tooth.

In the pigs the four incisors, canine, first, second and third deciduous premolars were probed at six sites per tooth. The fourth deciduous premolar was probed at eighteen sites per tooth, measuring the pocket depths at the mesiobuccal, midbuccal, distobuccal, mesiolingual, midlingual and distolingual part of all three cusps of the tooth, thus ending up with eighteen sites for the total tooth. The first molars were probed at twelve sites per tooth, measuring the mesiobuccal, midbuccal, distobuccal, mesiolingual, midlingual and distolingual parts of both cuspids, thus ending up with twelve sites.

The mean values and standard deviations were calculated, for each sample, for each tooth group and for the total sample of pigs and sheep. We did a t-test to interpret the differences, and made graphs illustrating our findings.

### **3.3 Surgical procedures**

The instruments used for the surgical procedures include:

- Intraoral mirror: Hu-Friedy MIR w/handle MH1
- Periodontal probe: LM 23-52B XSi (with 2mm markings)
- Kirkland surgical knife Hu-Friedy KK 15/16
- Scalpel handle Hu-Friedy 10-130-07K
- Sugarman curette Hu-Friedy SS 9/10
- Syntette LM-Dental LM 215/16
- LaGrange scissor Hu-Friedy S14SC
- Periostal elevator Hu-Friedy P24GSP
- Adson tissue pliers Hu-Friedy TP5041
- Mathieu needle holder Hu-Friedy NH5076
- Scalpel blade Martin 12d
- Scalpel blade Swann-Morton 15
- Suture needle and thread Ethicon, Ethilon\*II, polyamide 6, 5-0, 45cm

The surgical procedures of gingivectomy, modified flap operation, coronally advanced flap, apically repositioned flaps, papilla preservation flap, GTR with membranes, distal wedge procedures and different suturing techniques were performed in different parts of the dentitions of both specimen and the sites were classified as good, suitable or not suitable for the specific surgical procedure.

***Gingivectomy (Goldman 1946):*** The depths of the periodontal pockets were measured. The incision was then made with a straight incision technique (Robicsek 1884) with a slightly coronal angle of the scalpel blade. The detached gingiva was then removed with a universal scaler.

***Modified flap operation (Kirkland 1931):*** Intracrevicular incisions with a scalpel were made on both the buccal/labial and lingual sides of the teeth or segment involved. The incisions were made in a mesio-distal direction. The flap was elevated with a periosteal elevator, and the root surfaces were carefully scaled with hand instruments, and eventual granulation tissue was removed with a universal curette. The flap was then repositioned at its original position and interproximal simple sutures, or continuous sutures were performed to secure the flap.

***Coronally advanced flap (Bernimoulin et al. 1975):*** The coronal part of the gingiva was dissected to illustrate a recessed gingiva. Intracrevicular incisions were made buccally and lingual to the teeth or segments involved. Releasing incisions were made at the mesial and distal edges of the intracrevicular incision. The flaps were raised with a periosteal elevator and a periosteal undermining incision was made to mobilize the flap even more. The root surfaces were carefully scaled and eventual granulation tissue was removed with a universal curette. A connective tissue graft was dissected from other parts of the mucosa with undermining incisions, and the graft was placed on the root surface to be covered by the advanced flap. De-epithelization of the zone to be overlapped at the papilla was performed with superficial incisions with the scalpel. The flap was raised and advanced coronally over the connective tissue graft and sutured with a sling-suture (horizontal mattress suture). The releasing incisions were sutured with interrupted circumferential sutures.

**Apically repositioned flap (Nabers 1954, Friedman 1962):** Intracrevicular incisions were made on both the buccal/labial and lingual sides of the teeth or segment involved. Releasing incisions were made at the mesial and distal edges of the intracrevicular incision. The flaps were raised with a periosteal elevator beyond the mucogingival border and the root surfaces carefully scaled and eventual granulation tissue was removed with a universal curette. The flap was then repositioned apically and sutured at an apical position with a periosteal suture (vertical mattress suture). The releasing incisions were sutured with interrupted circumferential sutures.

**Papilla preservation flap (Takei et al. 1985, Cortellini et al. 1995):** Intracrevicular incisions were made on the facial and lingual sides of the teeth, with semilunar incisions through the interdental area. A scalpel was used to free the interdental papilla from the underlying hard tissue, and the buccal and lingual flaps were raised with a periosteal elevator. The root surfaces were carefully scaled and granulation tissue removed with a universal curette. The vestibular flaps could be further coronally mobilized after dissection of the periosteum at its base (Modified papilla preservation flap). The flaps were repositioned and sutured with interrupted circumferential sutures through the semilunar incisions.

**GTR with membranes (Gottlow et al. 1986):** Intracrevicular incisions were made buccally and lingual to the teeth or segments involved. Releasing incisions were made at the mesial and distal edges of the intracrevicular incision. The flaps were raised with a periosteal elevator and a periosteal undermining incision was made to mobilize the flap even more. The root surfaces were carefully scaled and eventual granulation tissue was removed with a universal curette. A membrane replica was made by cutting a small piece of paper, and the membrane was placed over the root surface to be covered. The membrane was sutured with a sling-suture (horizontal mattress) to the root surface, and the flap was coronally advanced over the membrane. The flap was sutured with a sling-suture, and the releasing incisions were sutured with interrupted circumferential sutures.

**Distal wedge procedure (Robinson 1966):** Buccal and lingual incisions were made distal to a tooth segment to form a triangular wedge. The incised wedge is dissected and eventual undermining incisions were made on the buccal and lingual flaps, and the tooth



---

surfaces were carefully scaled. The buccal and lingual flaps are repositioned over the exposed alveolar bone and sutured with interrupted circumferential sutures.

The sheep model was put to use after the completion of the study, to introduce and teach 8th semester students basic surgical methods. The methods taught and practiced were modified flap operation, distal wedge procedure, apically repositioned flap and coronally advanced flap. The undergraduate students were divided into groups of approximately 8 students, the specific procedure was first demonstrated by one of the authors, before the students proceeded to their own specimen and performed the surgery with guidance of the instructors.

## 4. Results

### 4.1 Periodontal measurements

The probing results showed that the mean value of the probed sites were 2.26 mm in the pigs mandible, with a standard deviation of 0.93 mm (Table 4.1).

**Table 4.1: Total distribution of periodontal probing depth - The pig mandibles**

Surface/ PPD	1 mm	2 mm	3 mm	4 mm	5 mm	6 mm	7 mm	8+ mm	Sum	Average (mm)	Standard deviation
<i>m1 dist</i>		16	13	10	3				42	3.00	0.96
<i>m1 mes</i>	1	14	14	9	3				41	2.98	0.99
<i>dp4 dist</i>	9	31	5	1		1			47	2.04	0.86
<i>dp4 mid</i>	12	29	4	3					48	1.96	0.77
<i>dp4 mes</i>	4	37	5	1	1				48	2.13	0.67
<i>dp3</i>	3	34	3	1		1			42	2.14	0.78
<i>dp2</i>	13	28	1						42	1.71	0.51
<i>dp1</i>	1	11							12	1.92	0.29
<i>dc</i>	3	8	1						12	1.83	0.58
<i>di3</i>	4	11	2	5	1	1			24	2.63	1.35
<i>di2</i>		5	1						6	2.17	0.41
<i>di1</i>									n/a		
<b>Sum</b>	<b>50</b>	<b>224</b>	<b>49</b>	<b>30</b>	<b>8</b>	<b>3</b>	<b>0</b>	<b>0</b>	<b>364</b>	<b>2.26</b>	<b>0.93</b>
<b>Percentage</b>	<b>13.7%</b>	<b>61.5%</b>	<b>13.5%</b>	<b>8.2%</b>	<b>2.2%</b>	<b>0.8%</b>	<b>0.0%</b>	<b>0.0%</b>			

The mean value of the probed sites in the sheep mandibles was 2.59 mm and a standard deviation of 1.34 mm (Table 4.2).

**Table 4.2: Total distribution of periodontal probing depth - The sheep mandibles**

Surface/ PPD	1 mm	2 mm	3 mm	4 mm	5 mm	6 mm	7 mm	8+ mm	Sum	Average (mm)	Standard deviation
<i>m1 - dist</i>	5	31	14	5	4	9	6	10	84	3.99	2.56
<i>m1 - mes</i>	2	28	19	19	6	8	3	3	88	3.48	1.62
<i>dp4 dist</i>	5	49	26	15	7	6			108	2.89	1.24
<i>dp4 mid</i>	8	61	22	17	4	2			114	2.60	1.05
<i>dp4 mes</i>	12	64	20	15	2	2			115	2.45	1.02
<i>dp3</i>	33	81	5	1					120	1.78	0.55
<i>dp2</i>	49	61	4	1	5				120	1.77	0.90
<i>c/dc1</i>	4	74	33	9					120	2.39	0.68
<i>i3/di3</i>	16	54	38	12					120	2.38	0.84
<i>i2/di2</i>	16	47	32	18	6	1			120	2.62	1.10
<i>i1/di1</i>	11	46	32	22	6	2		1	120	2.82	1.25
<b>Sum</b>	<b>161</b>	<b>596</b>	<b>245</b>	<b>134</b>	<b>40</b>	<b>30</b>	<b>9</b>	<b>14</b>	<b>1229</b>	<b>2.59</b>	<b>1.34</b>
<b>Percentage</b>	<b>13.1%</b>	<b>48.5%</b>	<b>19.9%</b>	<b>10.9%</b>	<b>3.3%</b>	<b>2.4%</b>	<b>0.7%</b>	<b>1.1%</b>			

The mean value of the averages of the different sheep specimens was 2.55 mm with a standard variation of 0.58 mm. The mean value of the averages of the different pig specimens was 2.23 mm with a standard deviation of 0.17 mm. One sample of the pigs had to be disregarded due to poor quality and thus no reliable probing depths could be measured. The P-value was calculated with a t-test to 0.153 which means we cannot reject the Null hypothesis and say there is a significant difference between the pig and sheep mean periodontal probing depths (see figure 4.1).

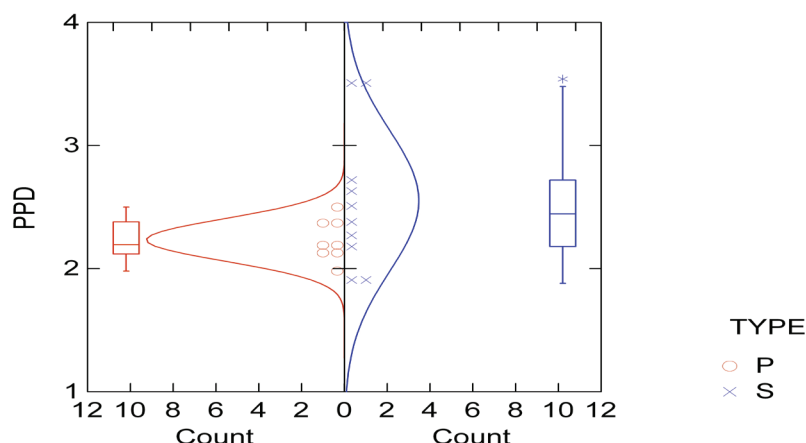


Figure 4.1: Distribution of overall pockets. The graph shows the normal distribution of the individual specimens average probing depths marked by circles and crosses, for respectively the pig and sheep specimens. The box on the side of the graph indicates the the 2nd and 3rd quartile, with the median value indicated by a line in that box. The lines extending from the box includes 90% of the values, and the asterisks show outliers.

When we calculated the probing depths of only the molars we had do disregard one specimen from the sheep selection and one specimen of the pig selection due to poor quality and molars undergoing eruption. The mean value of the sheep specimen was 3.53mm and a standard deviation of 1.29. The mean value of the pigs was 2.35mm and a standard deviation of 0.30. The t-test revealed a P-value of 0.024 which shows that there is a significant difference of the probing depths between the sheep and the pigs in the molar area (see figure 4.2).

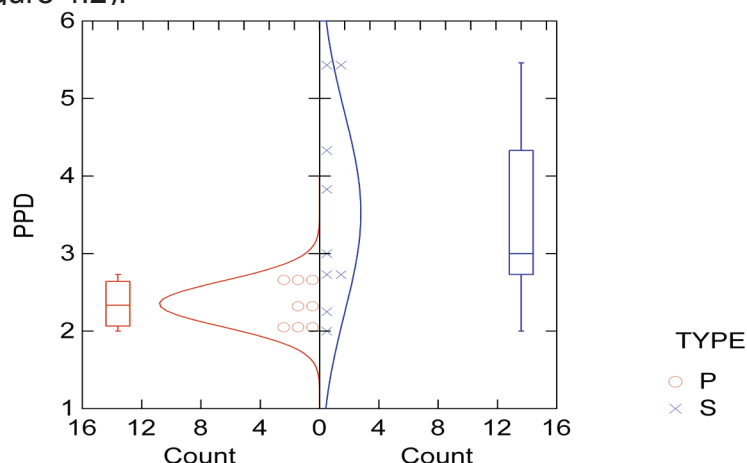


Figure 4.2: Distribution of pockets in the molar area.

We calculated the mean value of the premolar areas and one sample from the pigs selection had to be disregarded due to poor quality of the sample. The mean value of the sheep was 2.26 mm with a standard deviation of 0.50 mm. The mean value of the pigs was 1.95 mm with a standard deviation of 0.17 mm. The t-test revealed a P-value of 0.107 which means we cannot say there is a significant difference in probing depths between the two specimens in the premolar area (see Fig. 4.3).

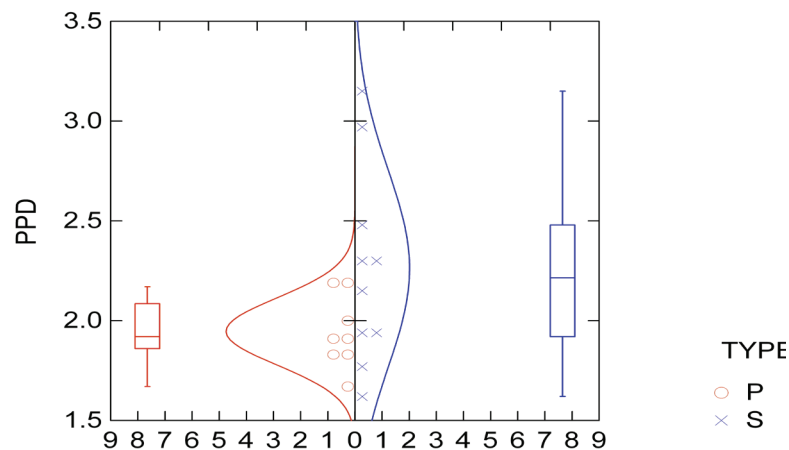


Figure 4.3: Distribution of pockets in the premolar area.

We calculated the mean value of the anterior teeth, and the mean value of the sheep was 2.53 mm with a standard deviation of 0.39 mm. In the pig section we had to disregard 4 of the specimens because of lack of probed depths as a result of poor quality of the specimens. The mean value of the pigs was 2.17 mm with a standard deviation of 0.52 mm. The t-test showed a P-value of 0.149 which means we cannot say here as well that there is a significant difference in probing depths of the anterior teeth of the two specimens (see Fig. 4.4).

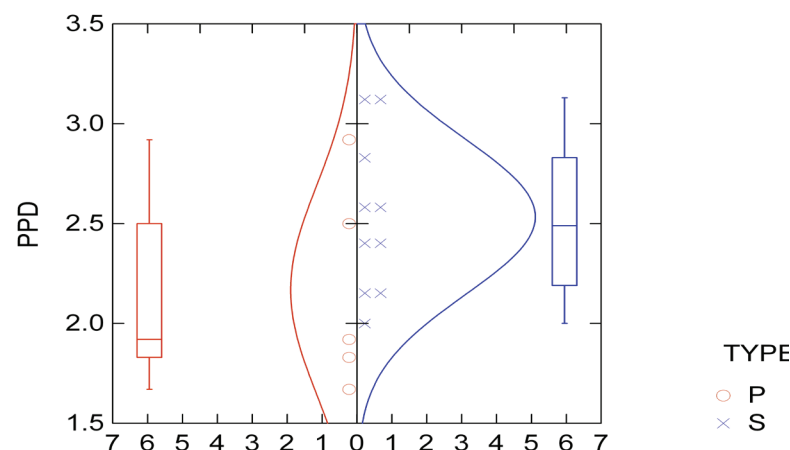


Figure 4.4: Distribution of pockets in the anterior area.

We measured the width of the gingiva on all teeth applicable in both specimens. The mean values of the measurements are given in table 4.3. The gingival width of the pigs anterior teeth were excluded due to inconsistent morphology with diverging and broken teeth, and difficulties establishing a definitive measurement.

Area	Sheep (mm)	Pig (mm)
Anterior segment	3.74	n/a
Posterior segment	2.58	5.75

## **4.2 Surgery**

### **4.2.1 Gingivectomy**

The gingivectomy procedure could be utilized in the dental pad area of the sheep specimen and classified as suitable, but throughout other parts of the dentition there were quite thin gingiva and therefore not so suitable for teaching purposes, and thus classified as not suitable.

In the pig the thickness of the gingiva seemed generally more suitable, but still there were difficulties in performing the correct procedure. However the lingual side of the last molar seemed to have sufficient pocket depths and thickness of the gingiva so the procedure could be performed, and classified as good.

### **4.2.2 Modified flap operation**

This flap procedure was found to be highly applicable for the molar/premolar area of the sheep specimens and was classified as good, but the relatively tight contact areas between the teeth could make suturing challenging. The area of the anterior teeth could also be utilized for this surgery, but we have classified it as suitable and an alternative area, because of difficulties in raising the flap lingually because of the dental pad.

The pig specimen was showing similar suitability for this surgical procedure and was classified as good in the molar/premolar area. Because of the scarce placements of the anterior teeth, the procedure was classified as not suitable for that area.

### **4.2.3 Coronally advanced flap**

This flap was classified as good for the premolar area of the sheep, and as suitable for the anterior area and the molar area. The anterior teeth could be 'pretreated' to mimic recession defects labially by dissecting the coronal part of the gingival, but the area was not classified as good because of its loose teeth and therefore somewhat difficult terminal placement of the flap and the application of sling sutures. The molar area was classified as not suitable because of the relative big size of the teeth and tight contacts between the teeth, which make suturing with sling sutures in special challenging. The premolar area with the most anterior premolar in special was classified as good, because of looser contact points and suitable size of the teeth. A good area for harvesting the connective tissue graft was between the most anterior premolar and the canine or generally in the

dental pad region.

In pig specimens, the molar area was classified as not suitable because of the size of the teeth and the relative close contacts between the teeth and therefore somewhat challenging suturing. The premolar area was classified as good due to suitable sizes of the teeth and contact points between the teeth loose enough to make the suturing procedure relatively easy. The anterior area often consisted of few or damaged teeth with unfavorable rotations, so the area was classified as not suitable. An area for harvesting the connective tissue graft was between the premolars and the canine.

#### ***4.2.4 Apically repositioned flap***

In the sheep specimen the molar area was applicable but due to big teeth the final positioning of the flap was somewhat difficult and the area was classified as suitable. The premolar area was classified as good due to smaller teeth, and the whole procedure could be performed without major difficulties. The anterior area was classified as not suitable because of the dental pad and fibrous connective tissues in combination with long roots after the elevation of the flap made, in combination with somewhat loose teeth, the flap management and suturing difficult.

The pig molar area was classified as suitable because of large teeth and somewhat difficult to place the final flap stably in its apical position. The premolar area was very applicable and classified as good. The anterior area was classified as not suitable because of the relative small teeth, and often even missing teeth.

#### ***4.2.5 Papilla preservation flap***

The molar/premolar area of the sheep is not suitable for this procedure because of very tight contact points between the teeth and the semilunar incision therefore very difficult. The anterior area could be used but it is not ideal because of the hard connective tissue and hence the area was classified as suitable.

The pig molar and premolar area was not suitable because of the tightness between the teeth and therefore difficulties in performing the interdental semilunar incisions and elevation. The anterior area was not suitable because of the poor conditions of the teeth, and their small size, and big spaces between them.

#### **4.2.6 GTR with membranes**

The molar area of the sheep was difficult because of lack of furcations and difficult root anatomy, and therefore classified as not suitable. The anterior premolar was good for this procedure because of its two rooted anatomy and a furcation could be made with a universal scaler. The anteriors was classified as not suitable because of their looseness and therefore lack of stability when suturing the flap and membrane. The membrane could be cut out of the paper surrounding the suturing material.

The pig molar area was considered difficult and therefore not suitable because of difficult root anatomy. The premolar area was classified as good because we could make a furcation defect with a universal scaler and then place a membrane over the defect. Suturing could be performed with sling- sutures or interrupted sutures with relative ease. The anterior area was considered not suitable because of small and often missing teeth.

#### **4.2.7 Distal wedge procedure**

In the sheep the area distal to the last molar was found to be suitable, but not good because of the relative thin tissue overlying the marginal bone, and the sometimes presence of erupting teeth. The area distally of the canine was classified as not suitable because of the thin soft tissue and therefore difficulties in creating a proper wedge.

The area distally of the last molar in the pig was classified as good because of its deep soft tissue and easiness of making a true distal wedge and thereafter tight suturing. The area distally of the canines was classified as not suitable because of the small teeth and therefore difficulties in making a sufficient wedge to dissect.

The practical course for the undergraduate students was performed and organized by the authors. The students attending seemed to appreciate the course when asked, and many students commented that this type of training under relaxed conditions and supervision of more experienced instructors was a good introduction to the practical procedures of periodontal surgery.



**Table 4.4: Suitability table**

Suitability table	Sheep Specimen	Pig specimen
Gingivectomy	Suitable	Good
Modified flap operation	Good	Good
Coronally advanced flap	Good	Good
Apically repositioned flap	Good	Good
Papilla preservation flap	Suitable	Not suitable
GTR with membranes	Good	Good
Distal wedge procedures	Suitable	Good

**Table 4.5: Suitability table - Pig**

Pig area table	Best area	Alternative area	Not suitable area
Gingivectomy	Molar area		Anterior/premolar area
Modified flap operation	Premolar area	Molar area	Anterior area
Coronally advanced flap	Premolar area		Anterior/molar area
Apically repositioned flap	Premolar area	Molar area	Anterior area
Papilla preservation flap			Ant/premol/mol area
GTR with membranes	Premolar area		Anterior/molar area
Distal wedge procedures	Distally to last molar		Anterior/canine area

**Table 4.6: Suitability table - Sheep**

Sheep area table	Best area	Alternative area	Not suitable area
Gingivectomy	Dental pad		Rest of dentition
Modified flap operation	Premolar/molar area	Anterior area	
Coronally advanced flap	Premolar area	Anterior area	Anterior area
Apically repositioned flap	Premolar area	Molar area	Anterior area
Papilla preservation flap	Anterior area		Premolar/molar area
GTR with membranes	Premolar area		Molar/anterior area
Distal wedge procedures	Distally to last molar		Distally to canine

## 5. Discussion

In the original outline of this study, our aim was also to compare frozen sheep mandibles with fresh ones, but this comparison was later disregarded due to logistic reasons, which would mean that fresh sheep mandibles would have to be collected from freshly slaughtered sheep on a steady basis. We would only receive the specimens after slaughtering, but there were difficulties in getting precise dates for delivery of small numbers of fresh samples. Since we were only testing up to 3 mandibles each day, and the fear of deteriorating specimens made us disregard this comparison. This could be compared in later studies with better established supply logistics.

Another topic we discussed was comparing halal (i.e. allowed under Islamic law)-slaughtered sheep mandibles with sheep mandibles obtained through conventional slaughtering. Halal-slaughtered sheep do not contain blood (Al Qareer et al. 2004) which would be a considerable advantage when exercising the surgical procedures. This comparison was disregarded as well, the “halal-technique” utilized in Norway is not the same as the one utilized in the Islamic world, which seems to be an international issue (Nakyinsige et al. 2012). The difference in the slaughtering procedure may be only the presence of an imam who would bless the slaughtering process. Moreover, the long distance to the nearest slaughterhouse which provided so-called halal-slaughtering, which was in the middle part of Norway, would have increased the cost of attaining the samples significantly. Therefore we disregarded this issue as well.

As regards to the tooth nomenclature, there was some discussion regarding the naming of the deciduous teeth in the sheep. The deciduous teeth, which are replaced by permanent premolars, are by some named deciduous molars, as in humans, but the zoological and archeological literature classified them as deciduous premolars. When we asked members of the Norwegian veterinary institute, they were unsure as well. We also contacted Norwegian school of veterinary science and they agreed with our decision to classify them as deciduous premolars, based on the detailed archeological and zoological literature.

The quality of the specimens was another big issue. Only after having provided the butcher with sufficient information on how we exactly wanted the mandibles to be dissected the mean quality improved, but still there were some areas of torn gingiva especially in the distal/molar areas. The impact of freezing seems to deteriorate the sheep

mandibles as well. Also, it seems that mandibles which had spent the longest time in the freezer were dryer when they were defrosted. In retrospect, we see that they may have better been frozen in individual plastic bags to prevent them from drying up.

The mean quality of the pig heads was good, but preferably we would have obtained them as dissected mandibles already from the butcher. However, based on higher costs and the risk for torn gingiva we decided that the safest option was to obtain the half heads and dissect them ourselves to achieve a good quality of the samples.

Since we found it hard to find consistent evidence on the anatomy and the tooth nomenclature in other articles and different consultations with staff at both the Norwegian school of veterinary science and the Norwegian veterinary institute, we introduced the idea of including an anatomical chapter in this paper. To illustrate the teeth and underlying bone as well as tooth buds, we suggested performing a maceration process to remove all soft tissues (Sandström 1969). However, our consultant at the anatomical department advised us not to macerate the samples due to the long time needed and the somewhat disgusting procedure itself. He advised us to rather boil the jaws free from most of the soft tissues as described in the materials and methods part of this paper.

The probing procedure with a probe consisting of 2-mm-markings has a potential of inaccuracy, and in retrospect a periodontal probe with 1 mm markings could have been utilized to achieve a more reliable result. Some of the sites to be probed had to be disregarded due to torn gingiva, especially in the sheep molar areas. Other sites that sometimes were disregarded were the anterior teeth, especially in the pig mandibles, due to very small teeth, loose teeth, or poor sagittal dissection of the skull resulting in some of the anterior teeth being cut or the gingiva surrounding them damaged. This made the sample smaller and thus has to be taken in mind when interpreting the statistical results. Other issues related to periodontal probing were the presence of erupting molars in some of the samples, especially in the sheep, leading to relatively large readings at the last molar, which also has to be taken in mind when looking at the statistical results.

### **5.1 Surgical procedures**

The gingivectomy procedure was somewhat difficult to perform, due to either thin gingiva or the hard tissues, especially the hard dental pad of the sheep. The tissue conditions did not imitate those conditions in human mucosa indicating the gingivectomy procedure (Prato et al. 1995), which would be a more hyperplastic gingiva.

The modified flap operation could be described as the best procedure to practice on the animal specimen for the undergraduate student, due to its relative simplicity, different areas where it was applicable (see results) and different suturing techniques which could be utilized. The root anatomy however, especially in molars, is quite different from the human anatomy, and infrabony lesions were not observed which would have been preferable to illustrate situations where surgery has a good treatment outcome (Graziani et al. 2012).

The coronally advanced flap with its connective tissue graft is somewhat controversial, as compared to the procedure without the graft, or different root surface modifications (McGuire et al. 2012, Cairo et al. 2012, Oliveira & Muncinelli 2012, Roman et al. 2013). However we chose to perform the surgery with a connective tissue graft to illustrate its possibility in the animal models, and for teaching purposes the training for harvesting and handling of this tissue graft may be educational.

The indication of an apically repositioned flap is mainly made in multirrooted teeth with some degree of furcation involvement (Walter et al. 2011) and thus these areas of the dentition in the animal specimens were tested primarily.

The papilla preservation flap is mostly used in the anterior area because of aesthetic reasons (Takei et al. 1989) and thus we focused our testing of this procedure there. The molar/premolar area had often very tight contacts between the teeth, which made the semilunar incision of the papilla very difficult.

The GTR procedure was in this study tested to cover furcation areas, and premolars of both specimens showed the best furcation involvements, or if there were lack of furcation lesions they could easily be simulated with a universal curette. For simplicity reasons membranes were just cut out of the paper surrounding the suturing needle, as they were regarded as sufficient for teaching purposes.

The distal wedge procedure was included in this study although new procedures had been described as alternatives (Singh et al. 2012). We would like to see more evidence on efficacy of these procedures before including them in our study, which describes a

study model for teaching routine methods of periodontal surgery. A different advantage of learning this procedure is that the dissected distal wedge could sometimes be used as a graft (Park 2009), although more evidence is needed in this part as well before recommendations could be made to teach undergraduate students this procedure.

### ***5.2 Future aspects***

There are plenty of issues to be investigated in future studies. Thus, it may be possible to compare frozen versus fresh mandibles, and comparison with truly halal-slaughtered sheep. The logistic procedures could and should be improved, so that the sheep and pig mandibles preferably will arrive in optimal condition. It may also be possible to study different age-groups of the specimens, to see if there are significant differences.

This study did not include the procedure of deepening the vestibulum by augmentation, and this could be included in future studies as well, although there is poor evidence of this procedures efficiency in regards of keeping the gingiva healthy (Miyasato et al. 1977, Grevers 1977).

Frenulectomy procedures could probably be included in the studies as the sheep specimens have both a lingual and labial frenula, but since the pig mandibles are cut in half, frenulectomy procedures may be difficult unless different samples are obtained. Whether respective treatment of involved furcations, such as root amputation, hemisection or tunnel procedures can be simulated in the sheep model, in particular, has to be assessed as well.

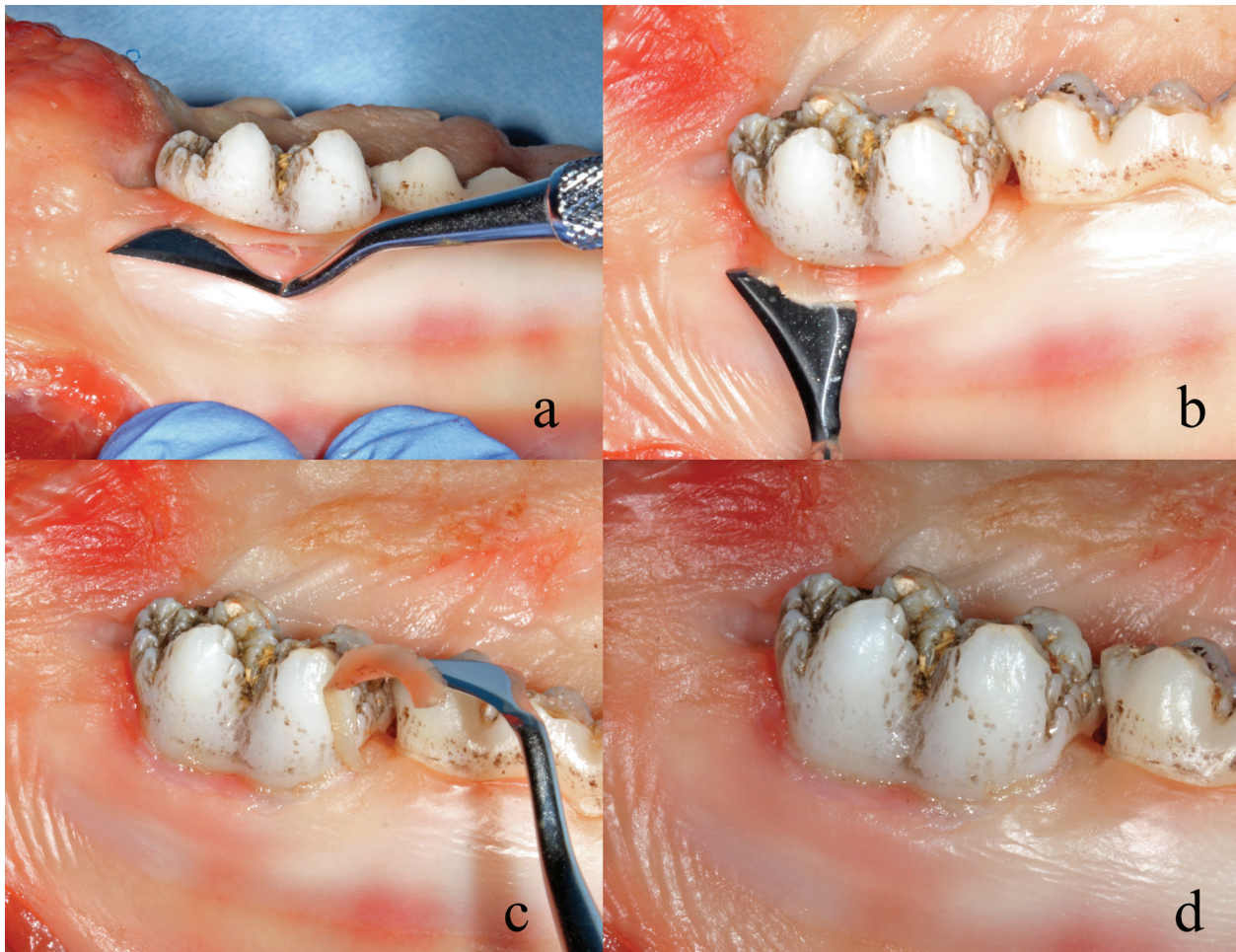Other surgical procedures not necessarily directly related to periodontal surgery may be introduced to the model, including simulation of sinus perforations after maxillary extractions, even sinus elevation procedures (López-Niño et al. 2012) and training for surgical wound closure.

## **6. Conclusion**

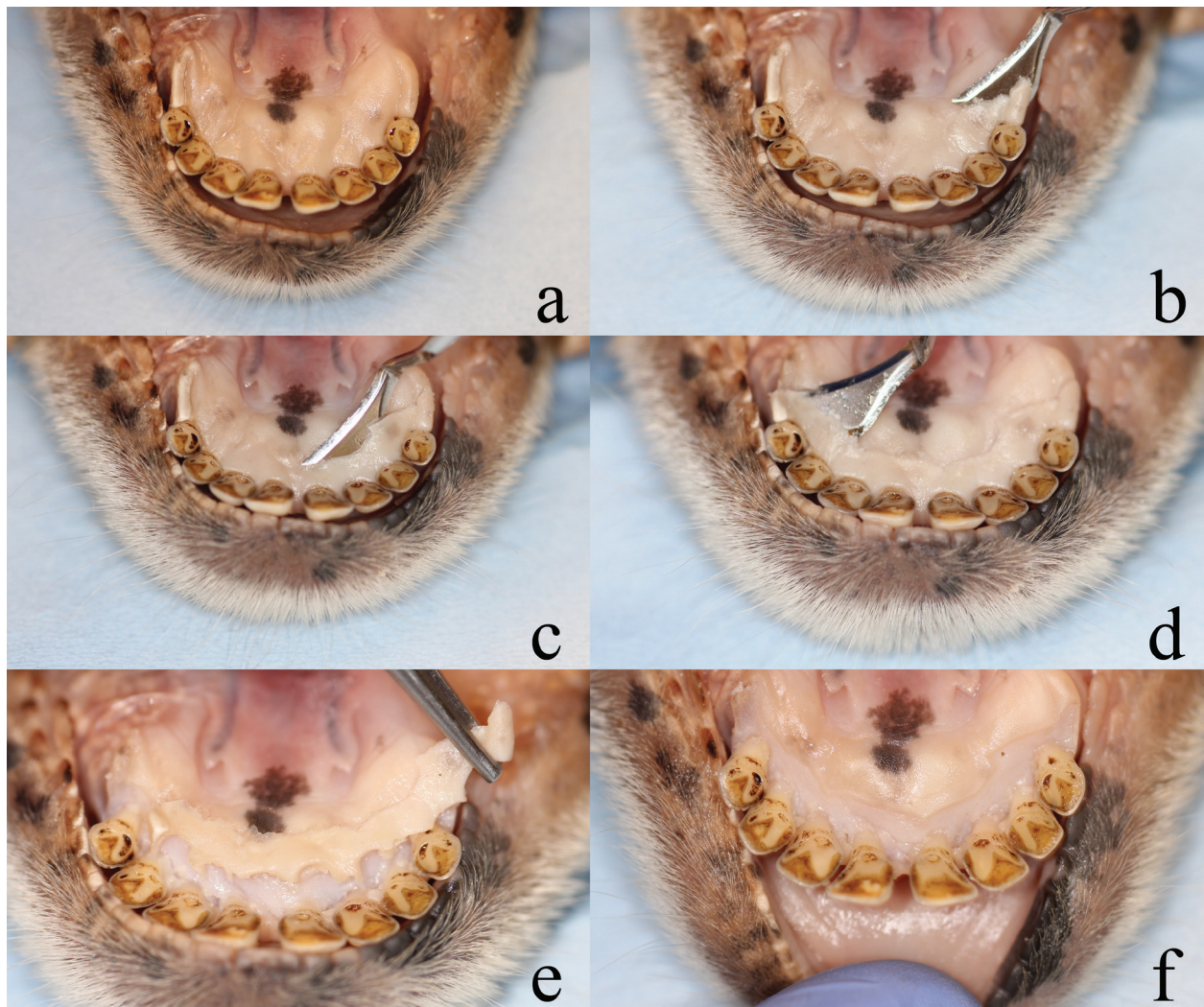
The study showed that the sheep model is a valid alternative for teaching undergraduate students a very large variety of periodontal surgical procedures, as compared to the pig model. Our study showed no difference in periodontal pathology between the two specimens.

The picture sequences below, illustrating the surgical procedures, could be used in a practical manual for teaching-courses in periodontal surgery.

## 7. Pictures

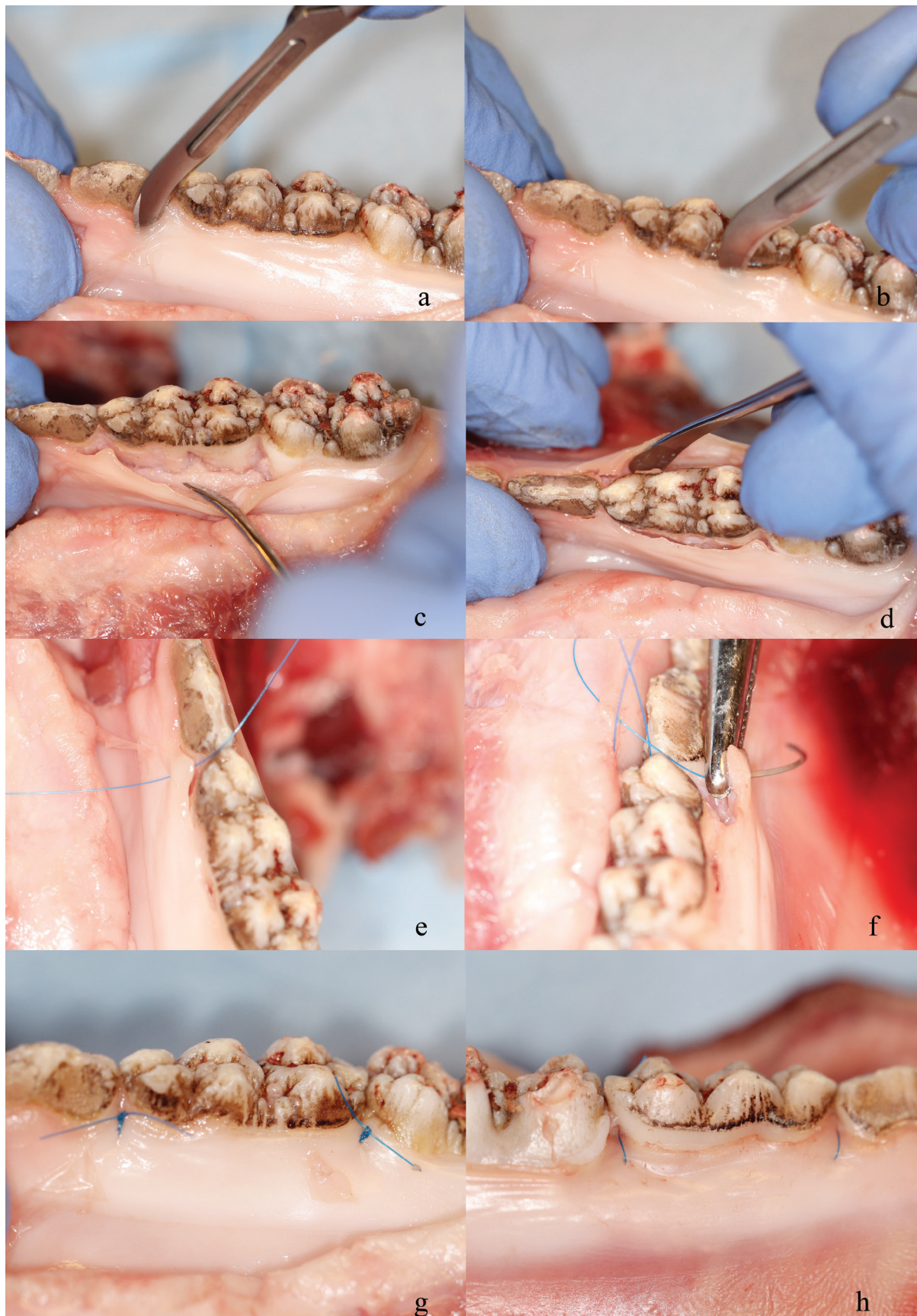

**Figure 7.1.** Gingivectomy - pig: a-b) Gingivectomy with a slightly coronal angle of the Kirkland surgical knife. c) The dissected gingiva. d) Postoperative view.

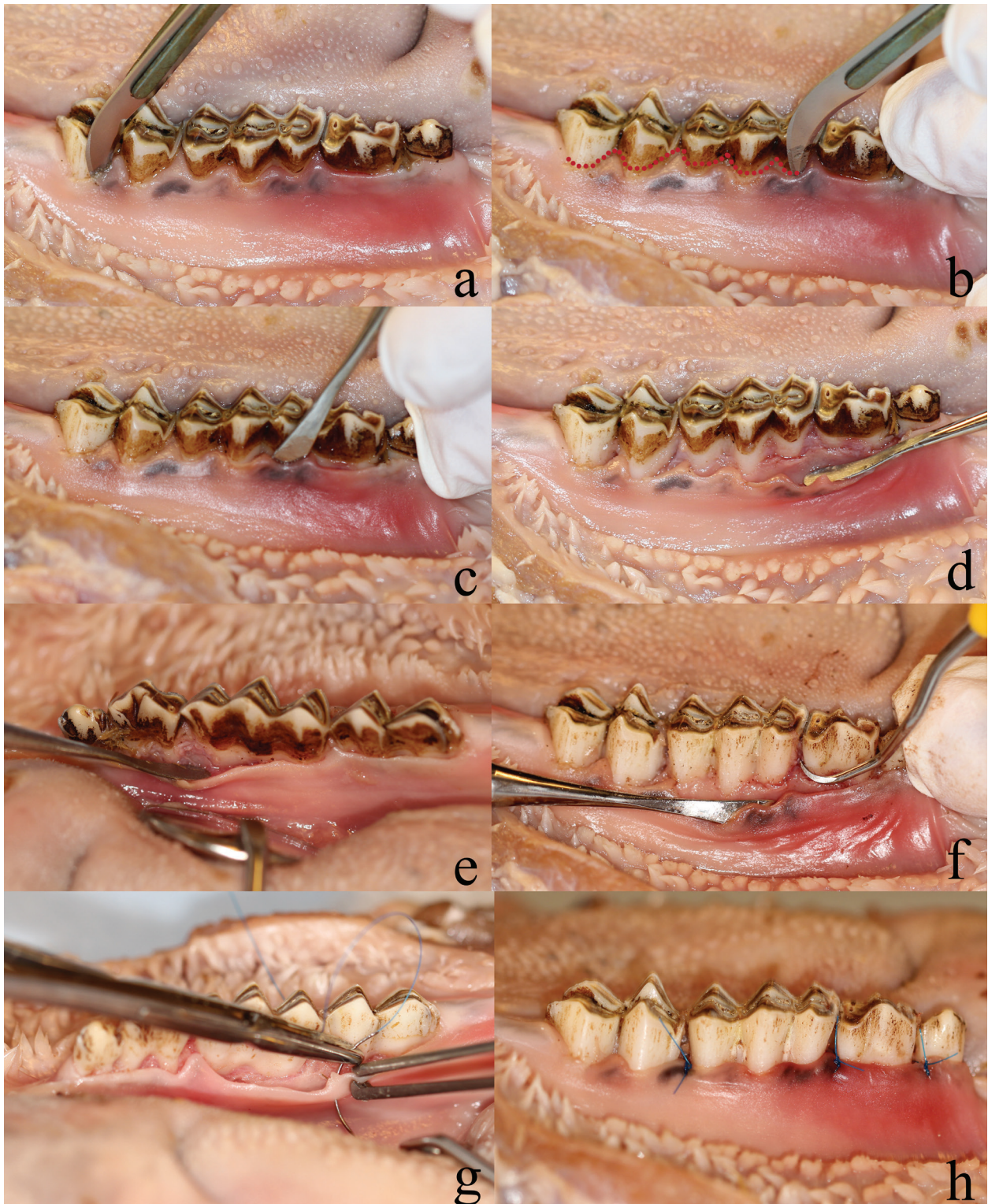


**Figure 7.2.** Gingivectomy procedure anterior area - sheep: a) Preoperative view. b) Incision angle to the tooth axis of about  $120^\circ$ , with a hatched-shaped Kirkland knife. c-d) Continuous incision across the entire surgical site. e) Tissue removal. f) Postoperative view.

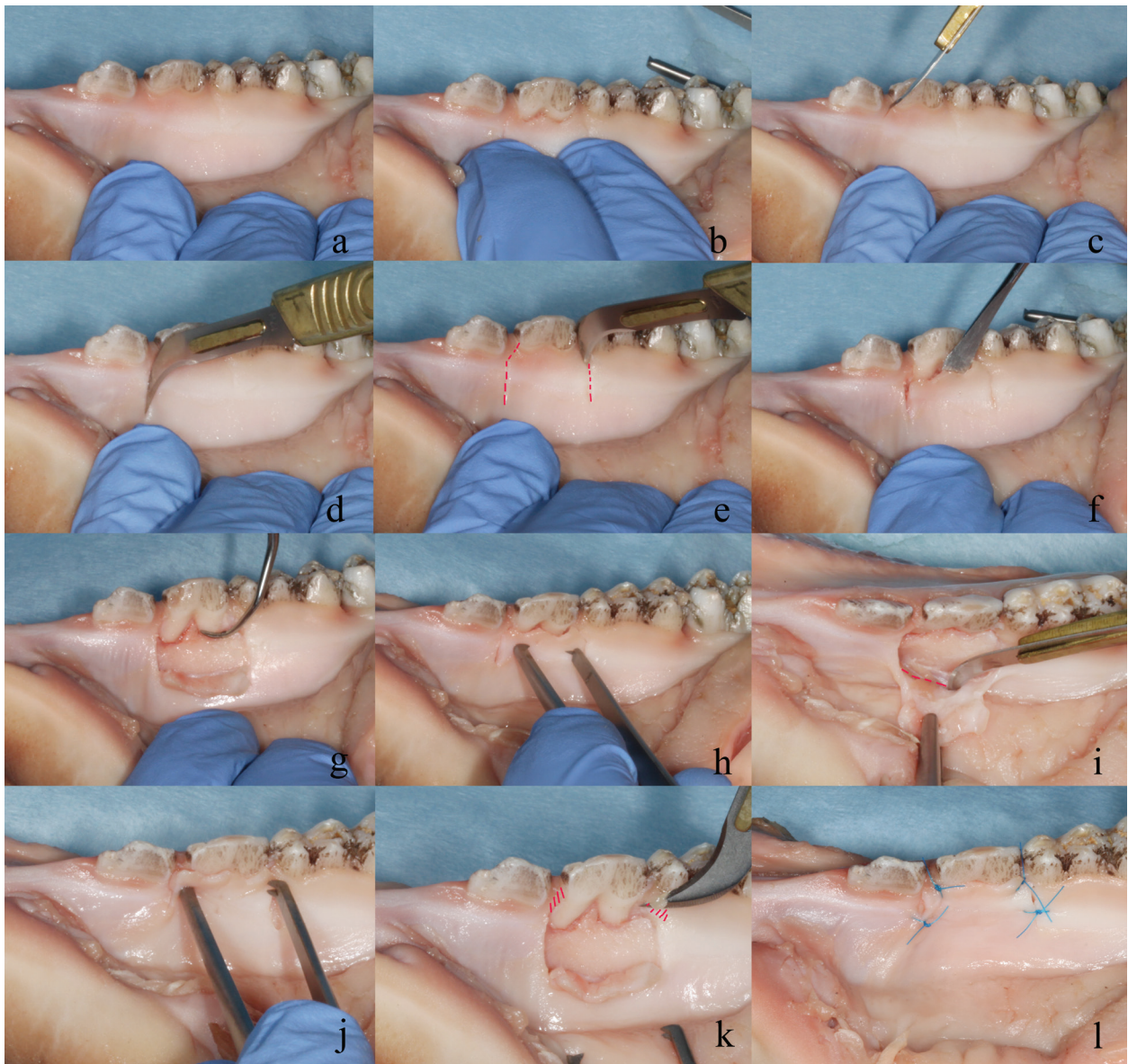




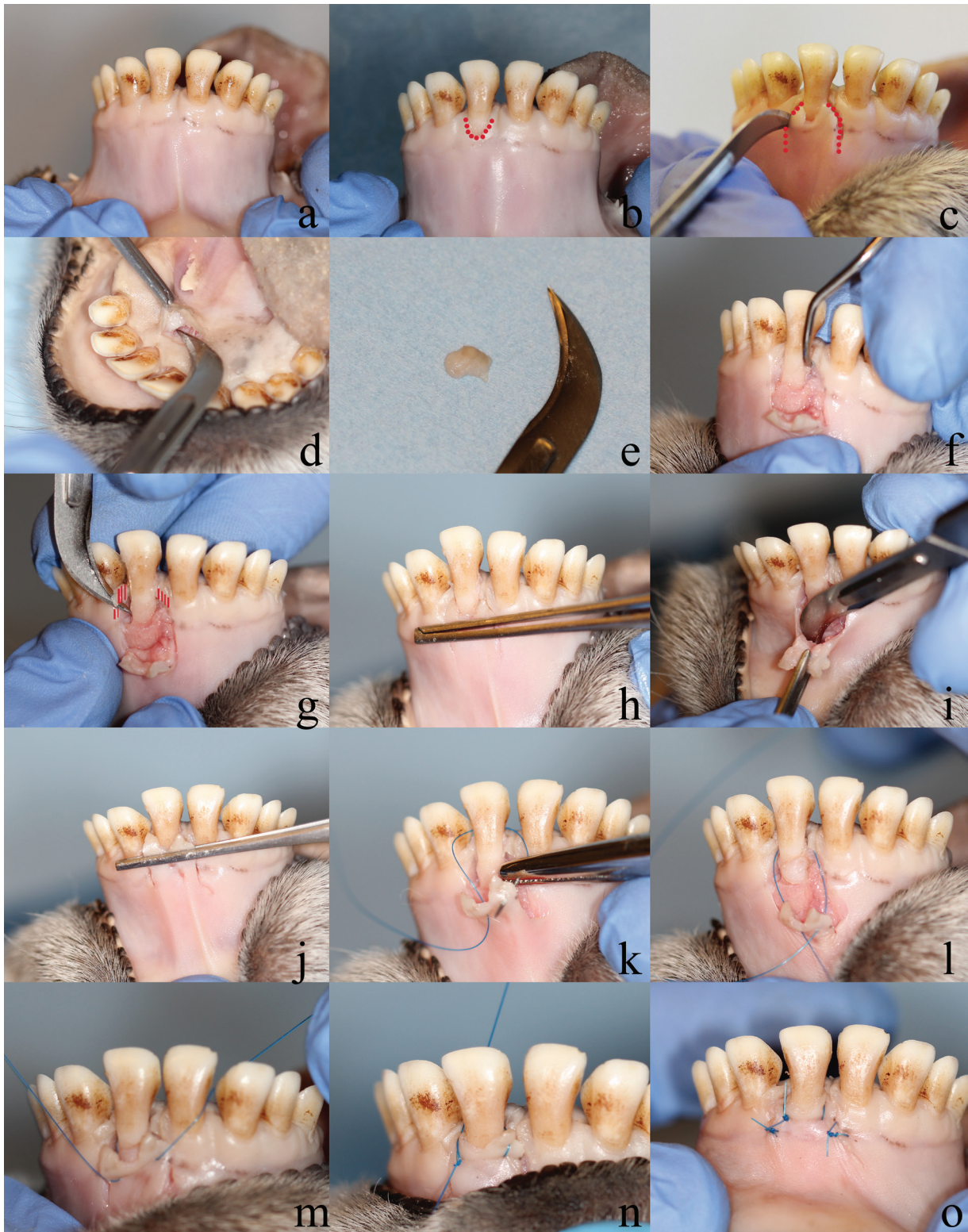
**Figure 7.3. Modified flap operation - pig:** a-b) Intracrevicular incisions. c-d) Raising the flap with a periosteal elevator on both buccal and lingual sides. e-f) Interproximal simple sutures through the buccal and lingual papilla. g-h) Postoperative view on the buccal and lingual sides.



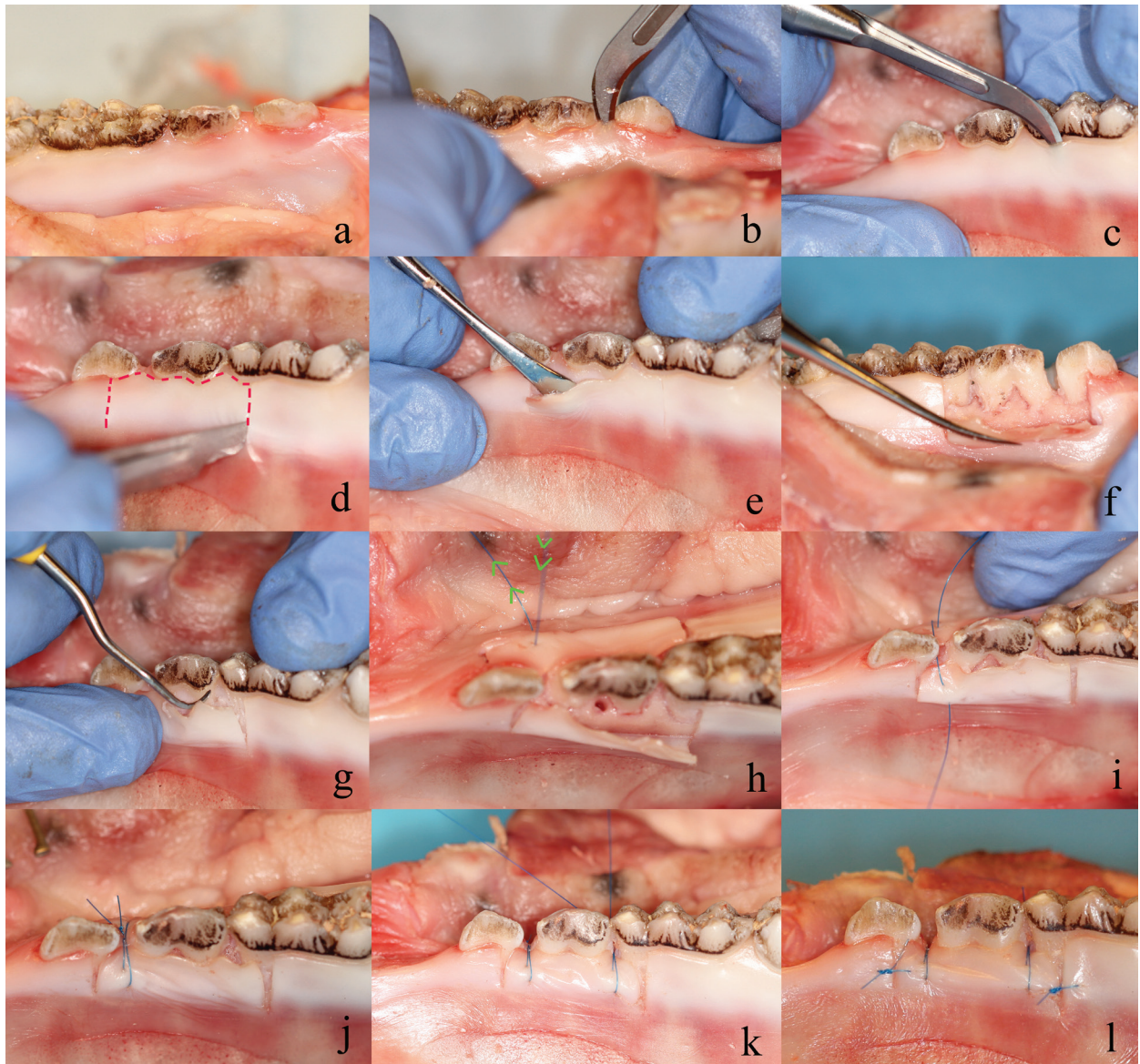
**Figure 7.4. Modified flap operation - sheep:** a-b) Intracrevicular incision. c-d) Elevating the flap with a periosteal elevator. e) Elevating the flap on the lingual side. f) Scaling of the exposed root surfaces. g) Simple interrupted sutures used to suture the flap. (lingual side) h) Postoperative view.



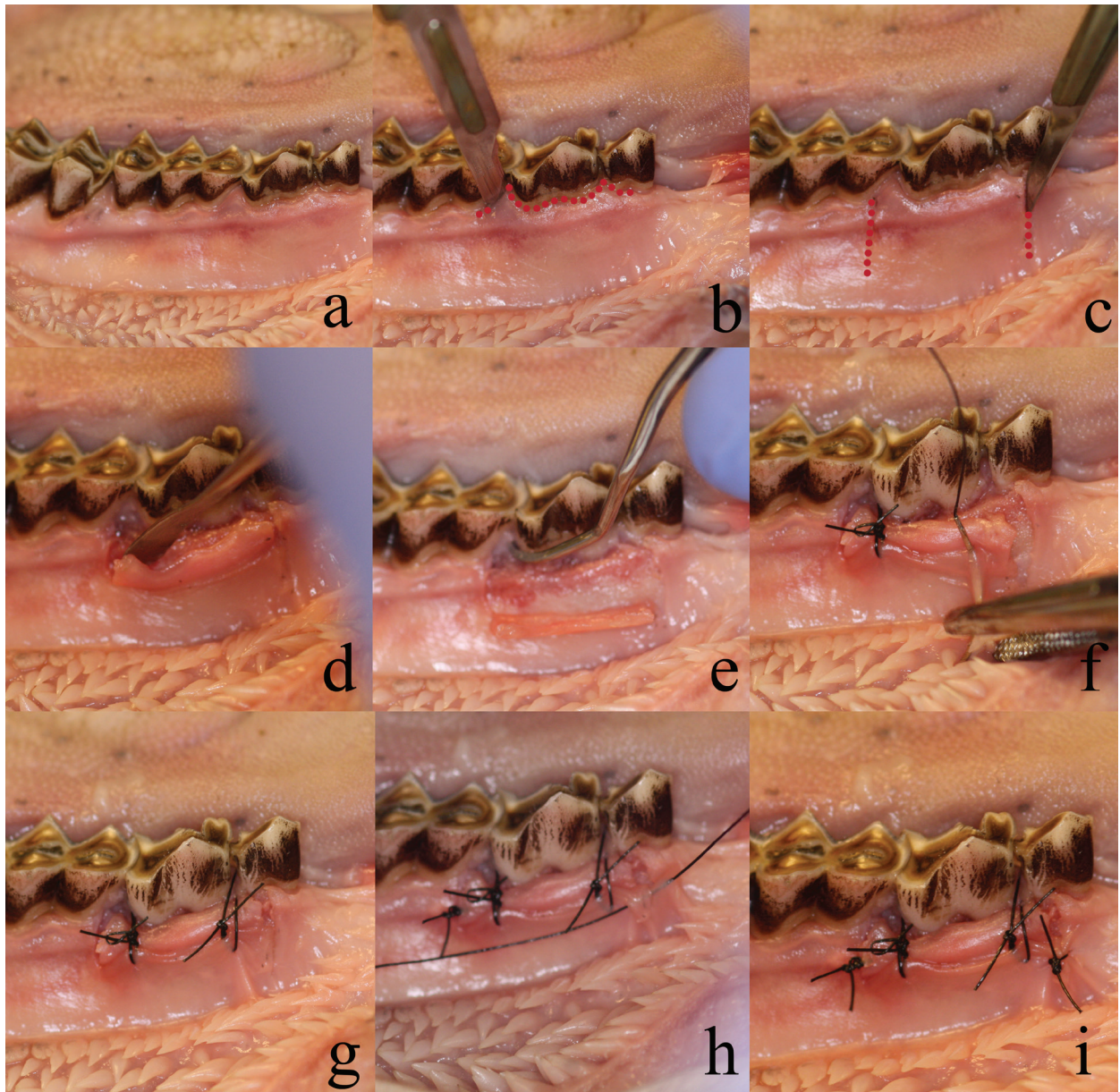
**Figure 7.5. Coronally advanced flap - pig:** a) Preoperative view. b) A recession defect was created by dissecting the most coronal part of the gingiva. c) Intracrevicular incision. d) Releasing incision. e) Stapled lines showing the extent of the releasing incisions. f) Raising the flap with a periosteal elevator. g) Scaling of the root surfaces. h) The flap at its original position. i) Periosteal undermining incision. j) Flap at its coronally advanced position. k) Oblique incisions illustrated by stapled area. l) Postoperative view, with sutures in place.



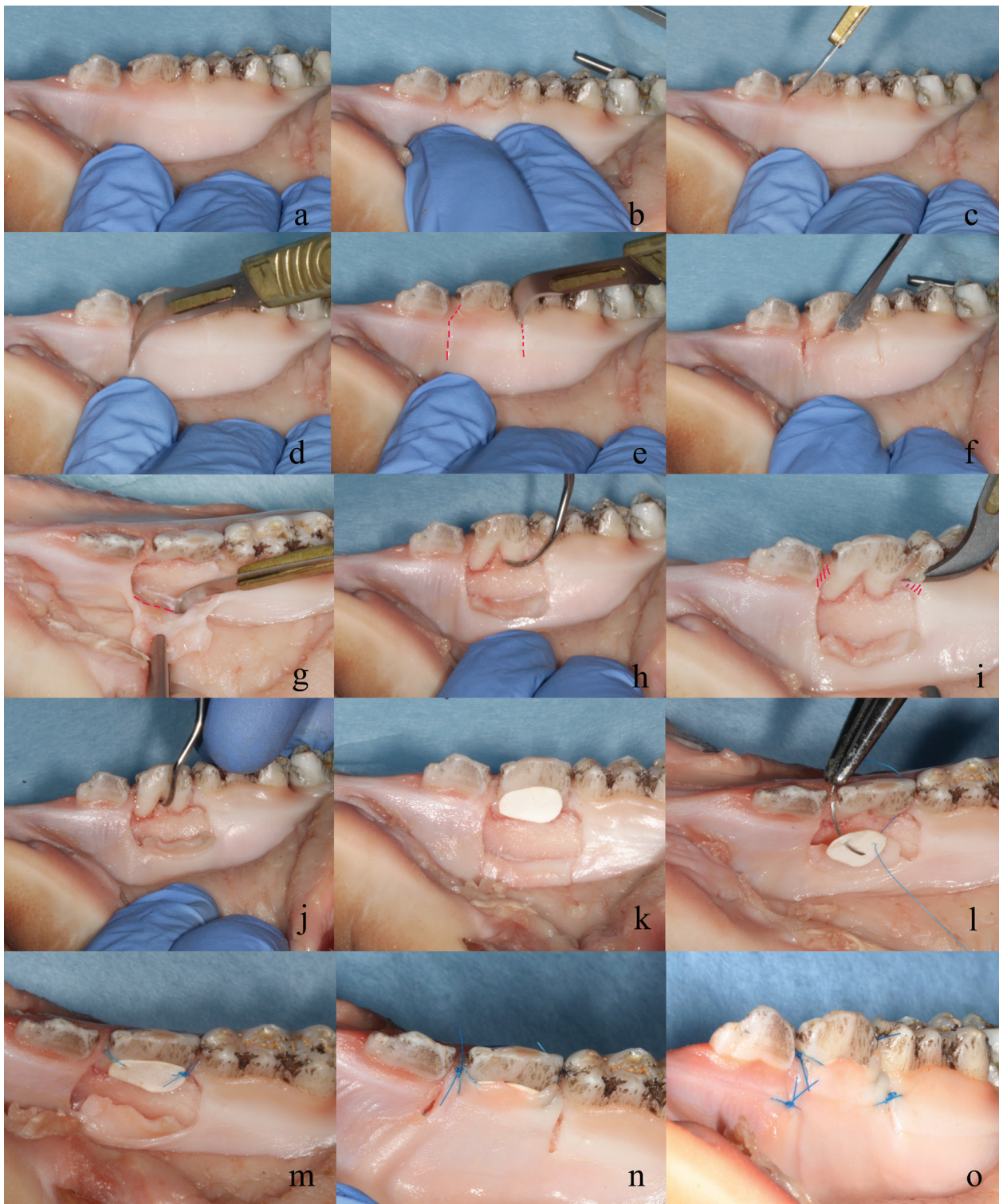
**Figure 7.6. Coronally advanced flap with connective tissue graft - sheep:** a) Preoperative view. b) Stapled line marking the intracrevicular incision. Note the recession defect created by dissecting the coronal part of the gingiva. c) Stapled lines marking the extent of the releasing incisions. d-e) Harvesting the connective tissue graft from the dental pad area. f) Scaling of the root surface. g) Oblique incisions marked by stapled area. h) Flap at its original position. i) Periosteal undermining incision. j) Flap at its coronally advanced position. k-n) Sling-suturing with the connective tissue graft covering the exposed root surface. o) Postoperative view including interrupted sutures of the releasing incisions.



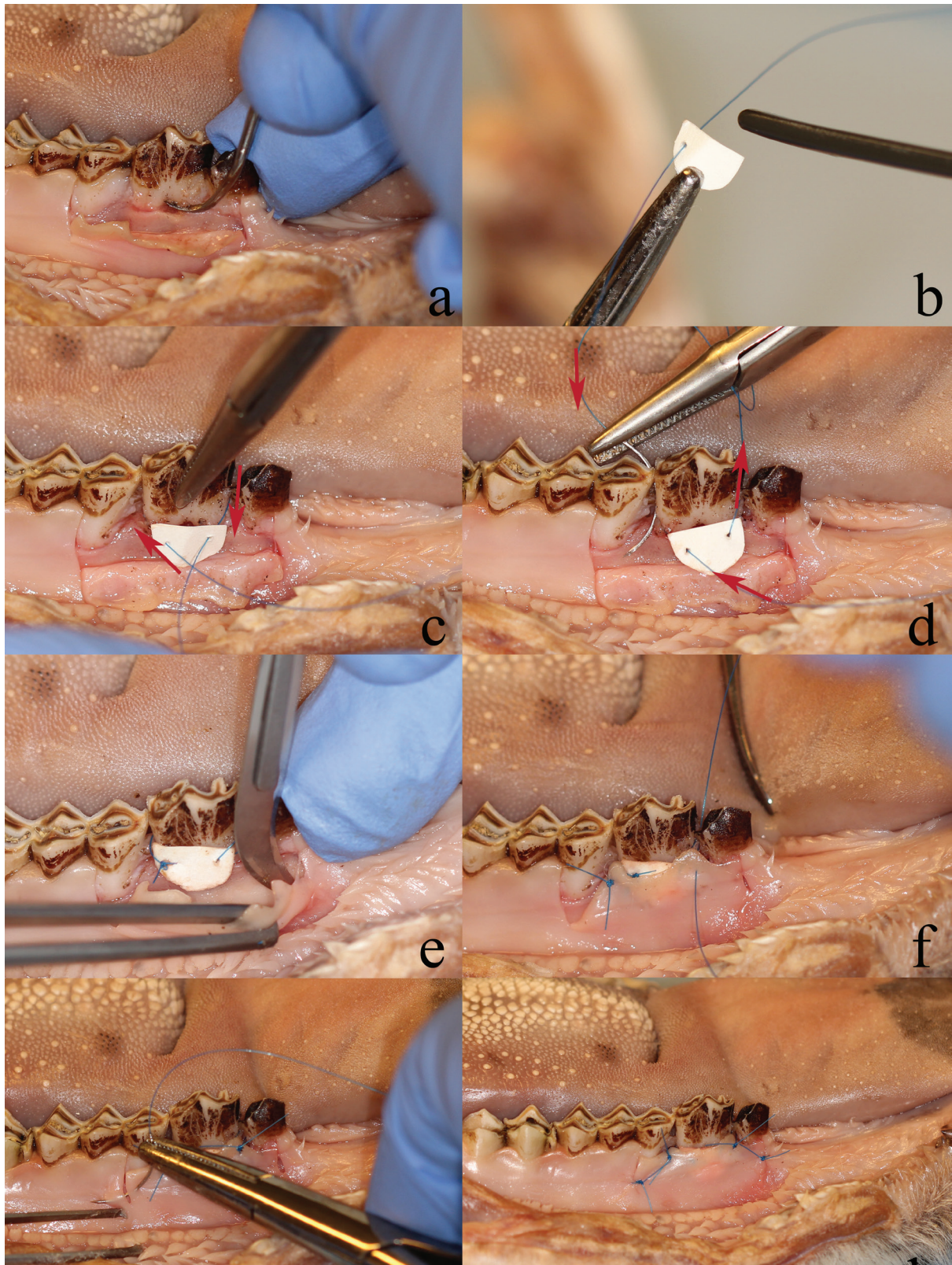
**Figure 7.7. Apically repositioned flap pig:** a) Preoperative view. b-c) Intracrevicular incisions on the buccal and lingual sides. d) Releasing incisions. The stapled lines shows the intracrevicular incision and the two releasing incisions on the lingual side. e-f) Raising the flap with a periosteal elevator. g) Scaling of the root surface. h) Periosteal suture. Arrows indicate the direction of the suture thread. i-k) Periosteal suture continued. l) Postoperative view with simple interrupted sutures for the releasing incisions.



**Figure 7.8. Apically repositioned flap - sheep:** a) Preoperative view. b) Intracrevicular incision. c) Releasing incision. The stapled lines showing the extent of the desired releasing incisions. d) Elevating the flap with a periosteal elevator. e) Scaling the exposed root surfaces. f) One periosteal suture (vertical mattress) in place. g) Periosteal sutures at both margins of the flap, fixing the flap at an apical position. h) Simple interrupted sutures were used for the releasing incisions. i) Postoperative view.

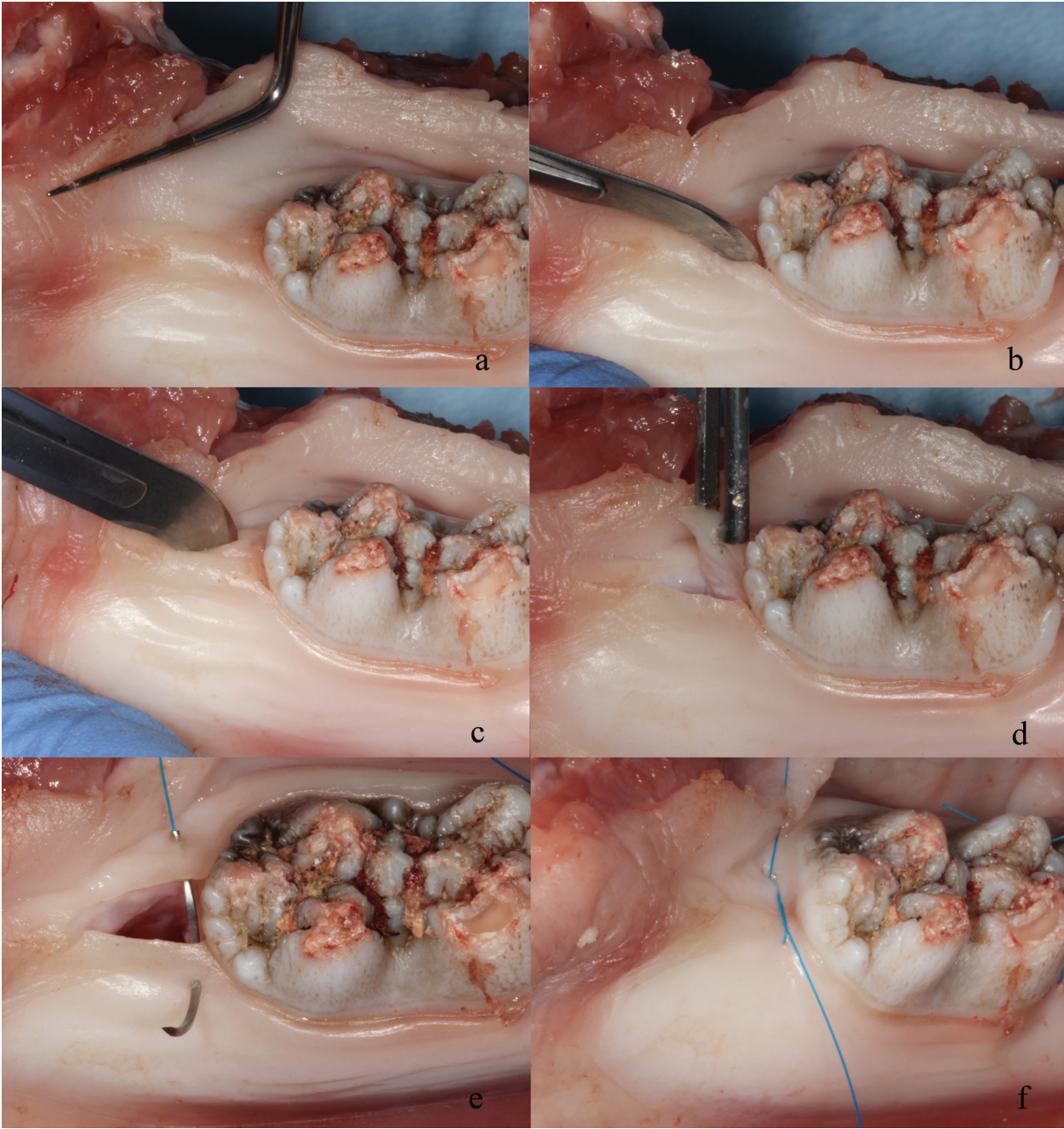


**Figure 7.9. GTR with membrane - pig:** a) Preoperative view. b) The coronal part of the gingiva was dissected to mimic a recession defect. c) Intracrevicular incision. d) Releasing incision. e) Stapled lines indicating the extent of the releasing incisions. f) Raising the flap with a periosteal elevator. g) Periosteal undermining incision. h) Scaling of the root surface. i) Oblique incisions illustrated by stapled area. j) Scaling of furcation area. k) Membrane replica created of paper. l-m) Sling suture to attach the membrane. n-o) Suturing with interrupted sutures covering the membrane and furcation area.

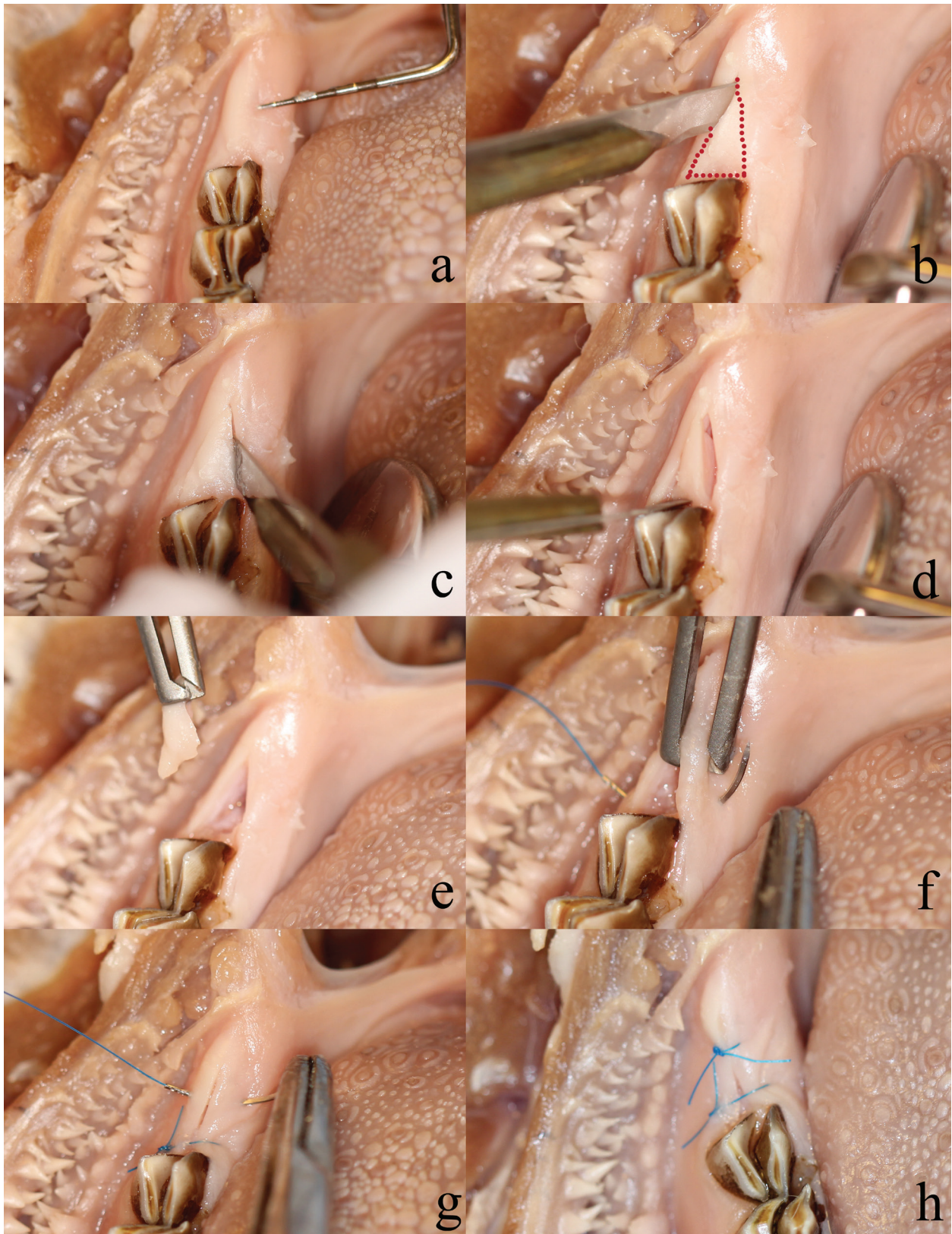


**Figure 7.10. GTR with membrane - sheep:** a) After elevation of the buccal flap, including releasing incisions. Scaling is performed in the furcation area to create a furcation. b) A membrane made of paper is cut out in a proper shape to cover the defect. The suture tread is penetrated once through the membrane. c-d) A sling-suture is made to fixate the membrane over the defect. Arrows showing the direction of the needle. e) Periosteal incision to mobilize the flap. f) Sling-suture to fixate the flap in a coronally advanced position. g) Simple interrupted sutures for the releasing incisions. h) Postoperative view.

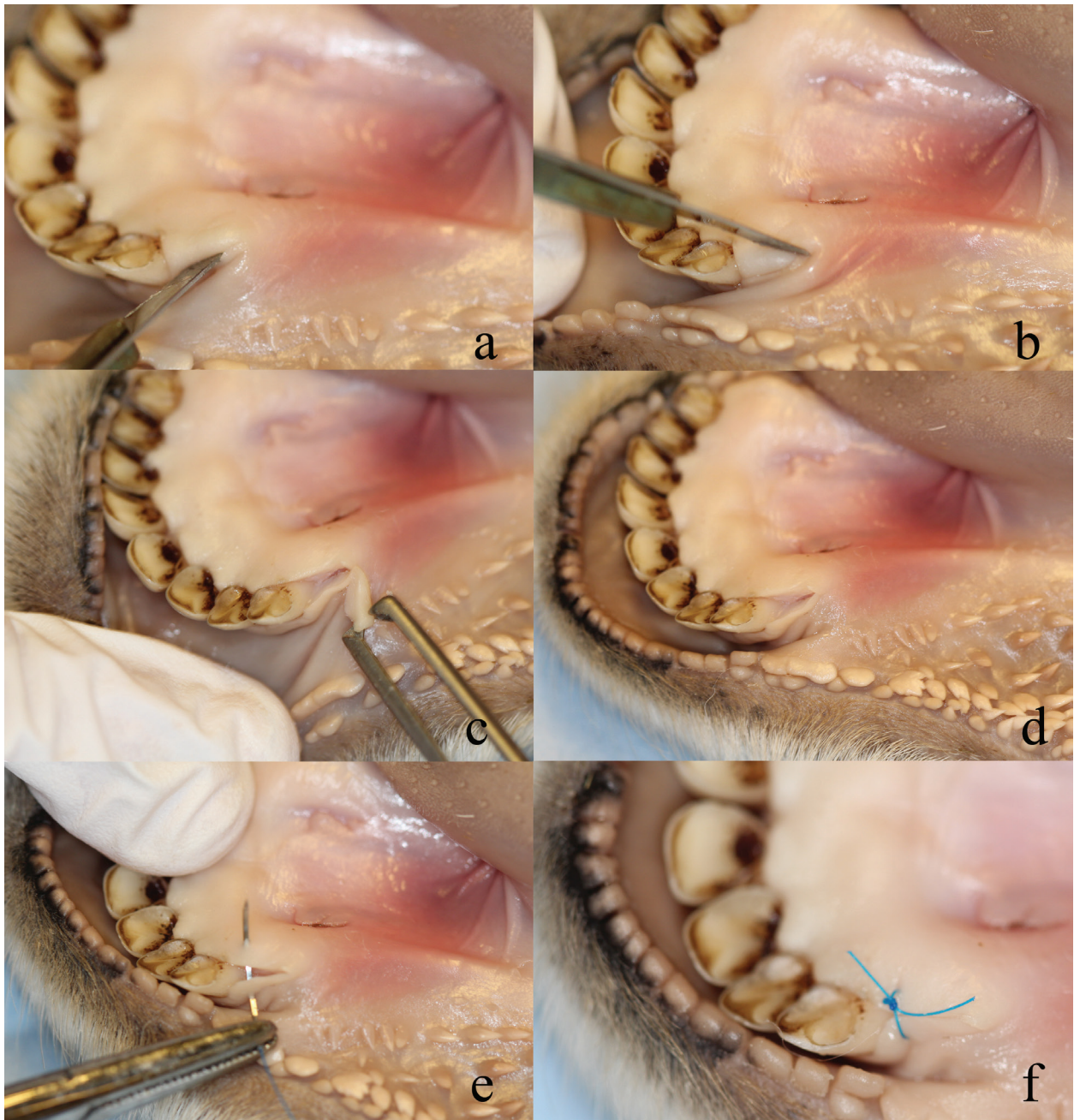




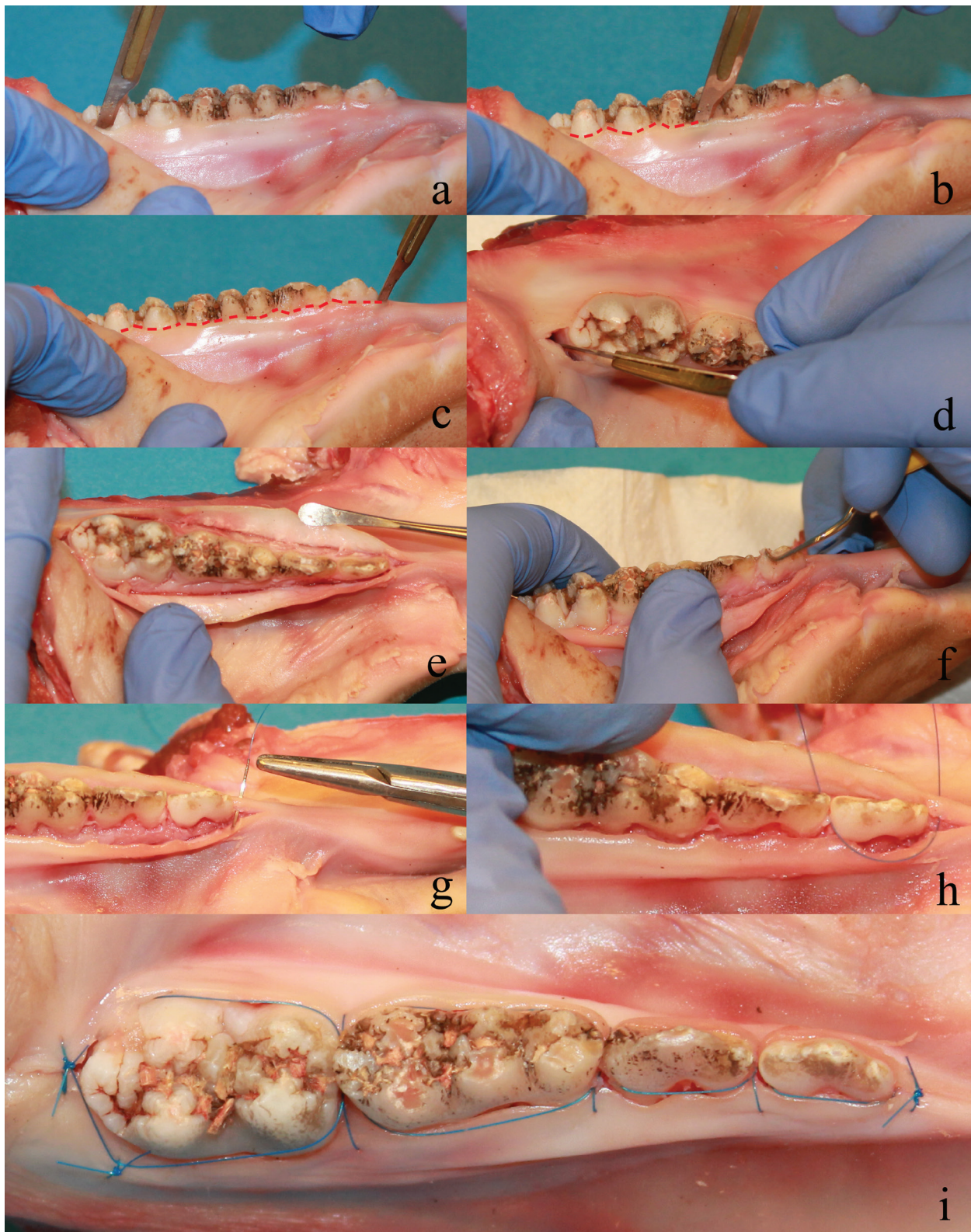
**Figure 7.11. Distal wedge procedure pig:** a) Preoperative view. b-c) Buccal and lingual incisions forming a triangle. d) Removal of the triangular wedge. e-f) Suturing with interrupted suture.



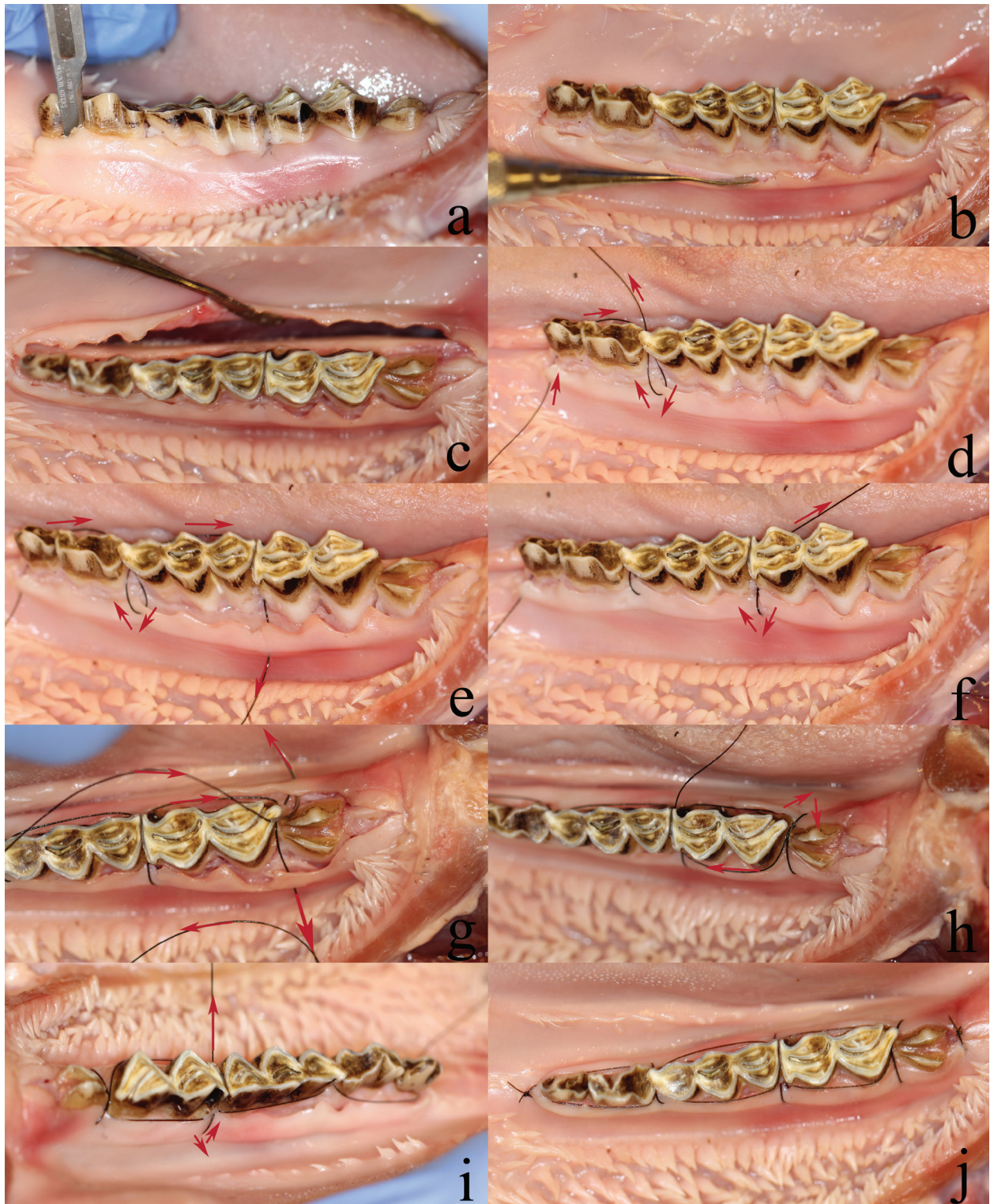
**Figure 7.12. Distal wedge procedure molar area sheep:** a) Preoperative view b) Buccal incision. The stapled line showing the preferred outline of the final wedge. c-d) Lingual and intracrevicular incisions. e) Dissection of the triangular wedge. f-g) Suturing with simple interrupted sutures. h) Postoperative view with two simple interrupted sutures.



**Figure 7.13.** Distal wedge procedure canine area sheep: a-b) Buccal and lingual incisions distally to the canine. c) Dissecting of the triangular wedge. d) View of the area without the dissected distal wedge. e) Suturing with a simple interrupted suture. f) Postoperative view.



**Figure 7.14. Continuous suture pig:** a-d) Intracrevicular incision through the whole posterior tooth segment. e) Elevation of the buccal and lingual flaps with a periosteal elevator. f) Scaling of the root surface. g-h) Continuous suture technique. i) Postoperative view.



**Figure 7.15. Continuous suture sheep:** a) Intracrevicular incision. b-c) Elevating the buccal and lingual flaps with a periosteal elevator. d-g) A continuous suture was performed. The buccal flap is fixed in this sequence. The arrows indicating the path of the suturing needle. h-i) Continuous suture. The lingual flap is fixed in this sequence. The arrows indicating the path of the suturing needle. j) Postoperative view.

## 8. References

- Agfacts A3.0.1: How to tell the age of sheep, first. Division of animal production, NSW agriculture [Online], reprinted 1989. Reviewed October 2003. Available from: <http://www.docstoc.com/docs/53054006/How-to-tell-the-age-of-sheep> [Accessed 16th January 2013].
- Al-Qareer AH, Afsah MR, Müller HP. A sheep cadaver model for demonstration and training periodontal surgical methods. *Eur J Dent Educ* 2004; 8: 78-83.
- Anthony DJ, Lewis EF. *Diseases of the pig*, 5th ed. London: Bailliere, Tindall & Cox; 1961.
- Badersten A, Nilveus R, Egelberg J. Effect of nonsurgical periodontal therapy. II. Severely advanced periodontitis. *J Clin Periodontol* 1984; 11: 63-76.
- Barrett RH. The feral hog at Dye Creek Ranch, California. *Hilgardia* 1978; 46: 283-355.
- Becker W, Becker BE, Caffesse R, Kerry G, Ochsenbein C, Morrison E, Prichard J. A longitudinal study comparing scaling, osseous surger, and modified Widman procedures: results after 5 years. *J Periodontol* 2001; 72: 1675-1684.
- Benzie D, Cresswell E. Studies of the dentition of sheep. II. Radiographic illustrations of stages in the development and shedding of the permanent dentition of Scottish Blackface sheep. *Res Vet Sci* 1962; 3: 231-235.
- Bernimoulin JP, Lüscher B, Mühlemann HR. Coronally repositioned periodontal flap. Clinical evaluation after one year. *J Clin Periodontol* 1975; 2: 1-13
- Bull G, Payne S. *Tooth eruption and epiphyseal fusion in pigs and wild boar*. Oxford: British Archaeology Reports; 1982.
- Caffesse RG, Sweeney PL, Smith BA. Scaling and root planning with and without periodontal flap surgery. *J Clin Periodontol* 1986; 13: 205-210.
- Cairo F, Cortellini P, Tonetti M, Nieri M, Mervelt J, Cincinelli S, Pini-Prato G. Coronally advanced flap with and without connective tissue graft for the treatment of single maxillary gingival recession with loss of inter-dental attachment. A randomized controlled clinical trial. *J Clin Periodontol* 2012; 39: 760-768.
- Cortellini P, Prato GP, Tonetti MS. The modified papilla preservation technique. A new surgical approach for interproximal regenerative procedures. *J Periodontol* 1995; 66: 261-266.
- Department of Agriculture. *Swine summary selected countries*. [Online] United States, Foreign Agricultural Service. Available from: <http://www.fas.usda.gov/psdonline/psdReport.aspx?hidReportRetrievalName=Swine+Summary+Selected+Countries&hidReportRetrievalID=1649&hidReportRetrievalTemplateID=7> [Accessed 1st February 2013].
- Duckworth J. Studies of the dentition of sheep. Clinical observations from investigations into the shedding of permanent incisor teeth by hill sheep. *Res Vet Sci* 1962; 3: 1-17.
- Feldhamer GA, McCann BE. Dental anomalies in wild and domestic *Sus Scrofa* in Illinois. *Acta Theriolog* 2004; 49: 139-143.

- Friedman N. Mucogingival surgery. The apically repositioned flap. *J Periodontol* 1962; 26: 328-340.
- Food and agriculture organization of the United Nations (FAOSTAT) [Online]. Available from: <http://faostat.fao.org/site/573/DesktopDefault.aspx?PageID=573#ancor> [Accessed 16th January 2013].
- Gentry A, Clutton-Brock J, Grooves CP. The naming of the wild animal species and their domestic derivatives. *J Archaeol Sci* 2004; 31: 645–651.
- Goldman HM. Gingivectomy; indications, contraindications, and method. *Am J Orthod Oral Surg.* 1946; 32(oral surg): 323-326.
- Gottlow J, Nyman S, Lindhe J, Karring T, Wennström J. New attachment formation in the human periodontium by guided tissue regeneration. Case reports. *J Clin Periodontol* 1986; 13: 604-616.
- Graziani F, Gennai S, Cei S, Cairo F, Baggiani A, Miccoli M, Gabriele M, Tonetti M. Clinical performance of access flap surgery in the treatment of the intrabony defect. A systematic review and meta-analysis of randomized clinical trials. *J Clin Periodontol.* 2012; 39: 145-156.
- Grevers A. Width of attached gingiva and vestibular depth in relation to gingival health. Universiteit van Amsterdam; 1977.
- Harvey CE. Veterinary dentistry. Philadelphia: W.B. Saunders Company; 1985.
- Hatt SD. The development of the deciduous incisor in the sheep. *Res. Vet. Sci* 1967; 8: 143-150.
- Healy WB, Ludwig TG. Wear of sheep's teeth. I. The role of ingested soil. *New Zealand J Agricul Res;* 1965; 8.4: 737-752.
- Hillson S. Teeth, 2nd ed. New York: Cambridge University Press; 2005.
- Hitchin AD, Walker-Love J. Broken-mouth in hill sheep. *Agriculture* 1959; 66:5.
- Rafferty KL, Herring SW, Marshall CD. Biomechanics of the rostrum and the role of facial sutures. *J Morphol* 2003; 257: 33-44.
- Kirkland O. The suppurative periodontal pus pocket; its treatment by the modified flap operation. *J Am Dent Assoc* 1931; 18: 1462-1470.
- König J, Rühling A, Schlemme H, Kocher T, Schwahn C, Plagmann HC. Learning root debridement with curettes and power-driven instruments in vitro: the role of operator motivation and self-assessment. *Eur J Dent Educ* 2002; 6: 169-175.
- Lindhe J, Westfelt E, Nyman S, Socransky SS, Haffajee AD. Long-term effect of surgical/non-surgical treatment of periodontal disease. *J Clin Periodontol* 1984; 11: 448-458.
- López-Niño J, García-Caballero L, González-Mosquera A, Seoane-Romero J, Varela-Centelles P, Seoane J. Lamb ex vivo modelin maxillary sinus floor elevation surgery: a comparative study with human standards. *J Periodontol* 2012; 83: 354-361.
- Matschke GH. Ageing European wild hogs by dentition. *J Wildlife Management* 1967; 31: 103-113.

- Matia JI, Bissada NF, Maybury JE, Ricchetti P. Efficiency of scaling of the molar furcation area with and without surgical access. *Int J Periodontics Rest Dent* 1986; 6: 24-35.
- McGuire MK, Scheyer ET, Nunn M. Evaluation of human recession defects treated with coronally advanced flaps and either enamel matrix derivative or connective tissue: comparison of clinical parameters at 10 years. *J Periodontol* 2012; 83: 1353-1362.
- McGrath C, Bedi R. Understanding the value of oral health to people in Britain-importance to life quality. *Community Dent Health* 2002; 19: 211-214.
- Miles A, Grigson C. Colyer's variations and diseases of the teeth of animals. Cambridge University Press; 1990. PP 107, 394.
- Miyasato M, Crigger M, Egelberg J. Gingival condition in areas of minimal and appreciable with of keratinized gingiva. *J Clin Periodontol* 1977; 4: 200-209.
- Moulton JE. Tumours in domestic animals. University of California Press; 1978. P 212.
- Myers P, Espinosa R, Parr CS, Jones T, Hammond GS, Dewey TA. 2013. The Animal Diversity Web [Online]. Available from: <http://animaldiversity.org> [Accessed 1st February 2013].
- Nabers CL. Repositioning the attached gingival. *J Periodontol* 1954; 25: 38-39.
- Nakyinsige K, Man YB, Sazili AQ. Halal authenticity issues in meat and meat products. *Meat Sci* 2012; 91: 207-214.
- Northey RD, Hawlay JG, Suckling GW. The tooth to pad relationship in sheep – some mechanical considerations. *New Zealand J Agricult Res* 1975; 18: 133-138.
- Oliveira GH, Muncinelli EA. Efficacy of root surface biomodification in root coverage: a systematic review. *J Can Dent Assoc* 2012; 78: 122.
- Oliver, WLR. Pigs, peccaries and hippos: status survey and conservation action plan. IUCN, Pigs And Peccaries Specialist Group, 1993; 19:1-2.
- Otto B, Schumacher GH. Dental abnormalities in the Vietnamese belly pig. *Z Versuchstierkd* 1978; 20: 122-131.
- Page RC, Schroeder HE. Periodontitis in man and a: a comparative review. Basel: S Karger AG; 1982.
- Park JB. Clinical showcase. Treatment of gingival recession with subepithelial connective tissue harvested from the maxillary tuberosity by distal wedge procedure. *J Can Dent Assoc* 2009; 75: 643-646.
- Prato GP, Clauser C, Cortellini P. Periodontal and mucogingival surgery. *Periodontol*. 2000 1995; 9: 90-105.
- Reavill C. *Ovis aries* [Online], Animal Diversity Web. Available from: [http://animaldiversity.ummz.umich.edu/accounts/Ovis\\_aries/](http://animaldiversity.ummz.umich.edu/accounts/Ovis_aries/) [Accessed 29th January 2013].
- Reig OA. A proposed unified nomenclature for the enamelled components of the molar teeth of the Cricetidae (Rodentia). *J Zool* 1977; 181: 227-241.



- Ridler AL, West DM. Diseases of sheep. 4th ed. Oxford: Blackwell Publishing 2007. P 149-155.
- Robicsek S. Ueber das Wesen und Entstehen der Alveolar-Pyorrhöe und deren Behandlung. The 3rd Annual Report of the Austrian Dental Association, 1884. (Reviewed in J Periodontol 1965; 36: 265.)
- Robinson RE. The distal wedge operation. Periodontics 1966; 4: 256-264.
- Roman A, Soanca A, Kasaj A, Stratul SI. Subepithelial connective tissue graft with or without enamel matrix derivative for the treatment of Miller class I and II gingival recessions: a controlled randomized clinical trial. J Periodontal Res 2013, in press.
- Rühling A, Schlemme H, König J, Kocher T, Schwahn C, Plagmann HC. Learning root debridement with curettes and power-driven instruments. Part 1. A training program to increase effectivity. J Clin Periodontol 2002; 29: 622-629.
- Samuel JL, Woodall PF. Periodontal disease in feral pigs (*sus scrofa*) from Queensland, Australia. J Wildlife Dis 1988; 24: 201-206.
- Sandström B. Enzymatic maceration of delicate bone and small skeletons. Acta Anat (Basel) 1969; 74: 487-488.
- Schaller, O. Illustrated veterinary anatomical nomenclature. Stuttgart: Enke, 1992.
- Schlegel M. Krebs in der Nasenhöhle des Schweines. Z Tiermed 1915; 18: 452-464.
- Singh M, Stark PC, Damoulis PD, Levi P, Griffin TJ. Trap door: an alternative procedure to the triangular distal wedge for the elimination of distal periodontal pockets adjacent to edentulous areas. Compend Cont Educ Dent 2012; 33: 38-44.
- Stacey GC. The pig's head as a teaching device in oral surgery. Aust Dent J 1967; 12: 160-164.
- Steele KW, Henderson HV . Occurrence of periodontal disease in sheep in Mangonui, Whangaroa, Hokianga and Bay of Islands counties. New Zealand J Agricult Res 1977; 3: 301-308.
- Takei HH, Han TJ, Carranza FA jr, Kenney EB, Lekovic V. Flap technique for periodontal bone implants. Papilla preservation technique. J Periodontol 1985; 56: 204-210.
- Takei H, Yamada H, Hau T. Maxillary anterior esthetics. Preservation of the interdental papilla. Dent Clin North Am 1989; 33: 263-73.
- Terrili CE. Food and Agriculture Organization of the United Nations [Online]. Rome, Italy: FAO; 1986. Available from: <http://www.fao.org/docrep/009/ah221e/ah221e00.htm> [Accessed 19th February 2013].
- Walter C, Weiger R, Zitzmann NU. Periodontal surgery in furcation-involved maxillary molars revisited—an introduction of guidelines for comprehensive treatment. Clin Oral Investig 2011; 15: 9-20.
- Weinreb MM, Sharav Y. Tooth development in sheep. Am J Vet Res 1964; 25: 891-908.